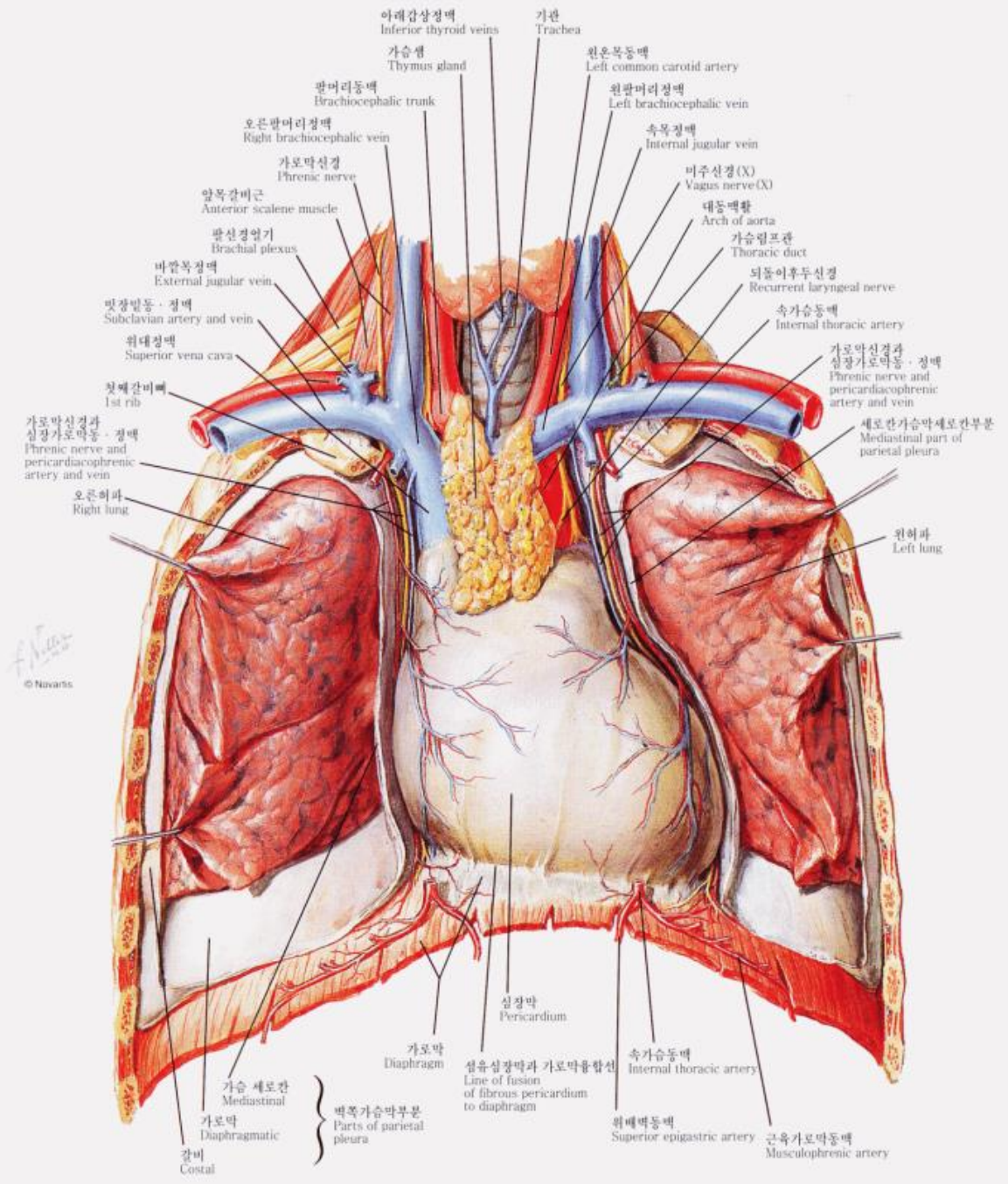


Normal cardiac anatomy

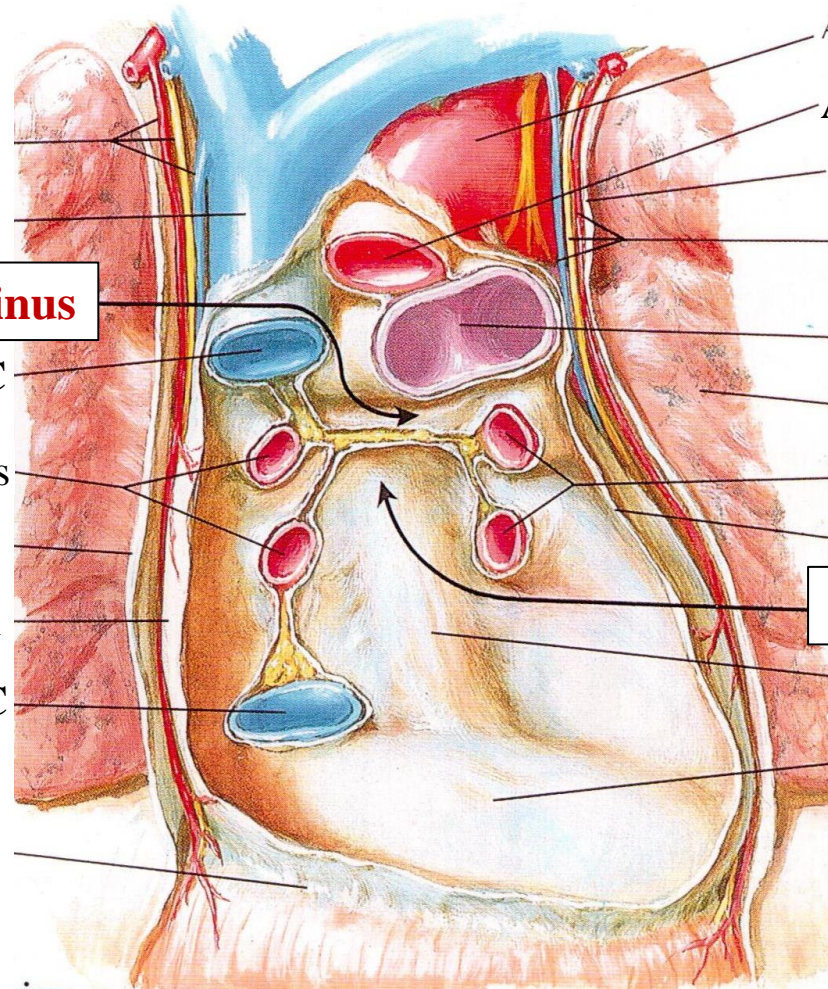
Woo Sung Jang, MD, PhD

Keimyung University Dongsan Medical Center



© Navaris

Pericardium



Transverse pericardial sinus

SVC

Right pulmonary veins

Pericardium

IVC

Aorta

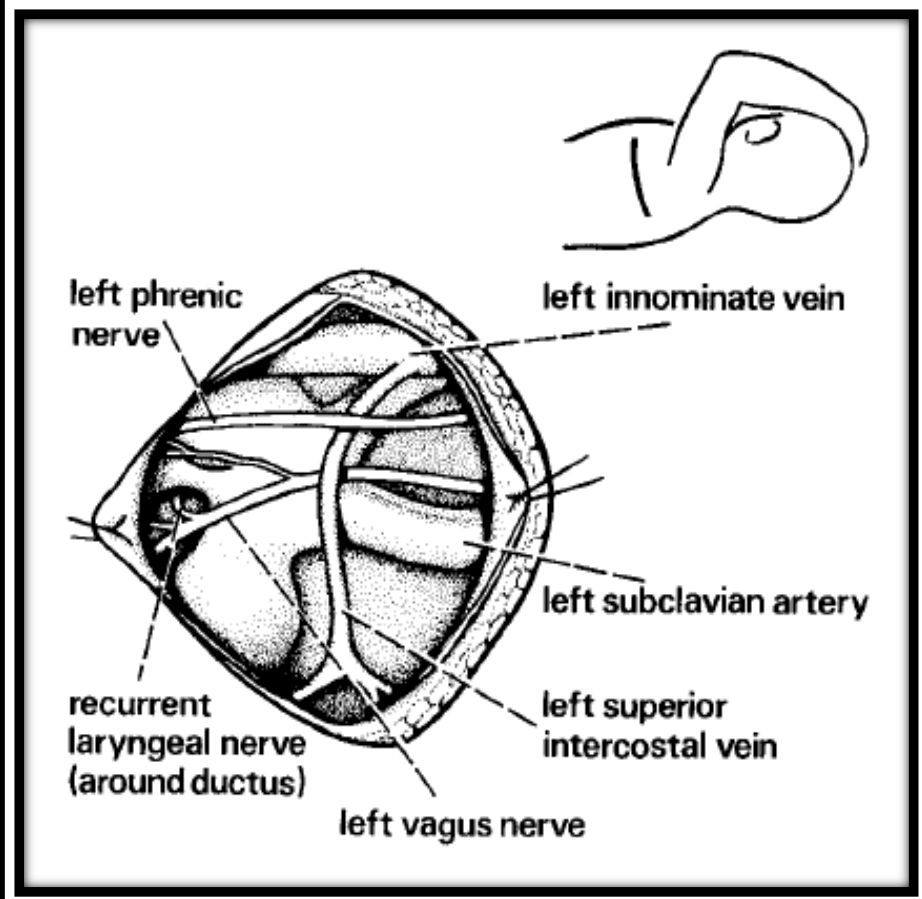
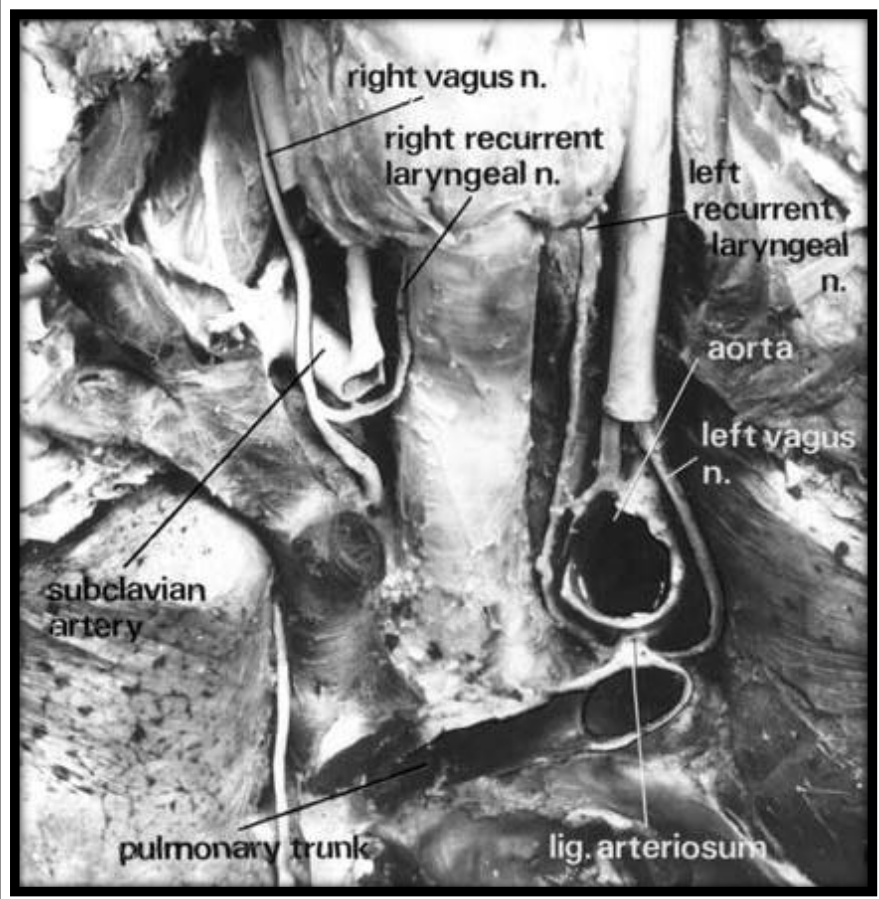
Pulmonary trunk

Left pulmonary veins

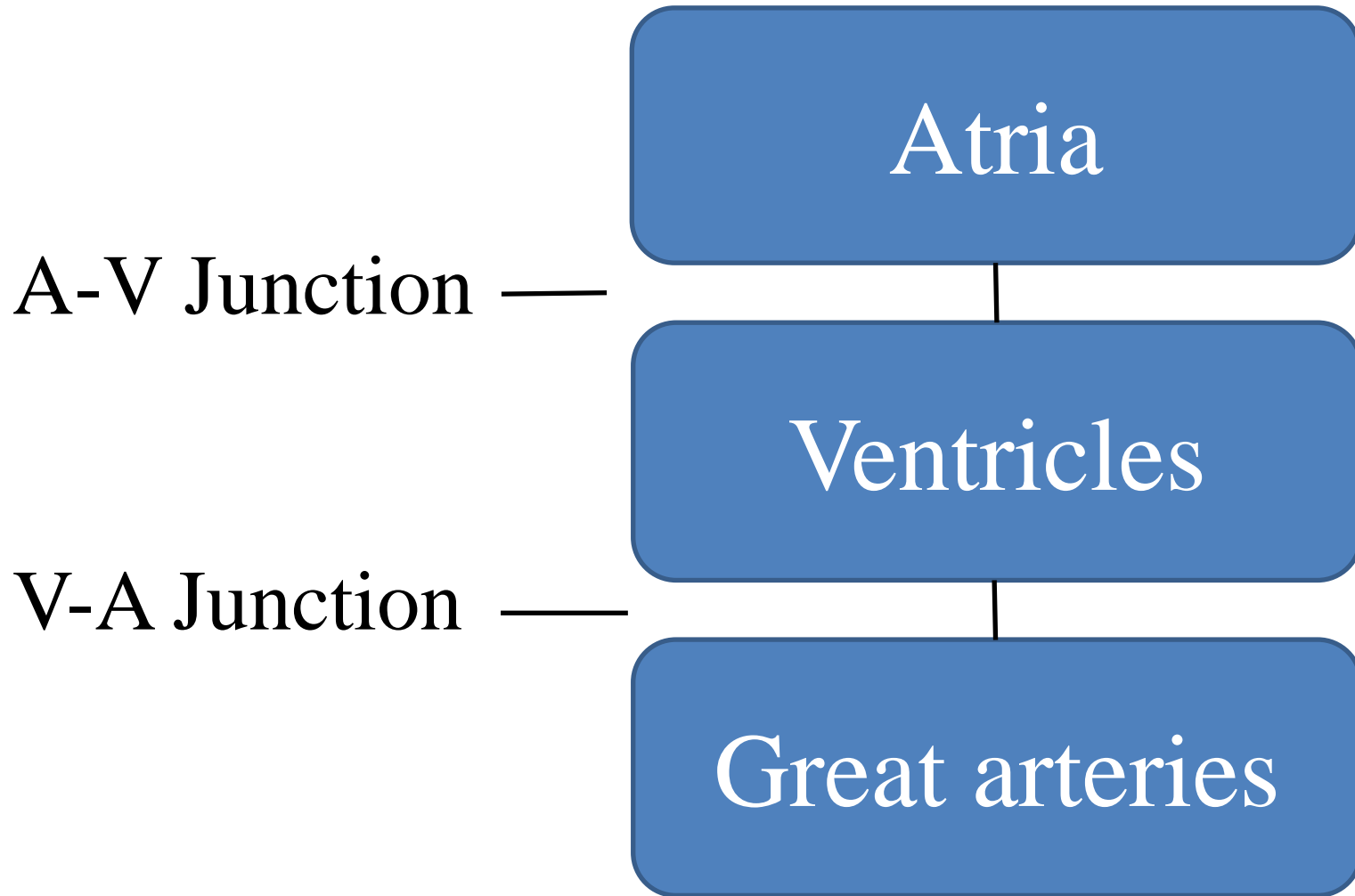
Pericardium

Oblique pericardial sinus

Esophageal prominence

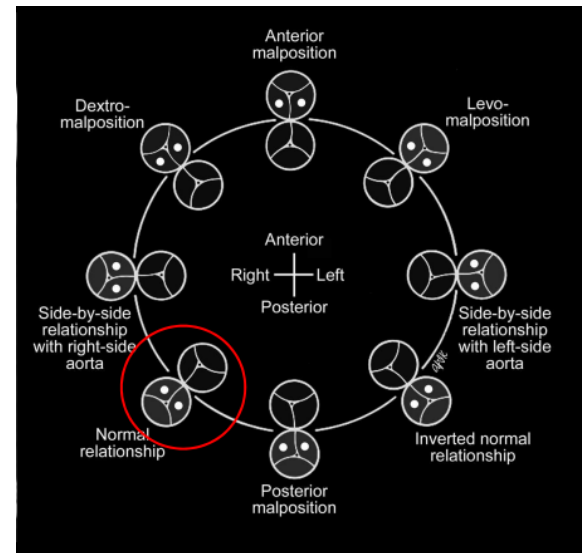


Segments of the heart

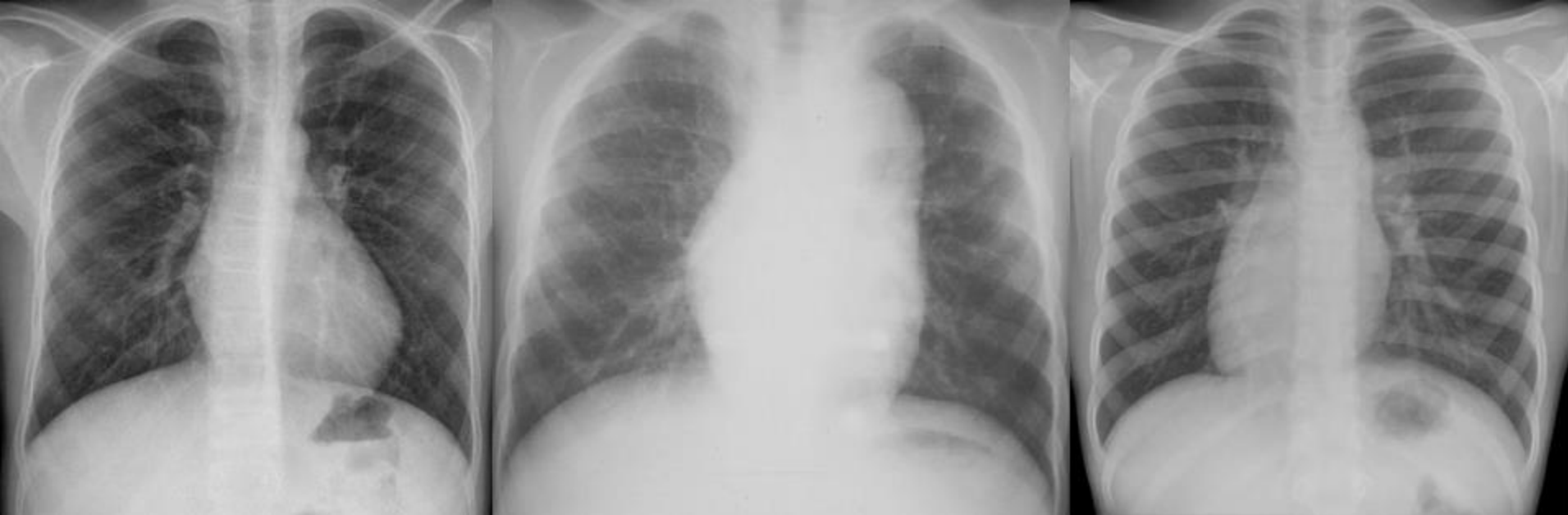

Three Facets

- Morphology
- Relationship
- Connection



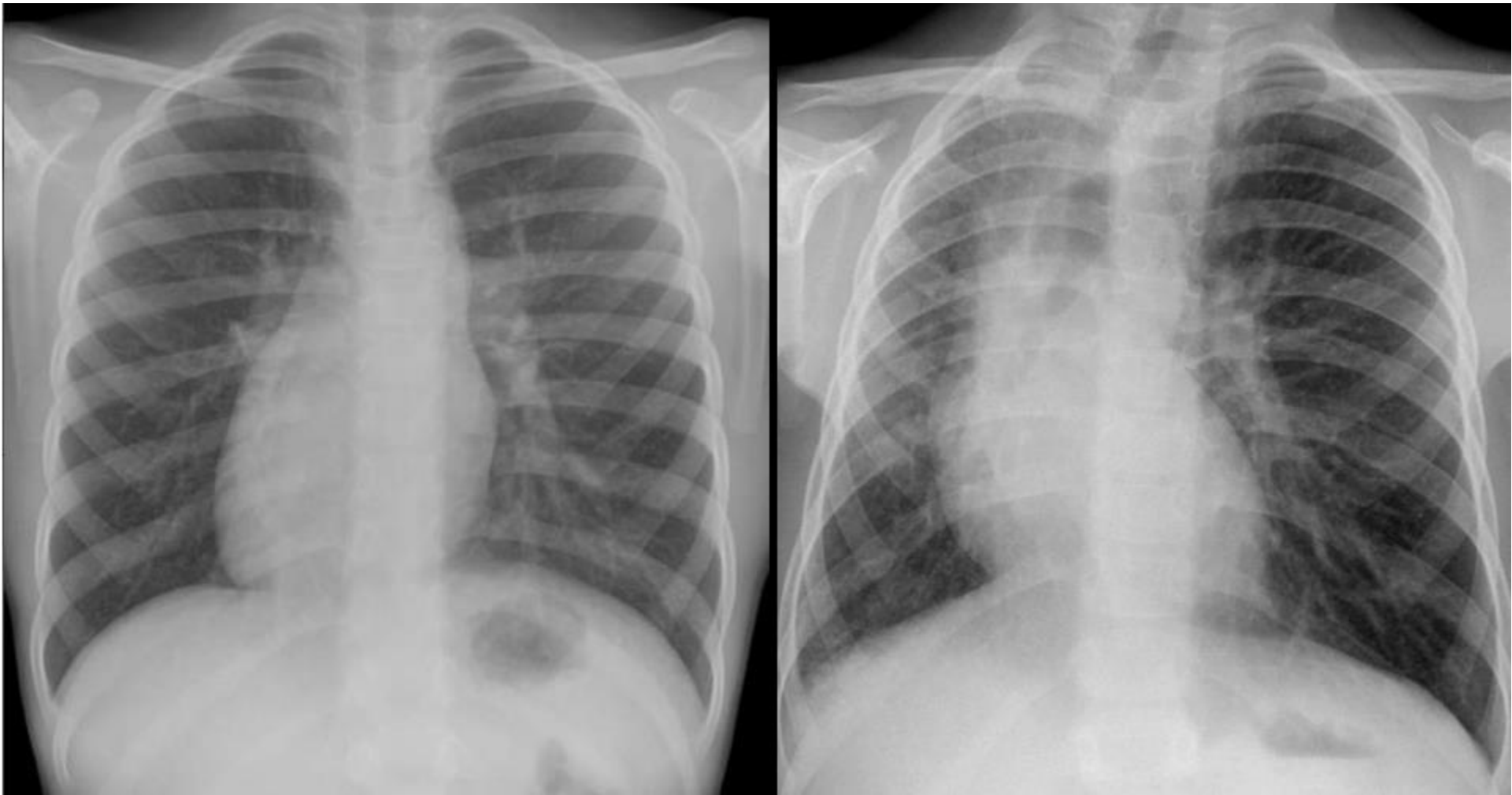
Heart Position



Levocardia

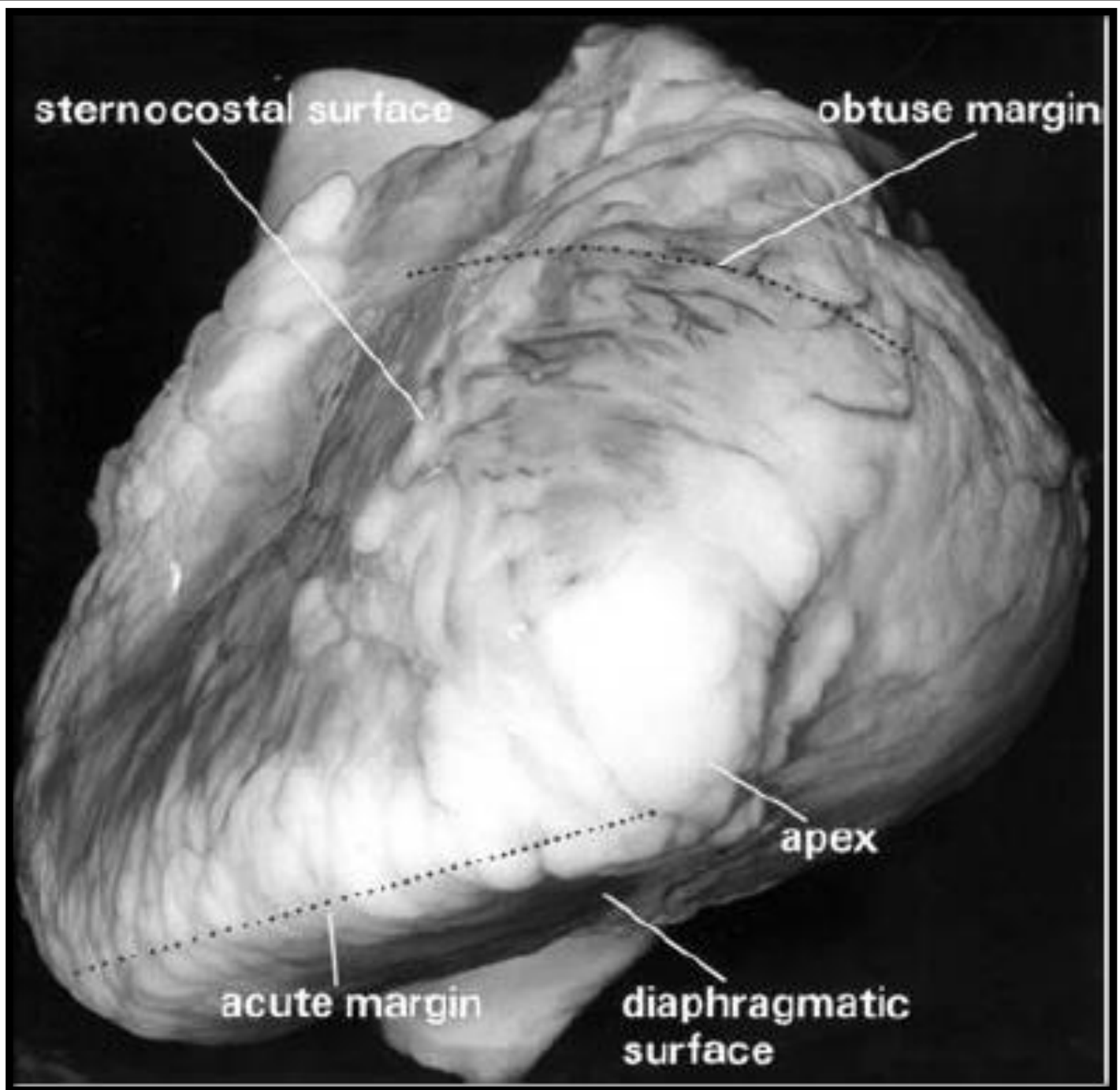
Mesocardia

Dextrocardia



‘Dextrocardia’ VS “Displacement’

Normal cardiac anatomy



sternocostal surface

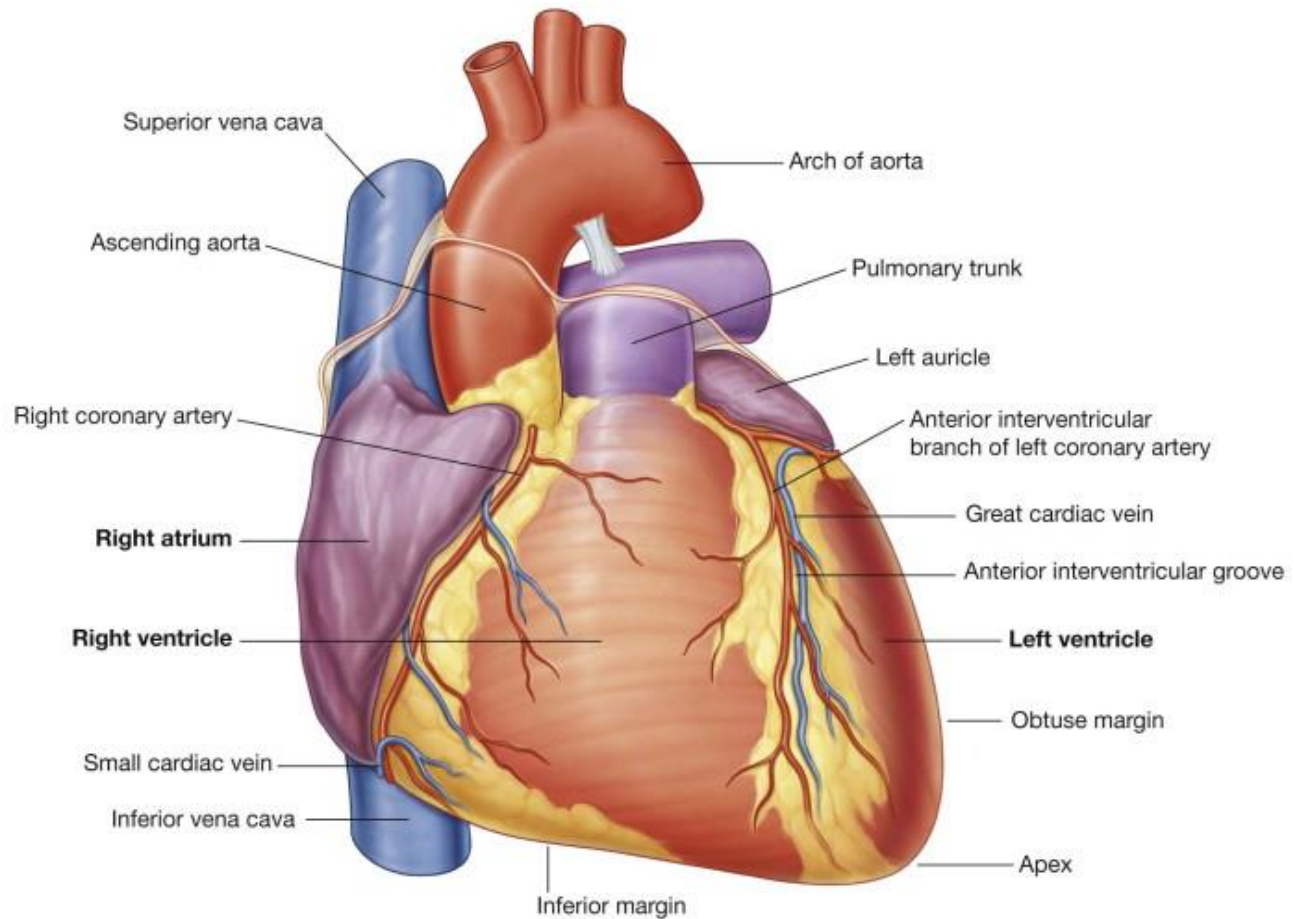
obtuse margin

apex

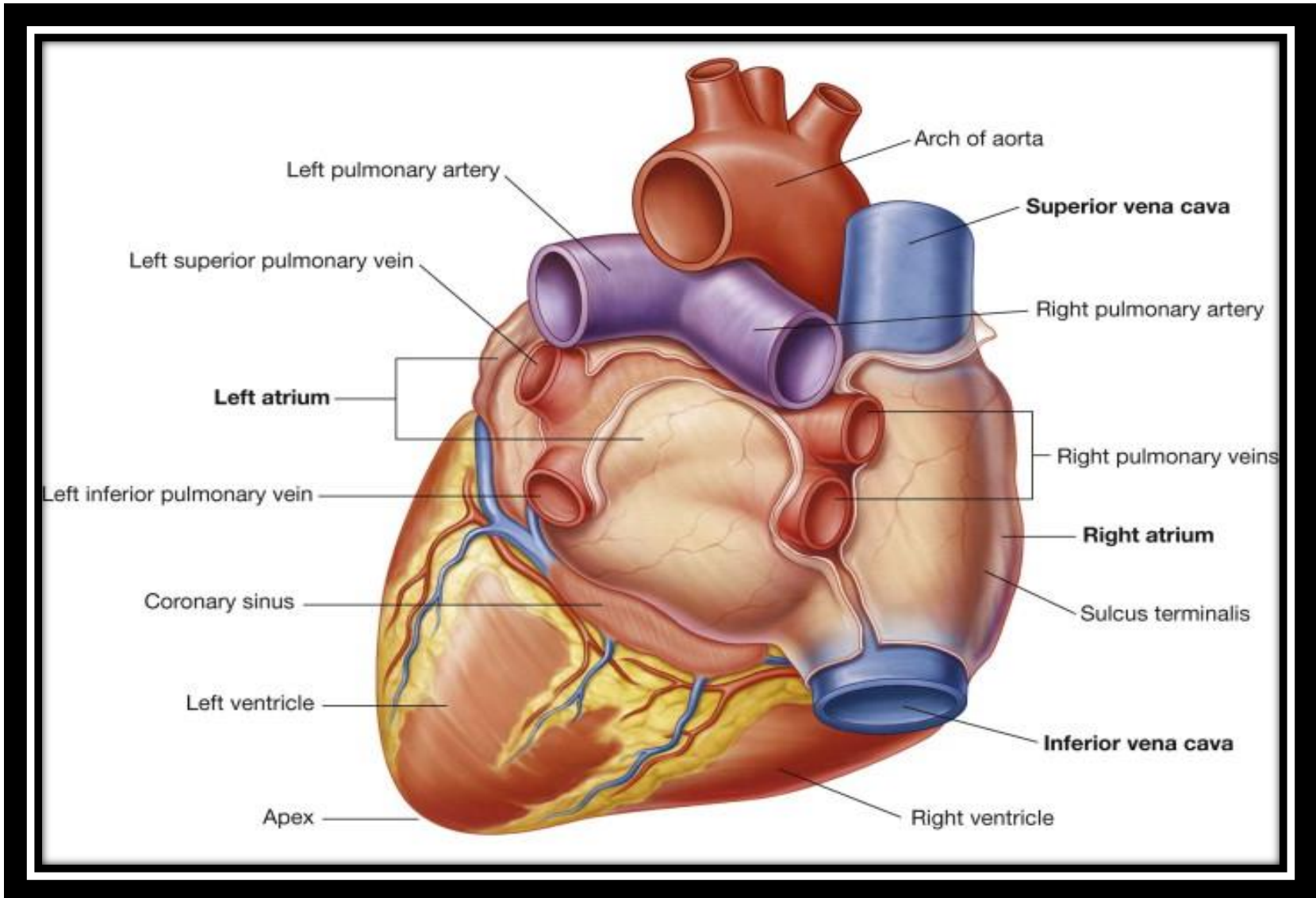
acute margin

diaphragmatic surface

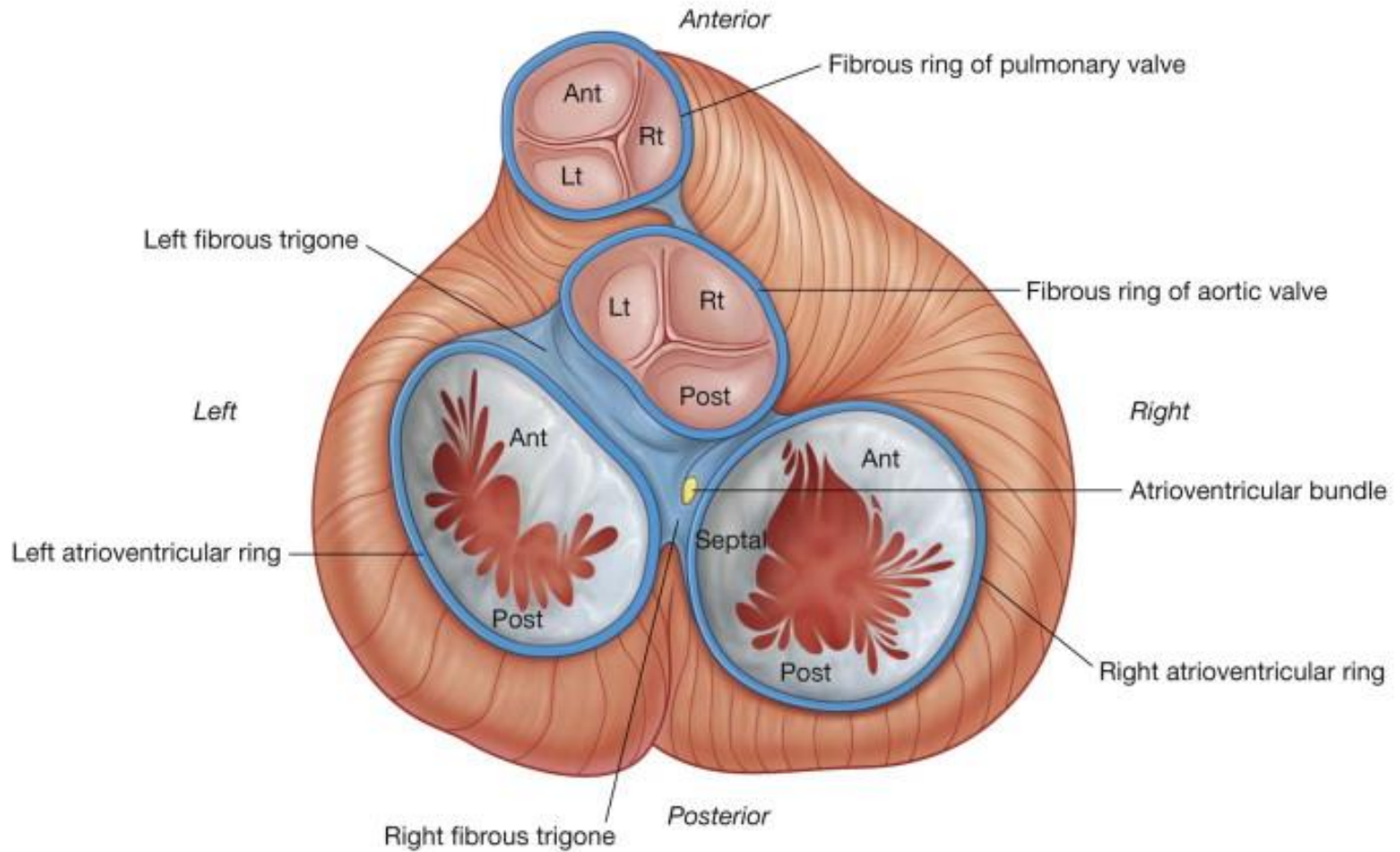
Anterior Surface



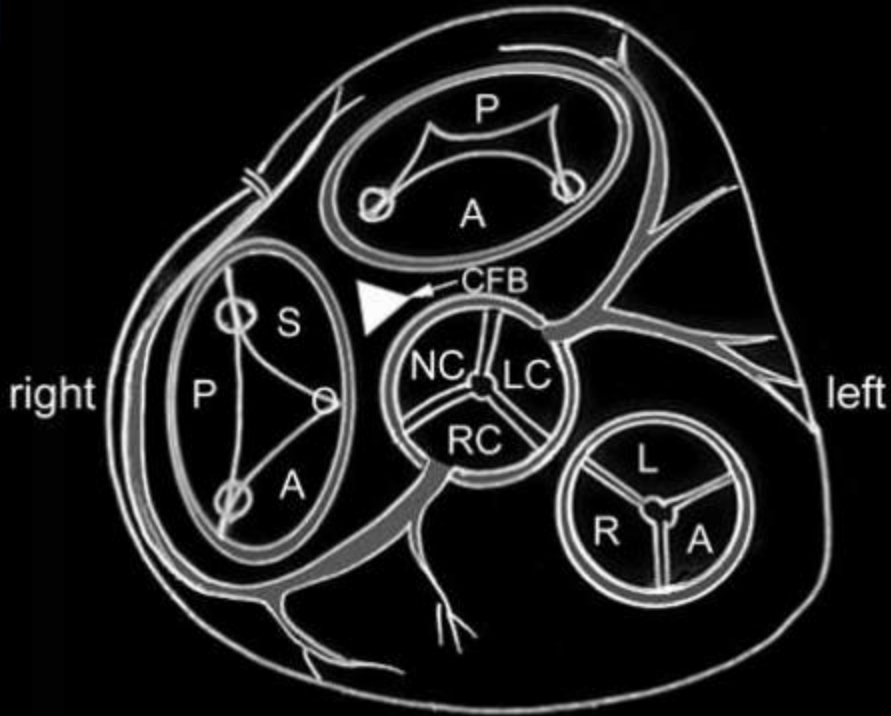
Posterior Surface



Heart Valves

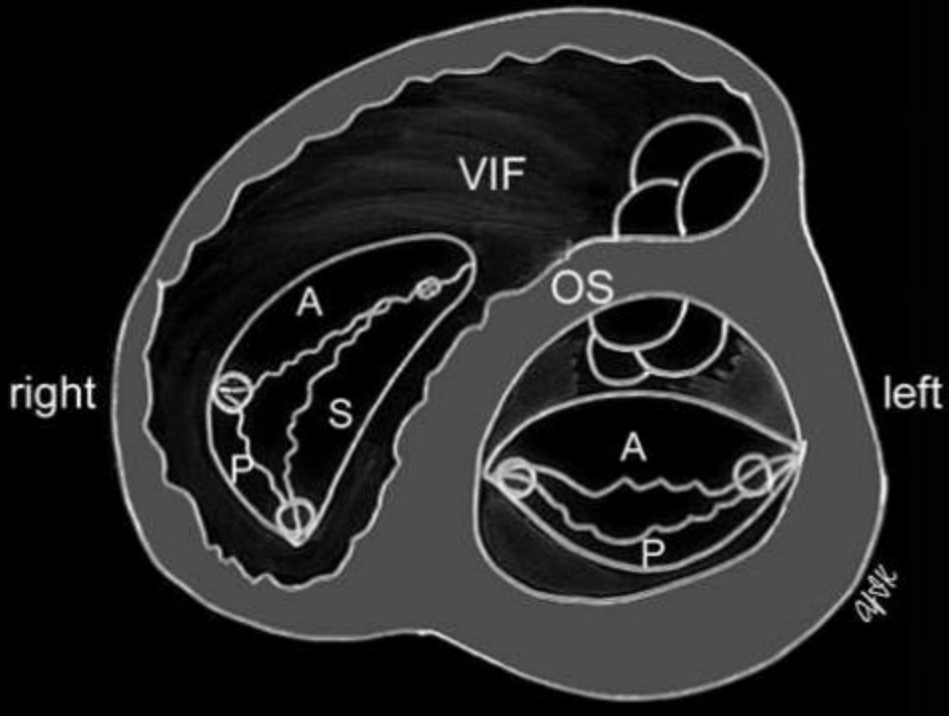


posterior / inferior



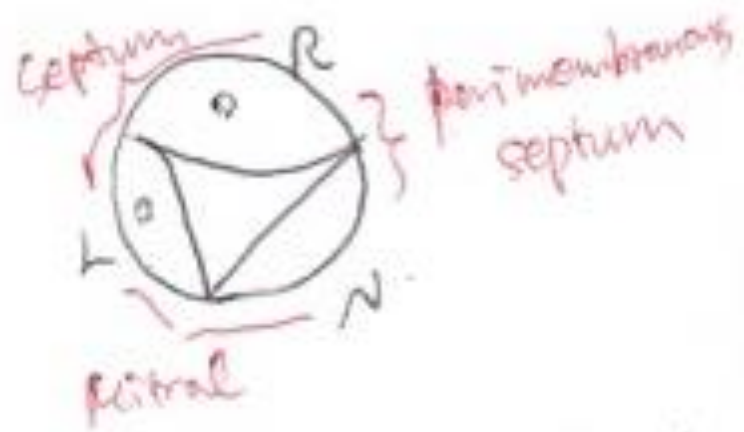
anterior / superior

anterior / superior

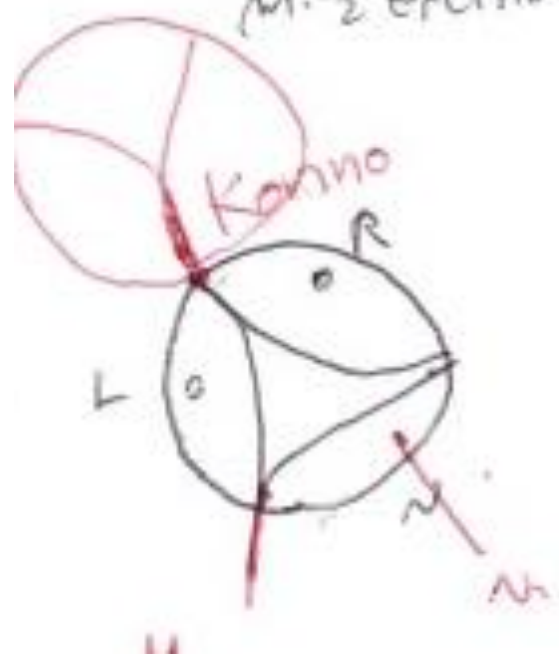

posterior / inferior

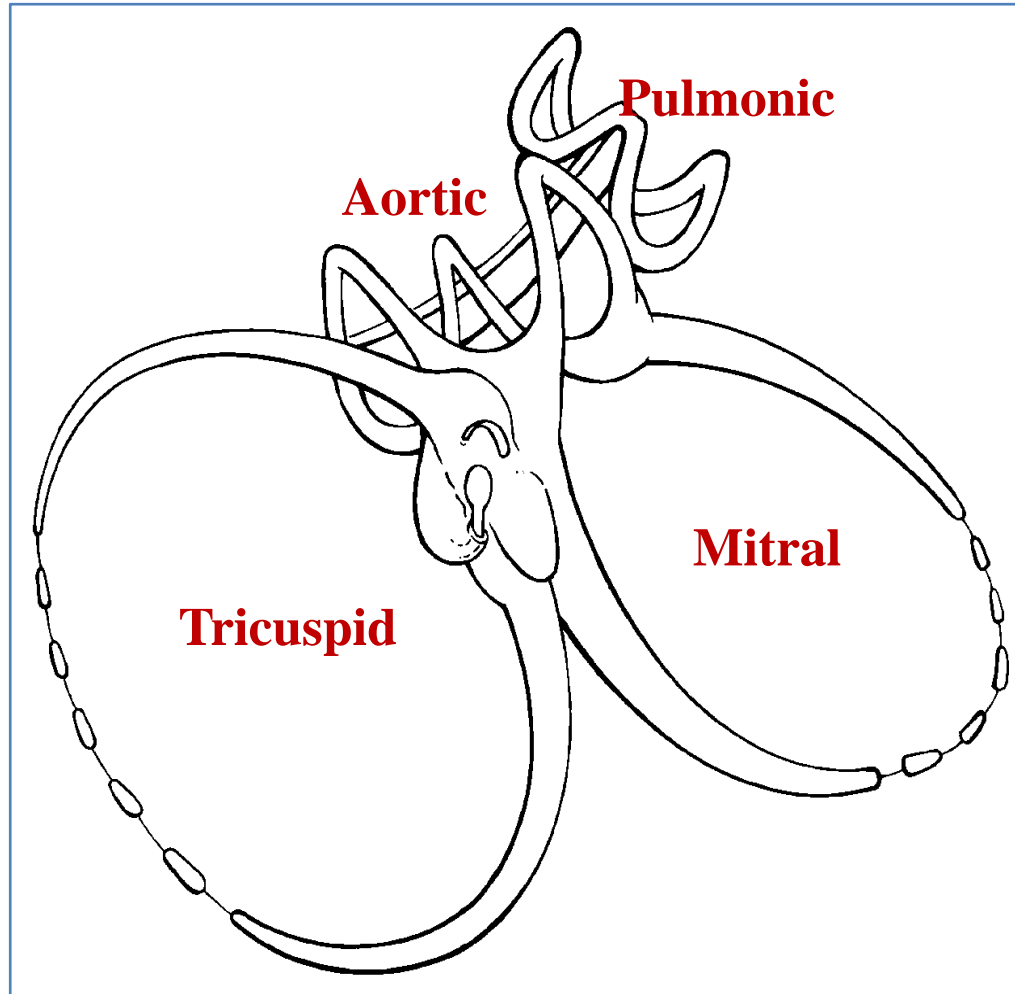
< Surgeon's View >



∴ H.C.M.P. $\frac{1}{2}$ Septum
M. $\frac{1}{2}$ Excretion



Fibrous Skeleton



Atrial Identification

- Atrial appendages
- Pectinate muscles
- Crista terminalis
- Septal morphology
- Not by venous connections

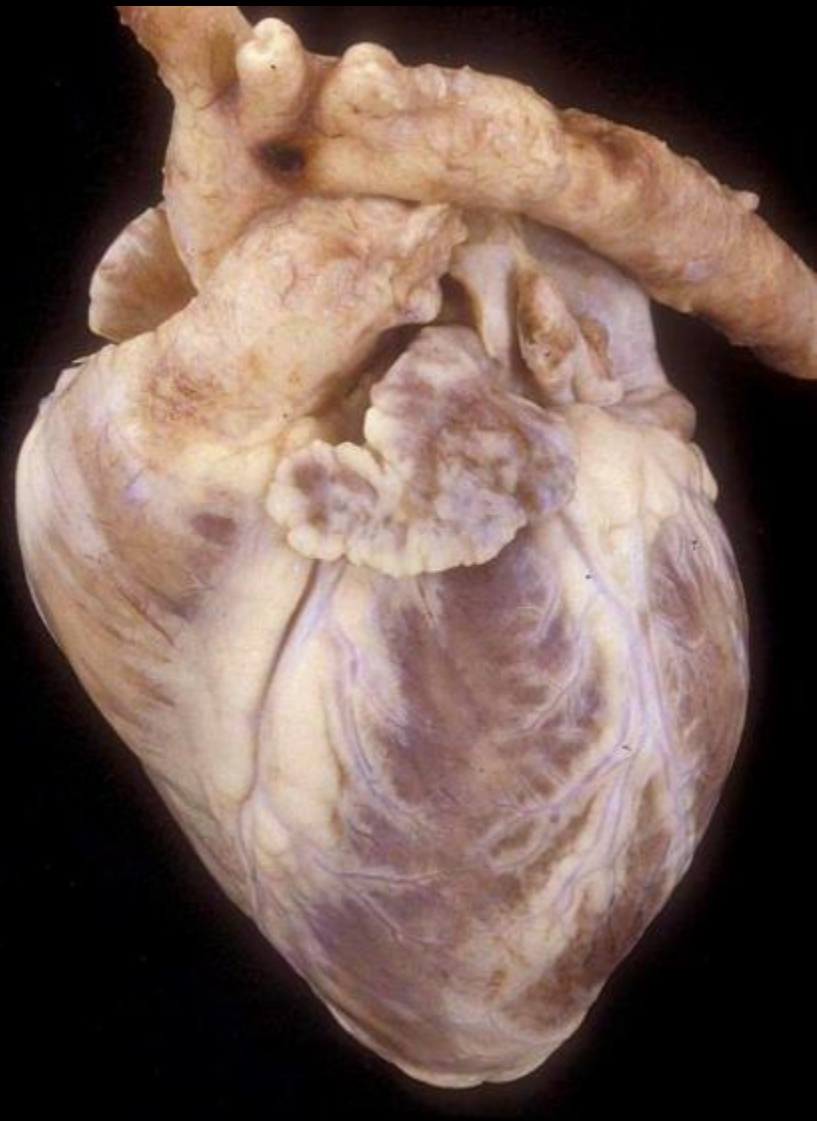
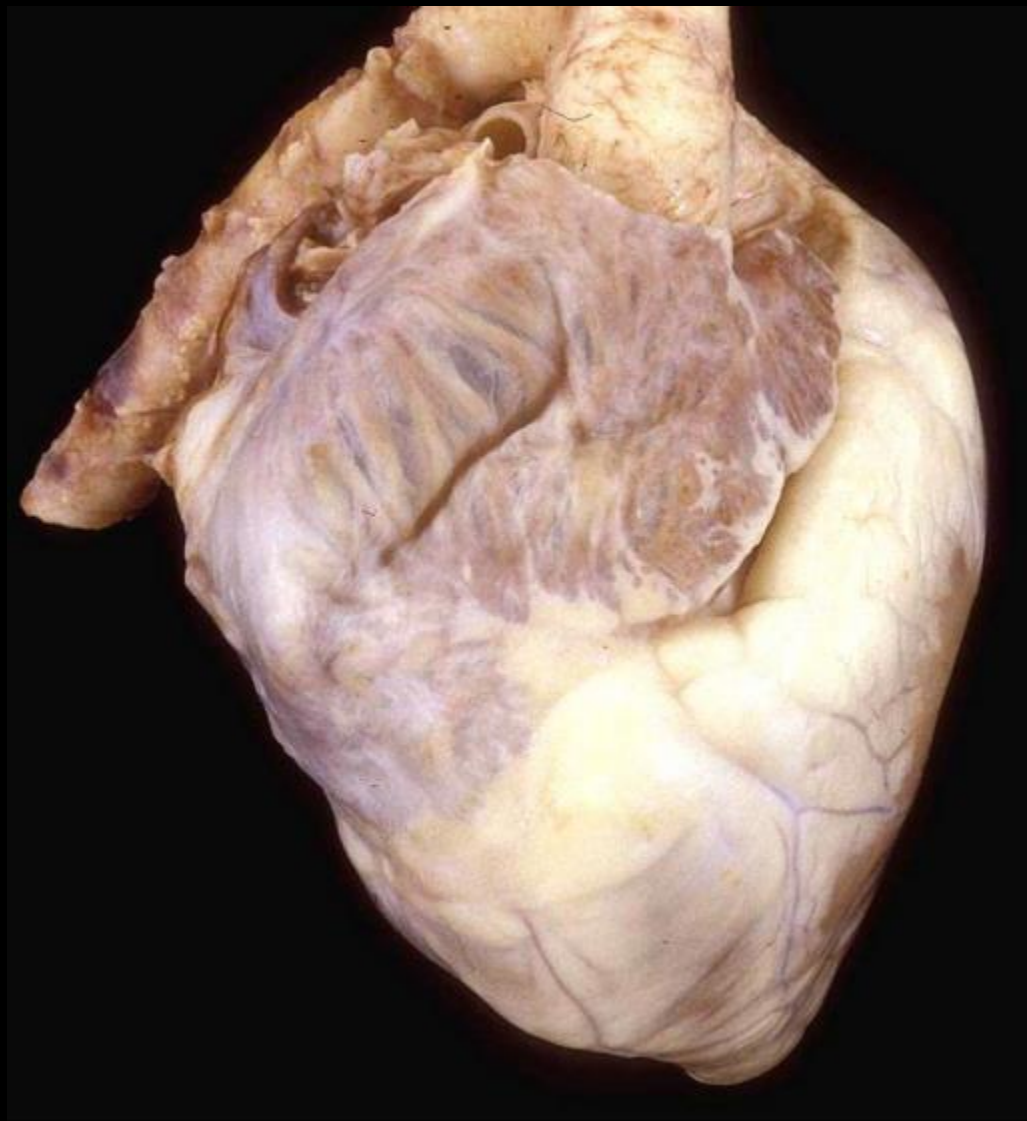
Atria

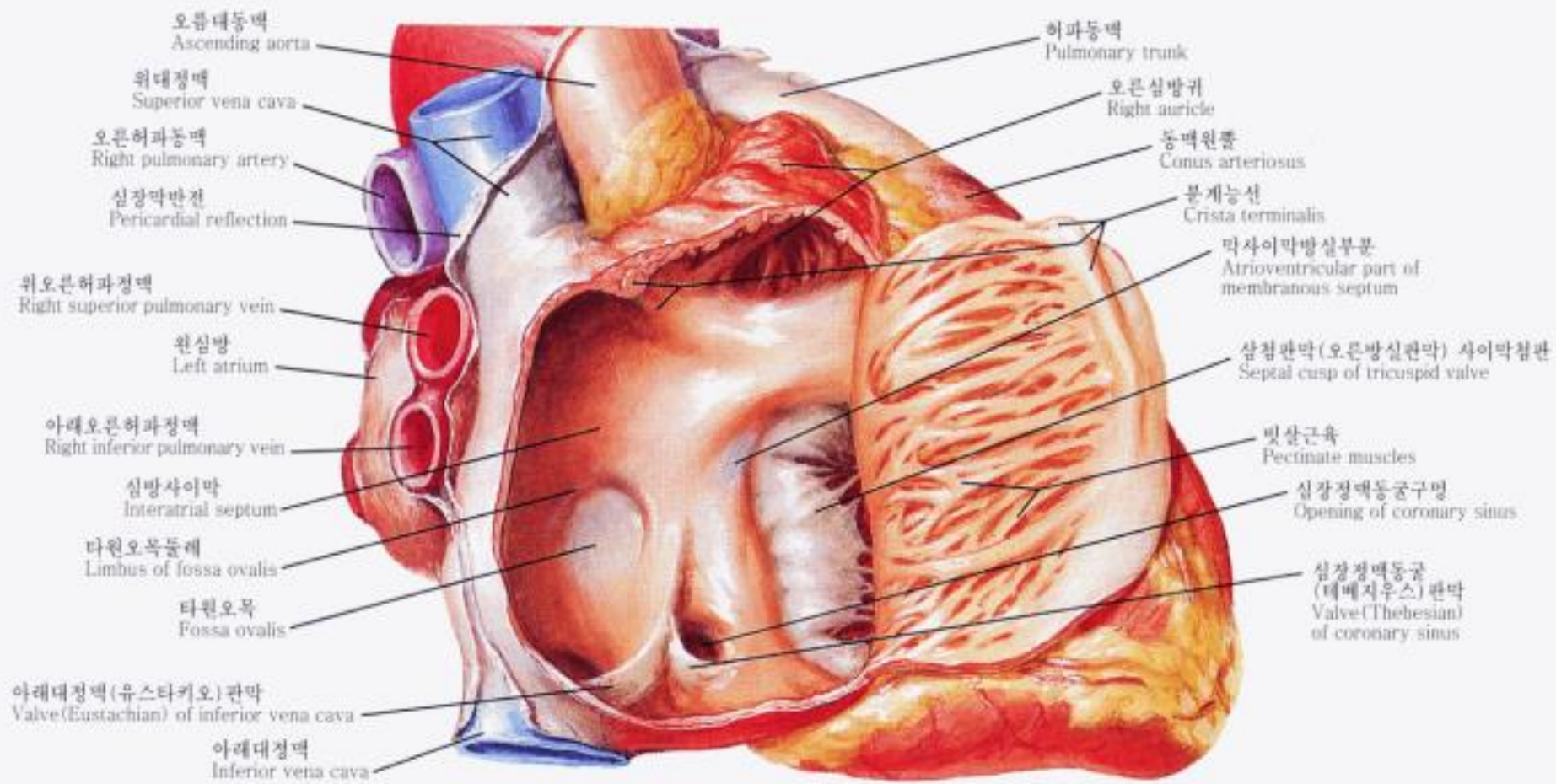
Right atrium

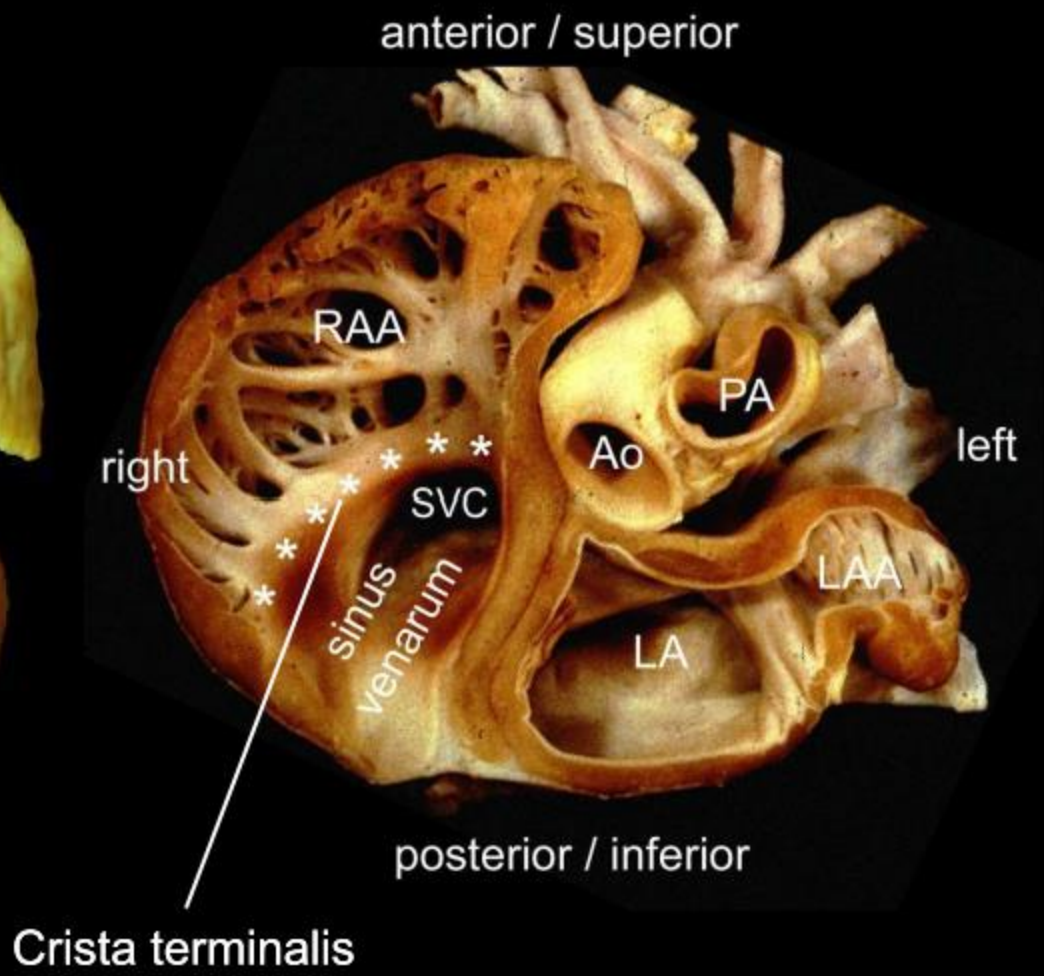
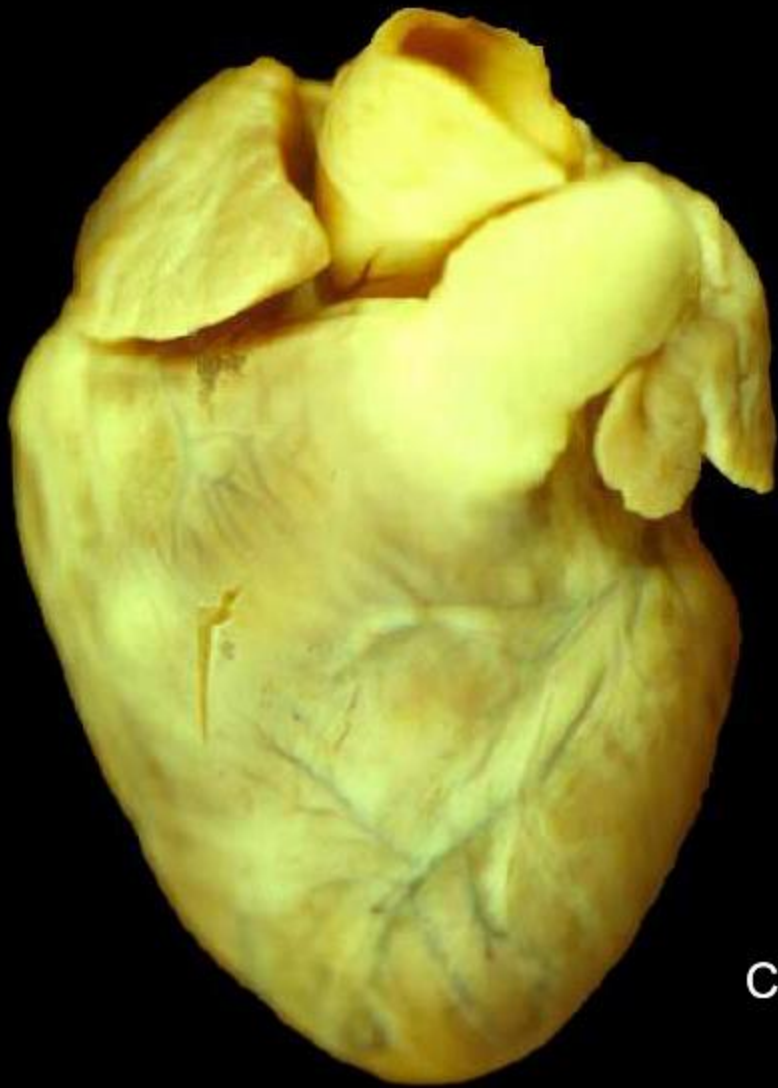- Triangular appendage with a broad junction
- Pectinate muscles extending to AV junction
- Crista terminalis
- Fossa ovalis with a limb

Left atrium

- Finger-like appendage with a narrow junction
- Pectinate muscles not extending to AV junction
- No crista terminalis
- No fossa ovalis







anterior / superior

RAA

PA

Ao

left

right

SVC

LAA

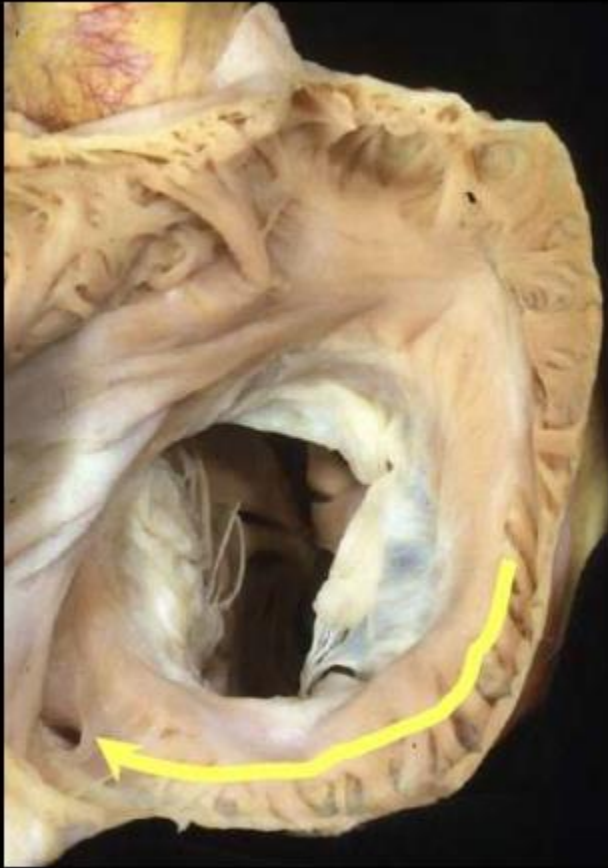
LA

posterior / inferior

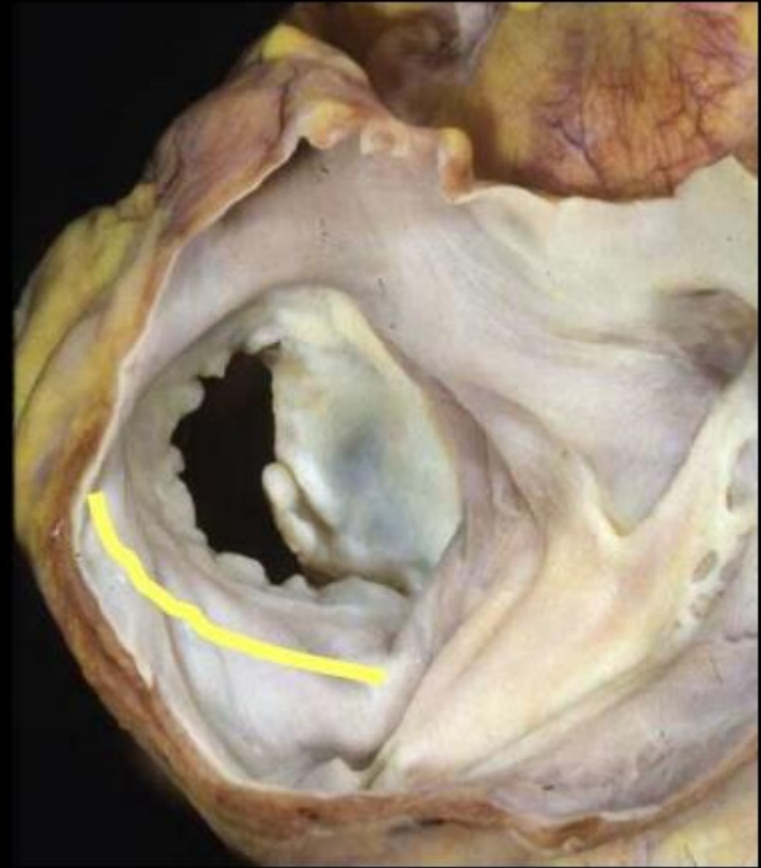
sinus
venarum

Crista terminalis

Extent of pectinate muscles

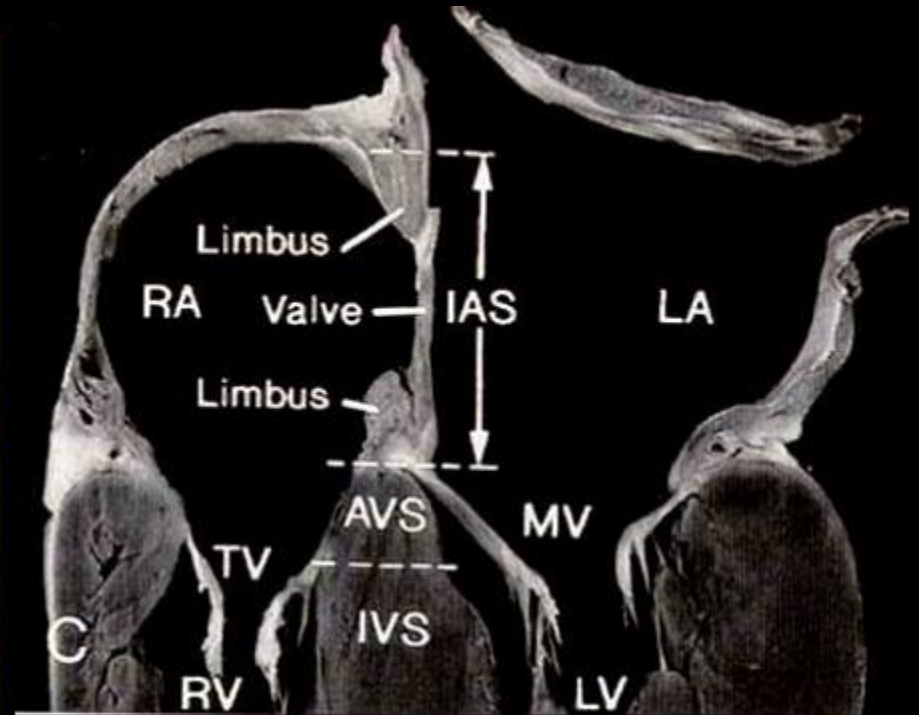
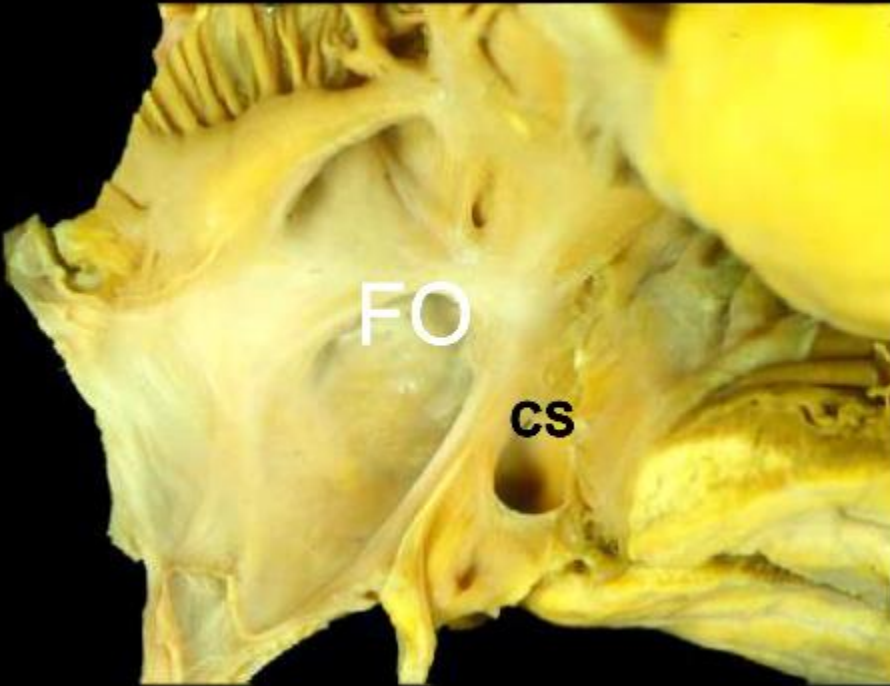


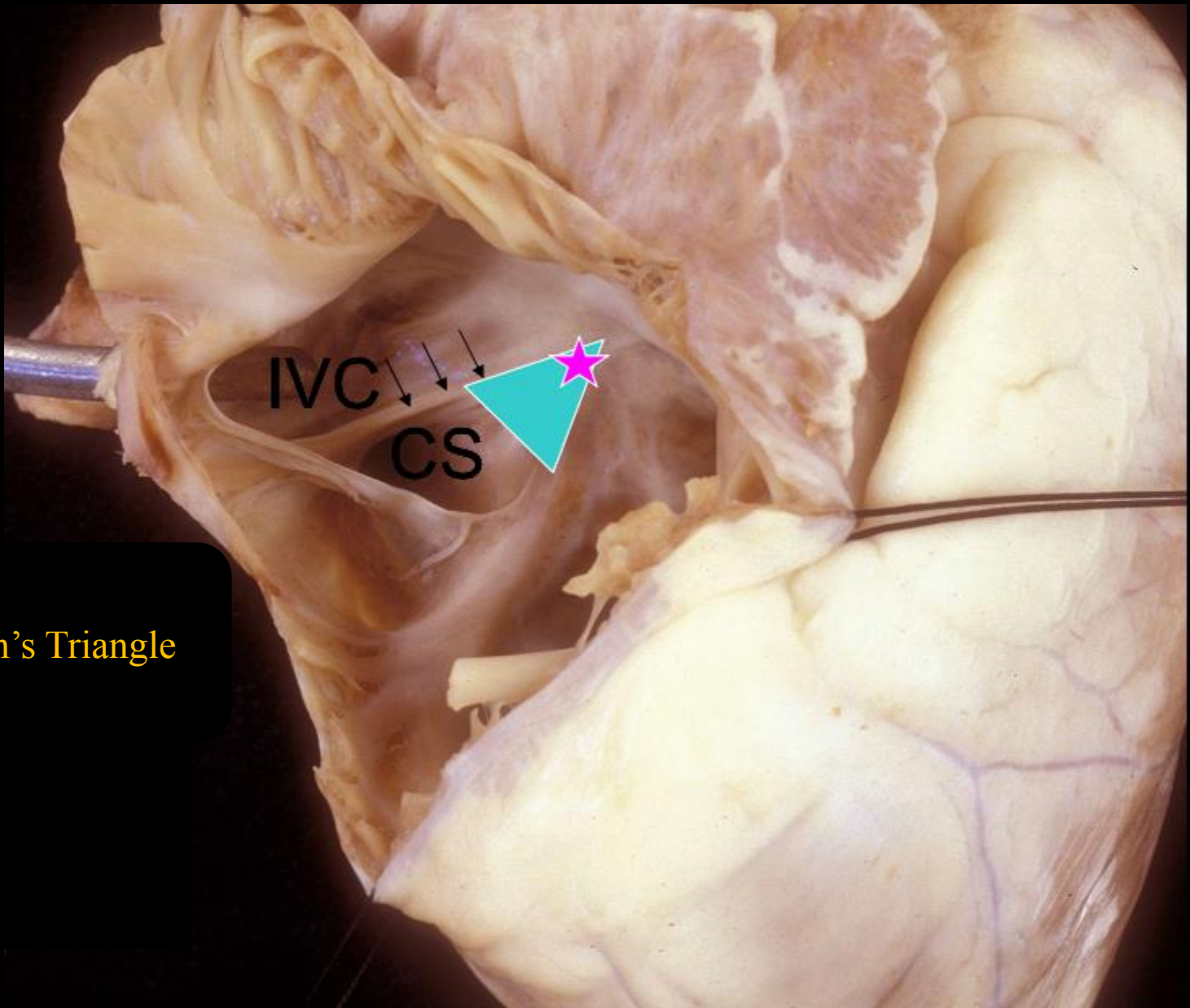
RA




LA

Interatrial septum





Koch's Triangle



aortic valve (non-coronary cusp)

aortic valve (right coronary cusp)

pulmonary valve

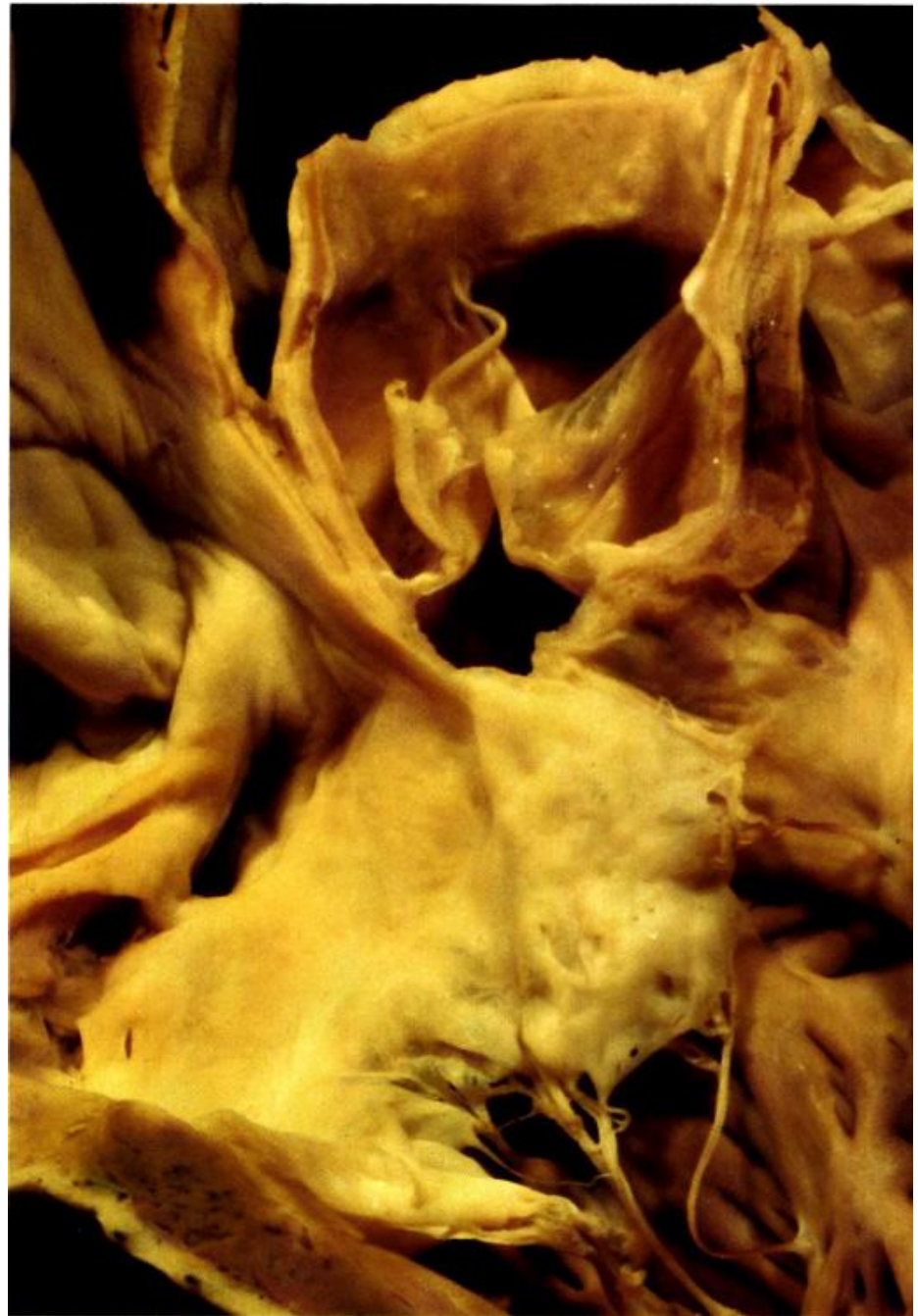infundibular septum

posterior extension (limb)
of trabecula septomarginalis

membranous septum

triangle of Koch

tricuspid septal leaflet



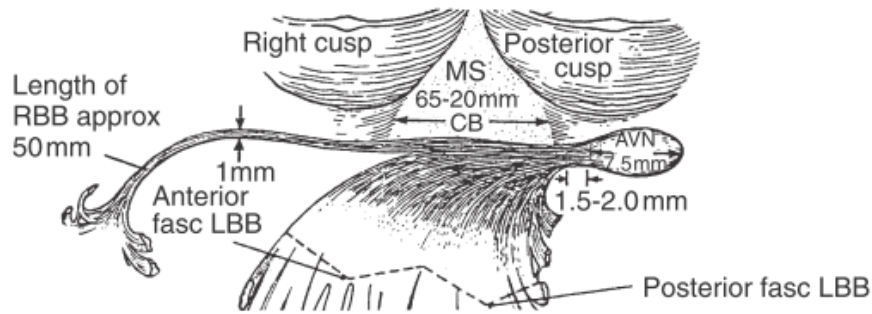


Figure 1-21 Diagram of atrioventricular (AV) conduction system and its relationship to membranous septum and aortic valve, viewed from left ventricular side. AV node is in the AV septum on right atrial side of the right trigone, which is beneath the nadir of the posterior (noncoronary) cusp of aortic valve. Common AV bundle courses along posteroinferior margin of membranous septum, giving off fibers that form the left bundle branch. This region lies beneath the commissure of right and noncoronary (posterior) aortic cusps. Right bundle branch originates from common AV bundle in the region of anteroinferior border of membranous septum. Key: *approx*, Approximately; *AVN*, atrioventricular node; *CB*, branching portion of common atrioventricular bundle; *fasc*, fascicle; *LBB*, left bundle branch; *MS*, membranous septum; *RBB*, right bundle branch. (From Titus.^{T5})

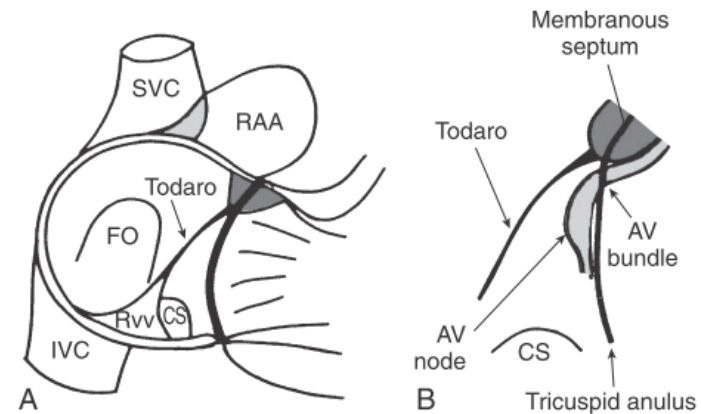
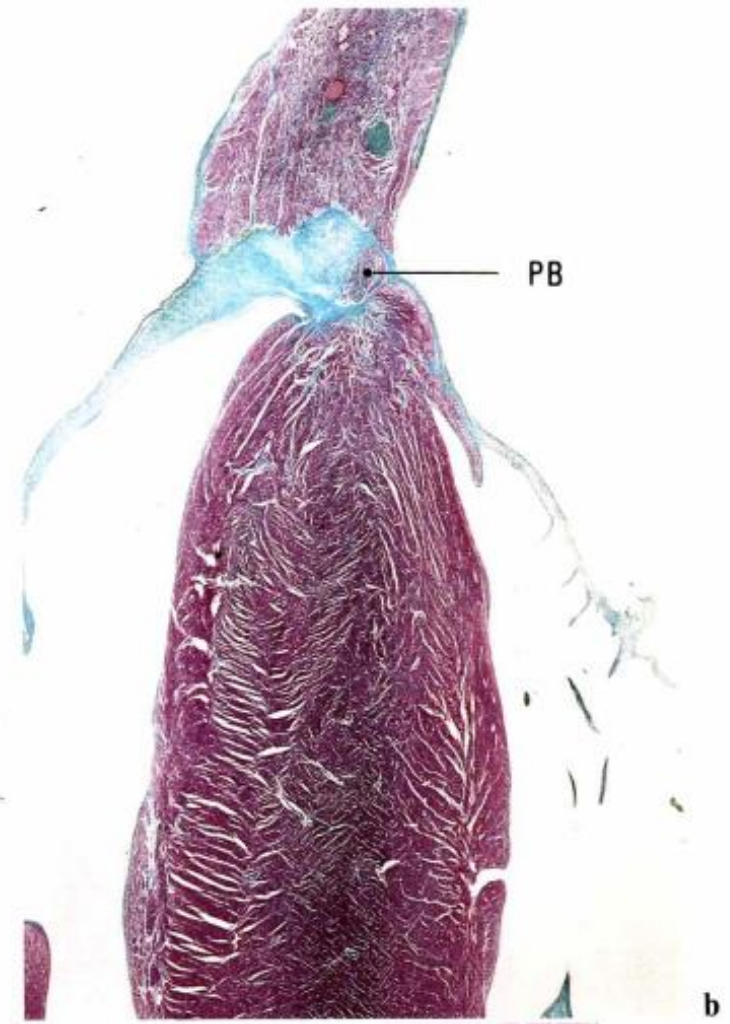
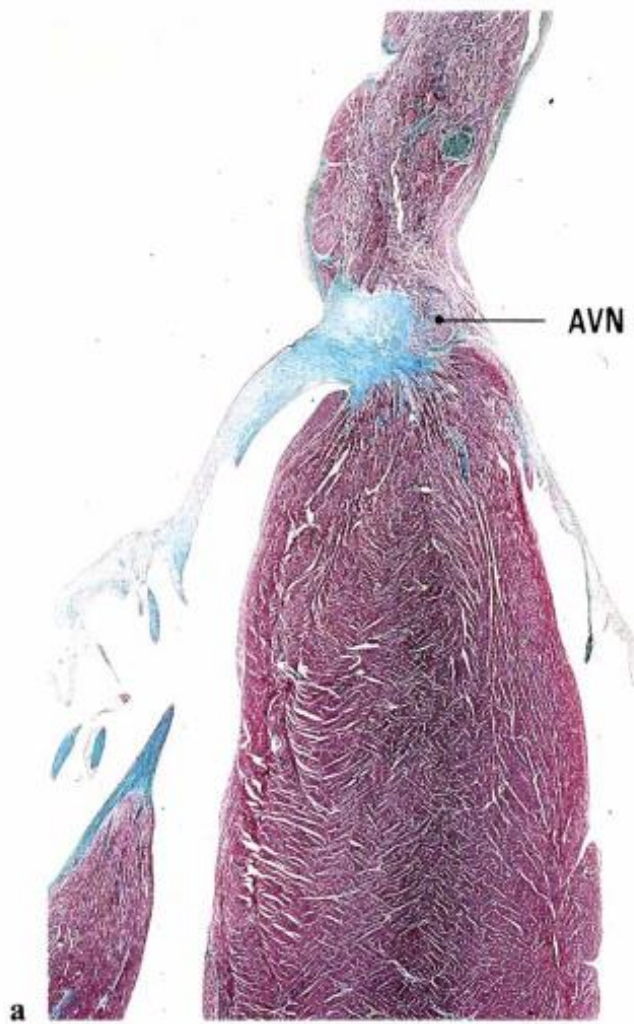
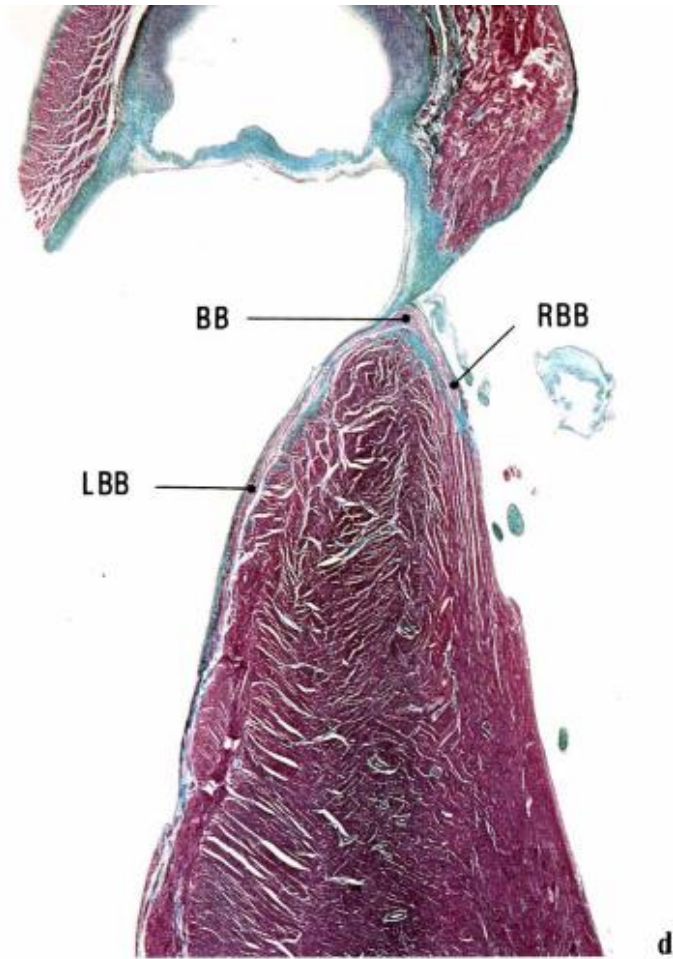
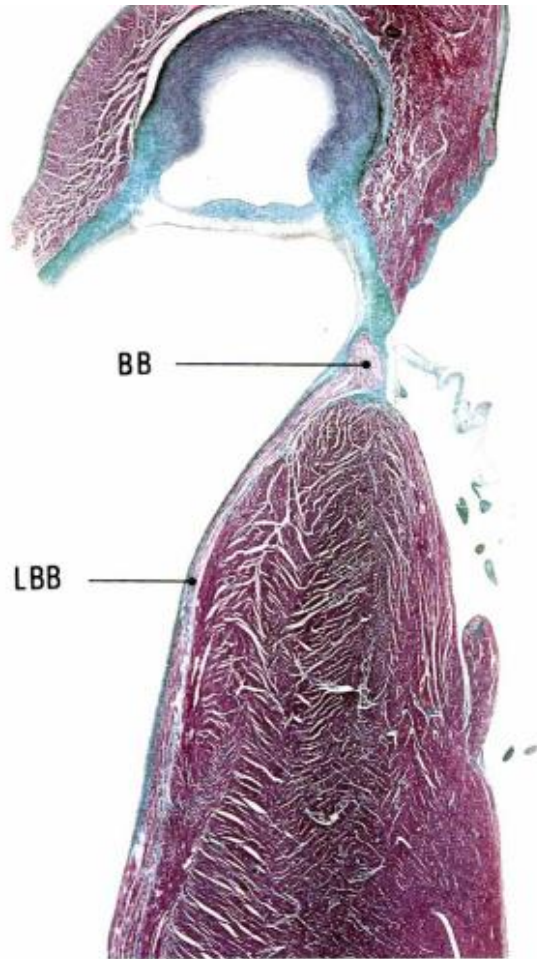
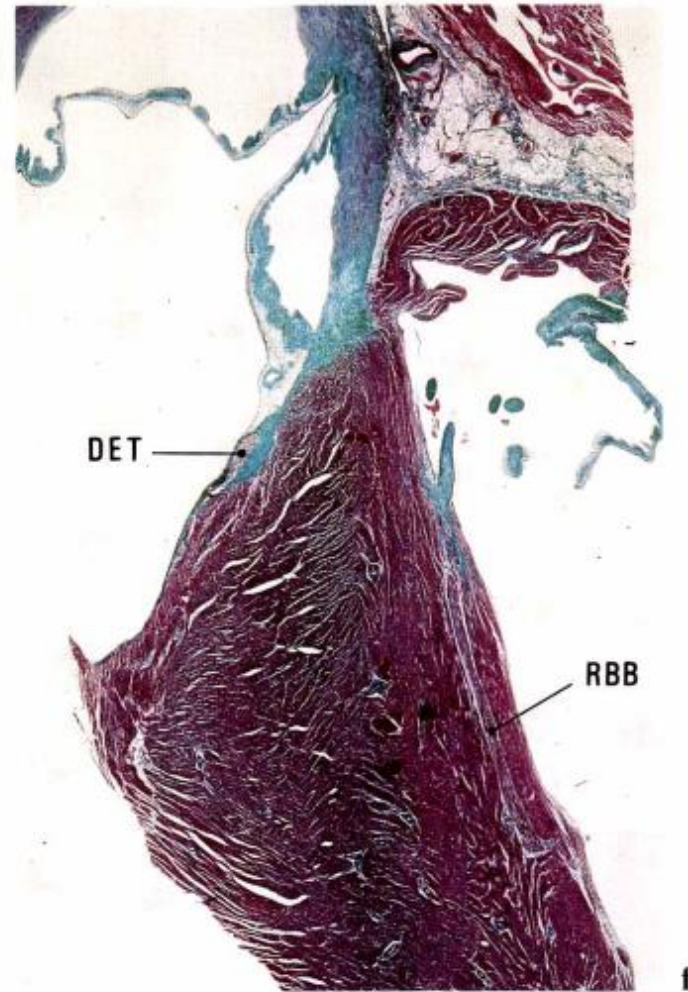
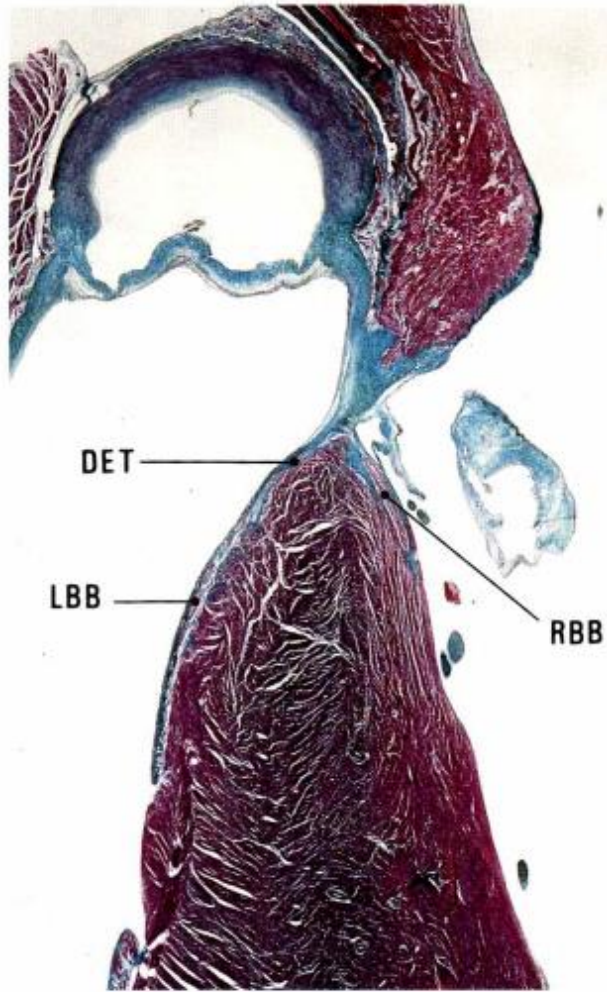


Figure 1-20 Anatomic and surgical aspects of cardiac conduction system. **A**, Diagram of triangle of Koch within right atrium; triangle is defined by tendon of Todaro, orifice of coronary sinus, and tricuspid annulus. **B**, Diagram showing relationship of atrioventricular (AV) node and atrioventricular bundle (bundle of His) to triangle of Koch. AV node lies within the triangle, and AV bundle is located at apex of triangle. CS, Coronary sinus; FO, fossa ovalis; IVC, inferior vena cava; RAA, right atrial appendage; RvV, right venous valve; SVC, superior vena cava. (From Anderson and colleagues.^{A11})







Ventricles

RV

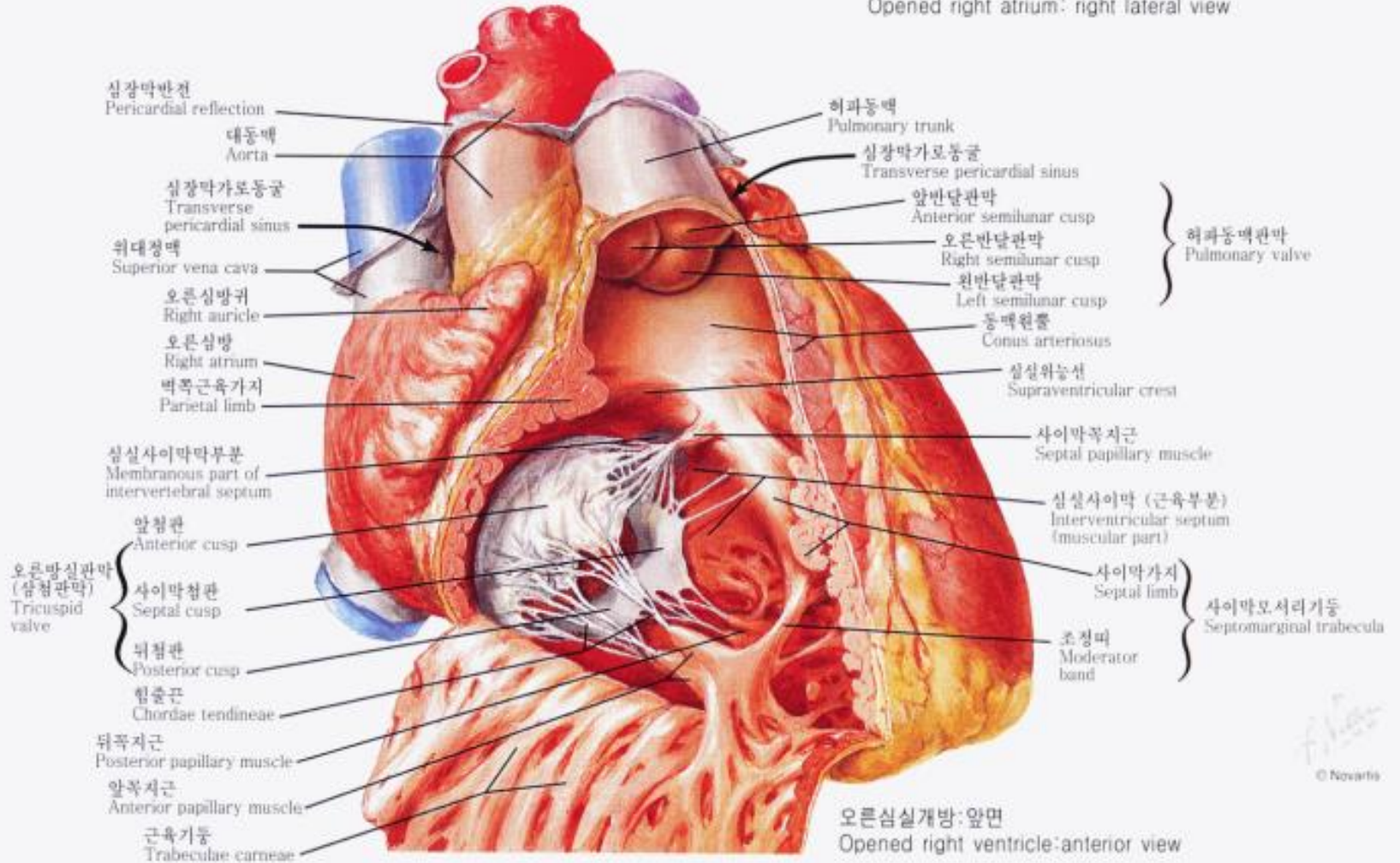
- Trabeculations: heavy and irregular
- Moderator band
- Septal attachment of AV valve: more apical
- Septal attachment of papillary muscles

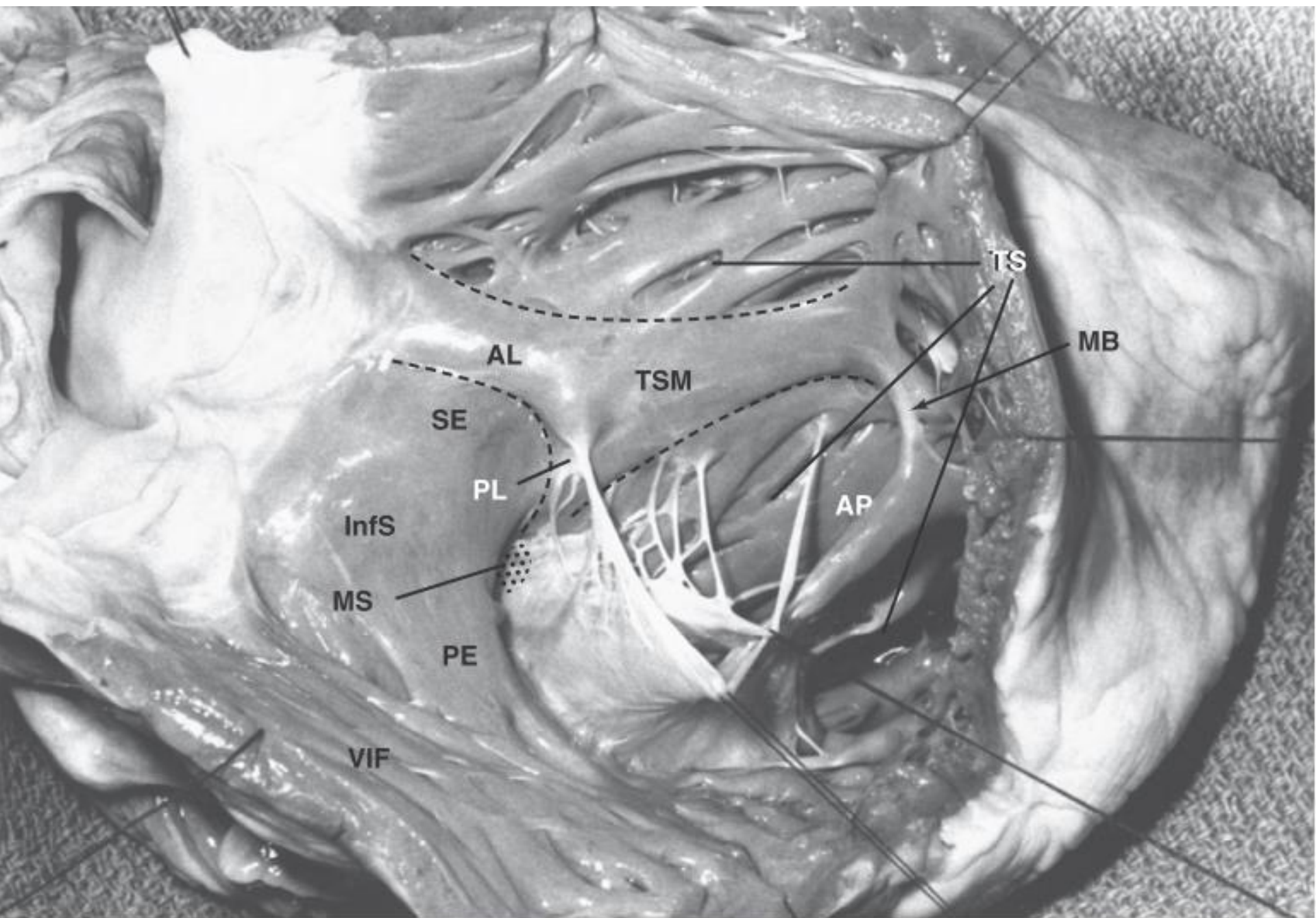
LV

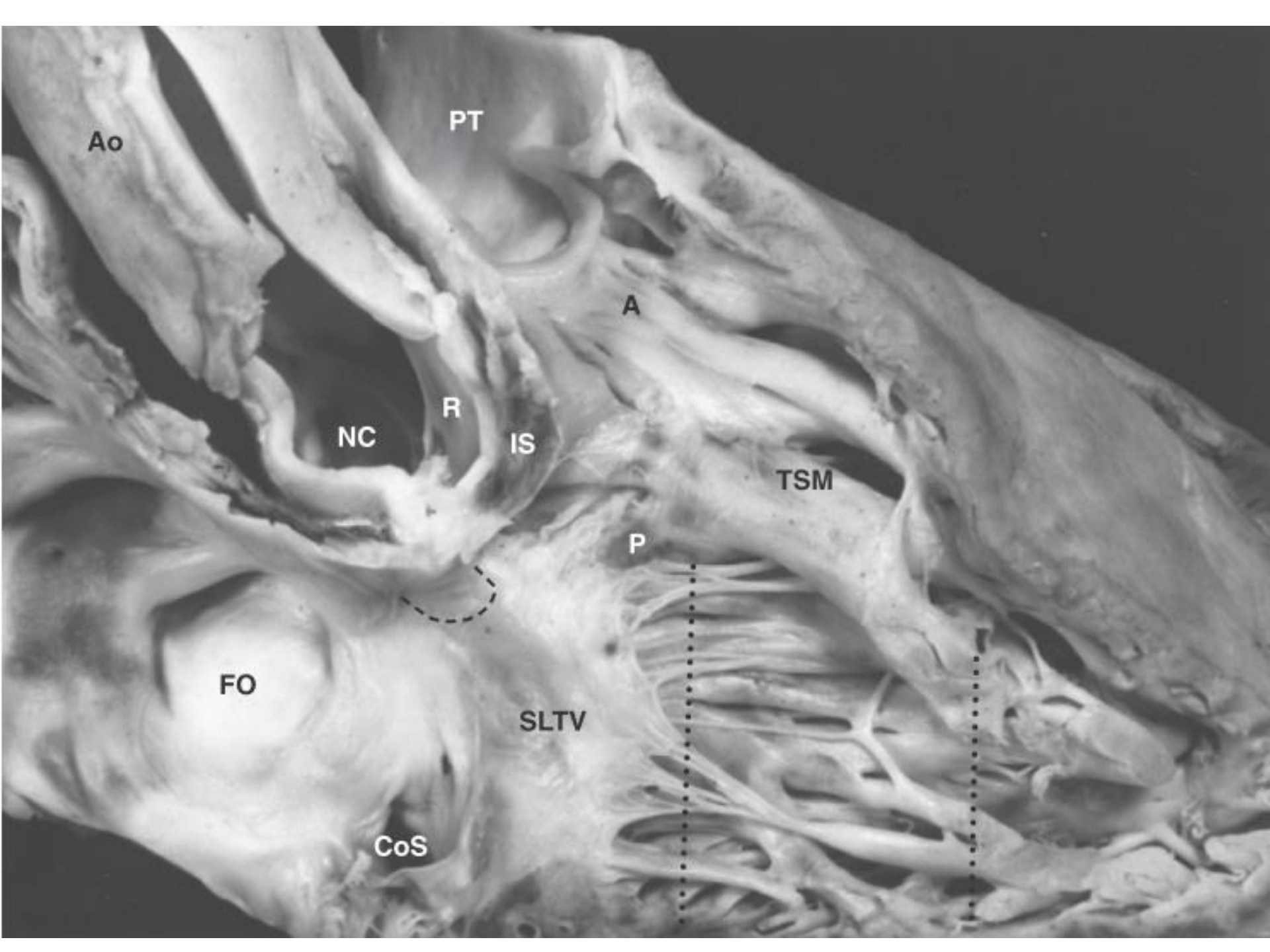
- Trabeculations: fine and regular
- No moderator band
- Septal attachment of AV valve: more cranial
- No septal attachment of papillary muscles

Right Ventricle

Opened right atrium: right lateral view







Ao

PT

A

NC

R

IS

TSM

P

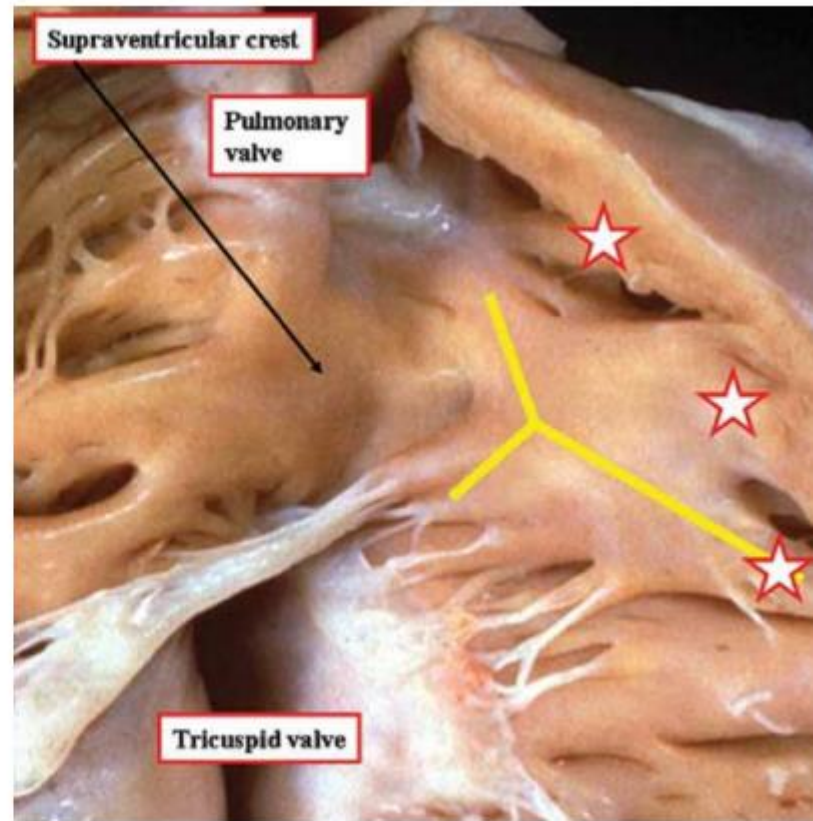
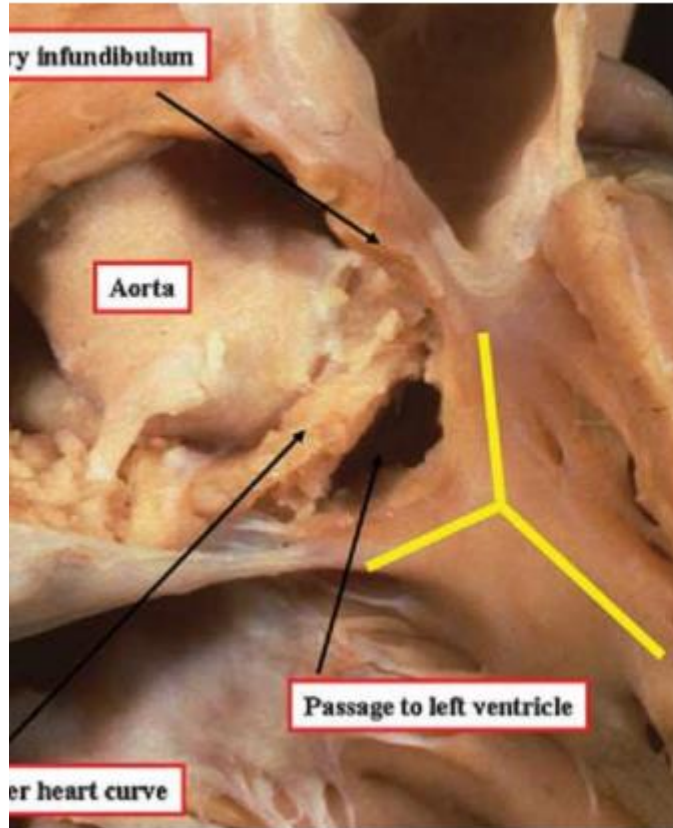
FO

SLTV

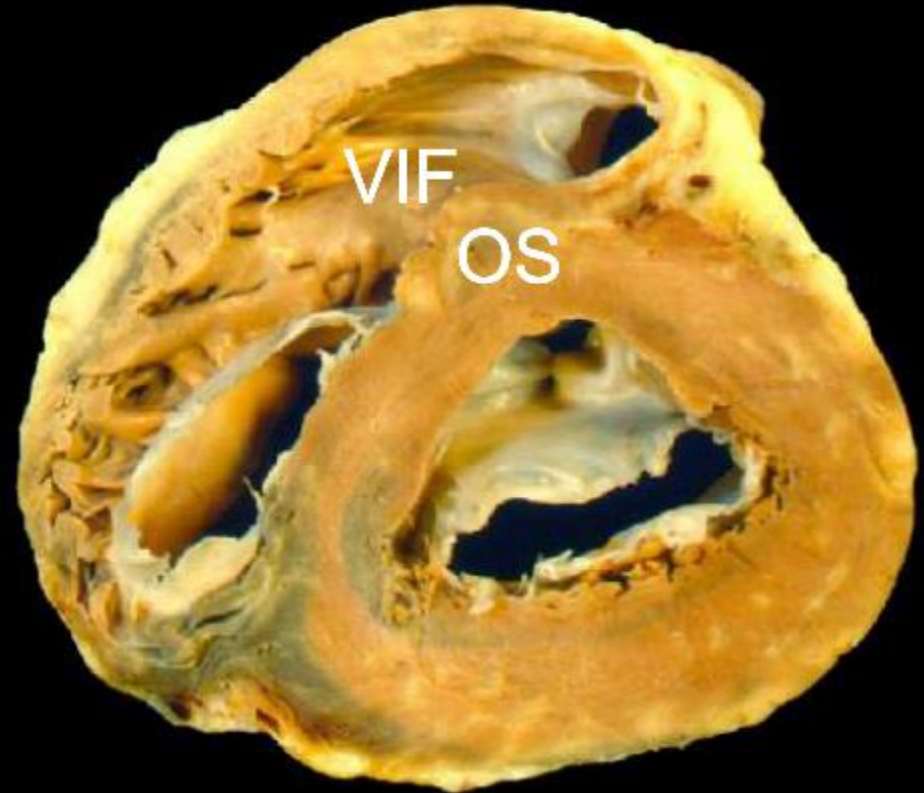
CoS

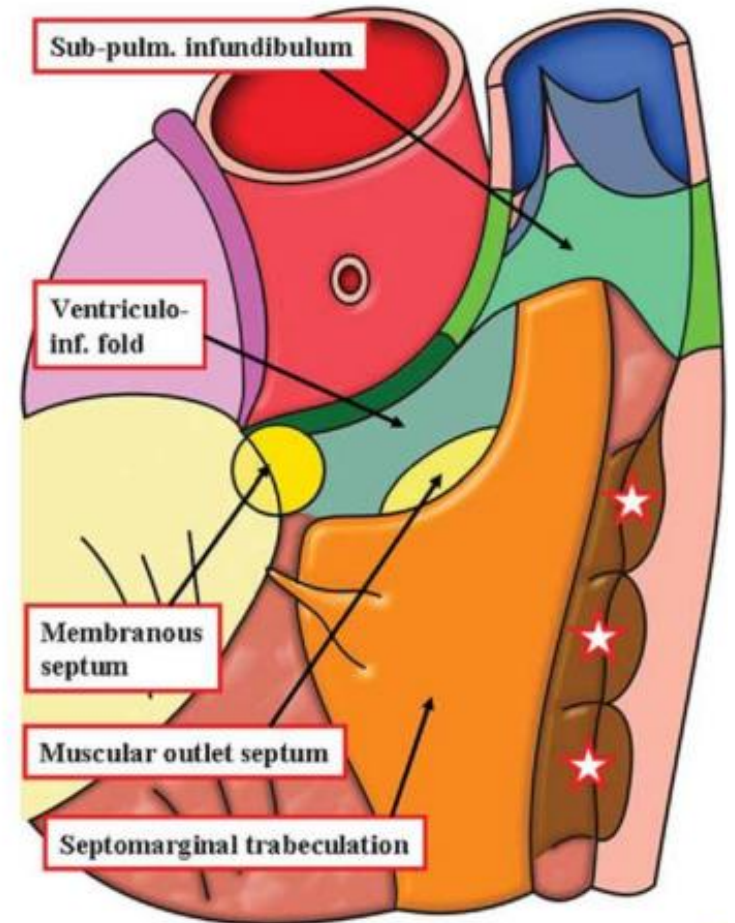
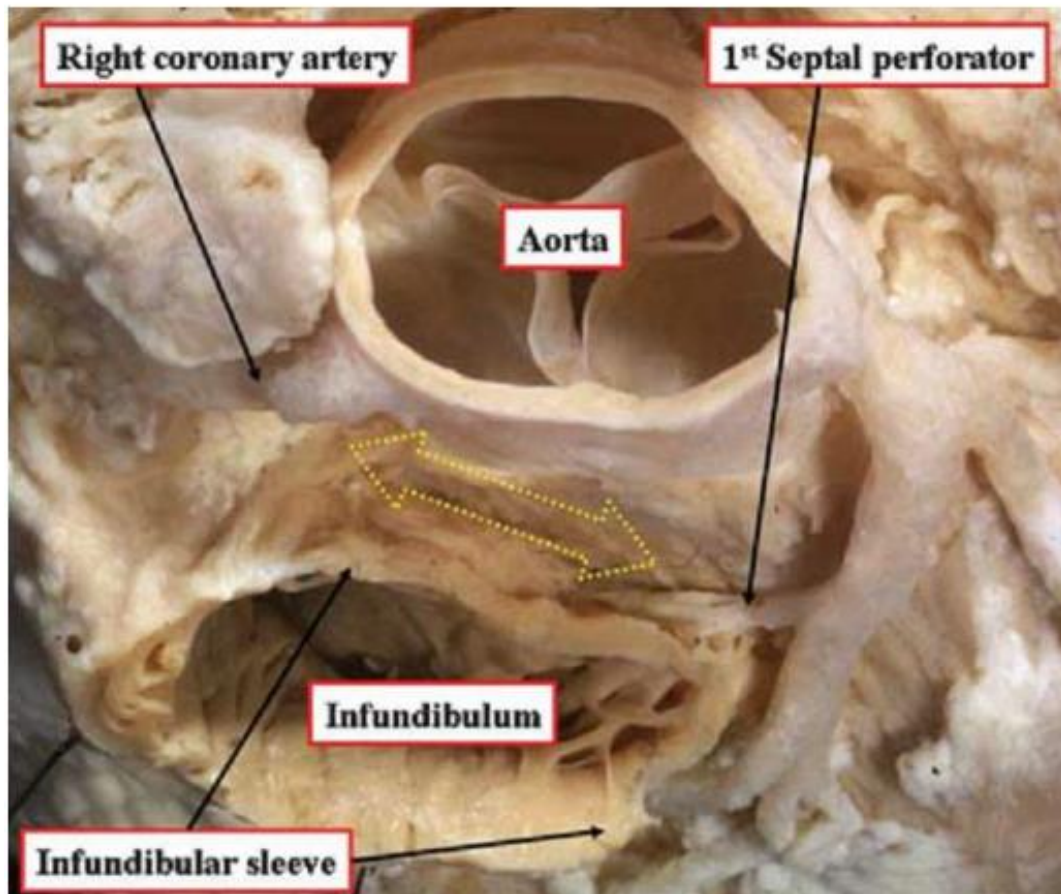
“Crista supraventricularis (Supraventricular crest)”

defined as the muscular area separating the attachments of the tricuspid and pulmonary valves in the roof of the right ventricle

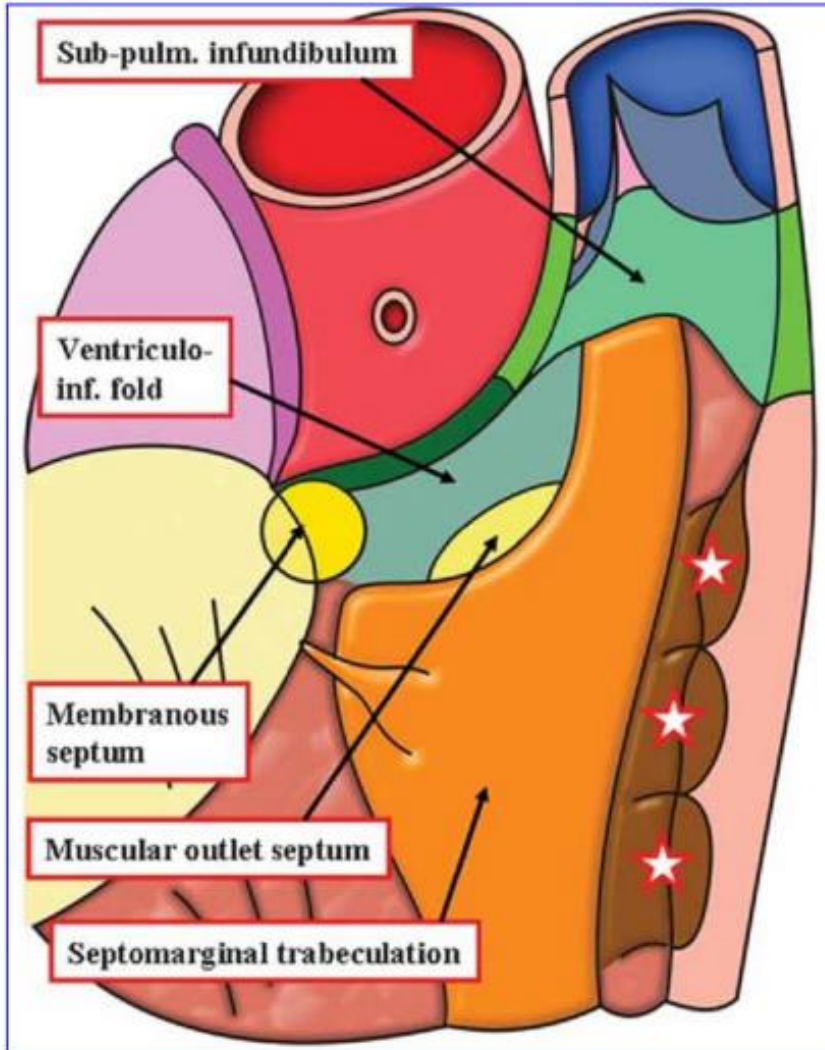


Crista supraventricularis:
ventriculoinfundibular fold (VIF) + outlet
or infundubular septum

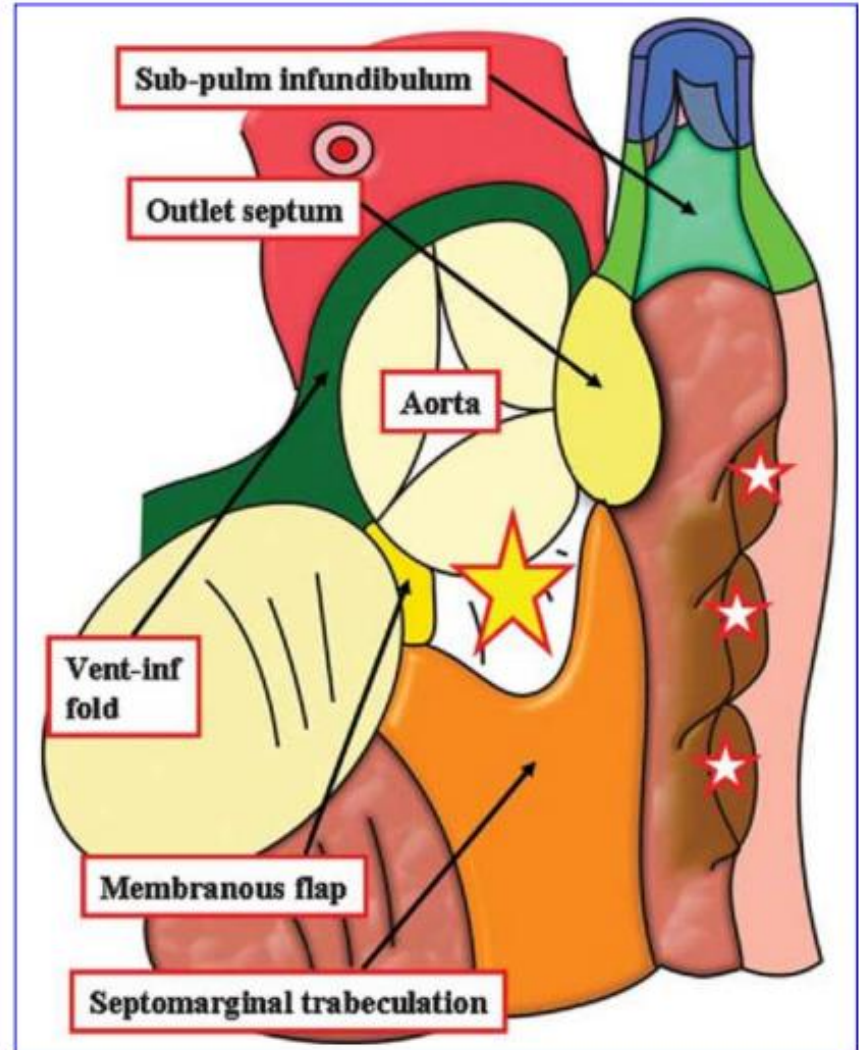


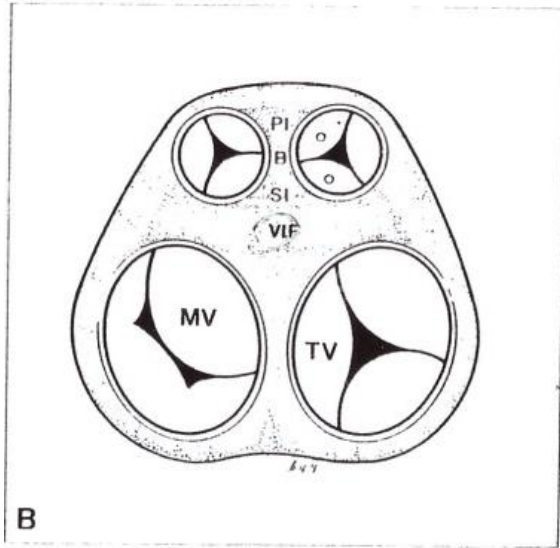


Normal



TOF





let right ventricle.

Notes

Definitions of some important anatomic structures of right ventricle (Fig. 10-9) [6-8].

Crista supraventricularis; muscular crest which separates the pulmonary and tricuspid valves in the normal right ventricle.

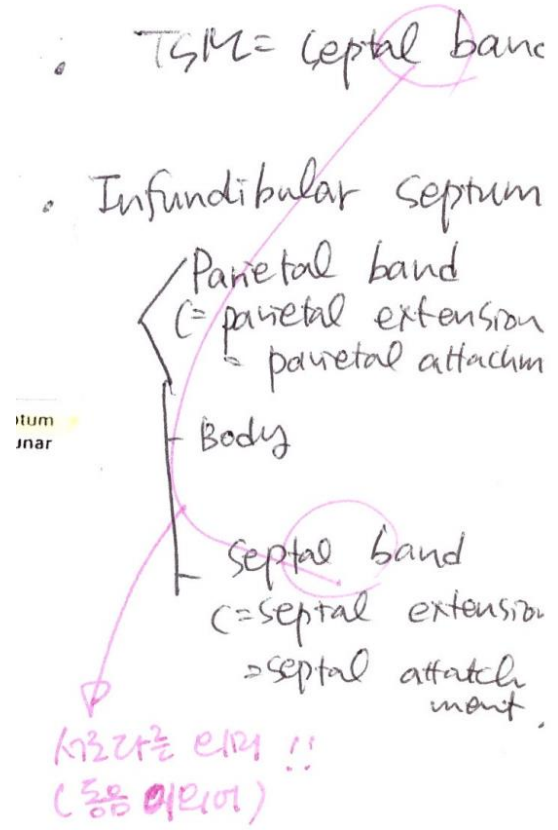
Outlet (infundibular) septum (IS); any muscular structure separating the ventricular outflow tracts and arterial valves. It has body (B) and septal (SI) and parietal (PI) insertions.

Ventriculoinfundibular fold (VIF); any muscular structure separating an arterial valve from an atrioventricular valve.

Trabecula septomarginalis (septomarginal trabecula) (TSM); extensive septal trabeculation of the morphologically right ventricle. It has a body (B) and anterior (AL) and posterior (PL) limbs.

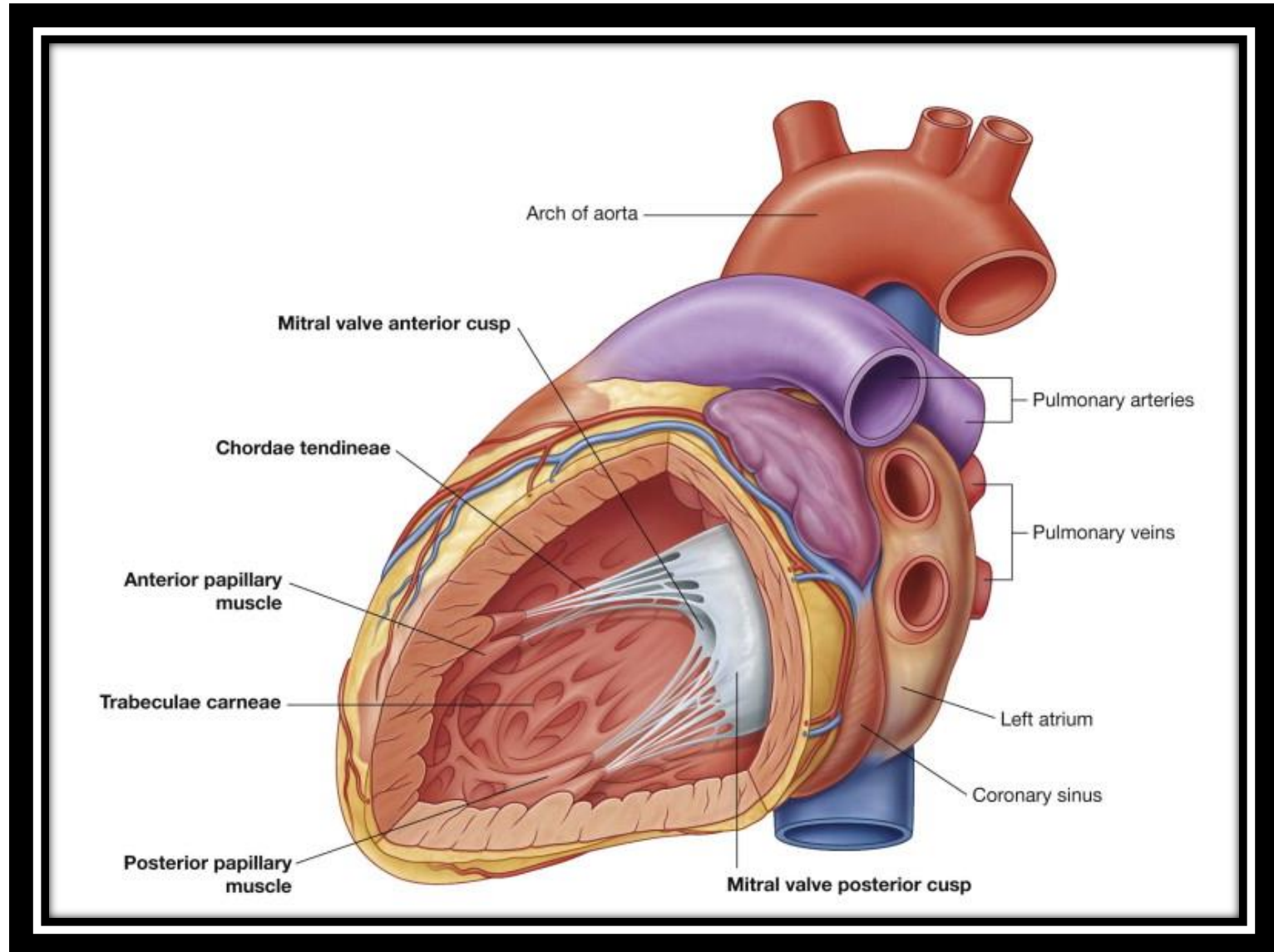
Septoparietal trabeculations (SPT); series of muscle bundles or bars in the right ventricle which extend from the septum to the parietal wall.

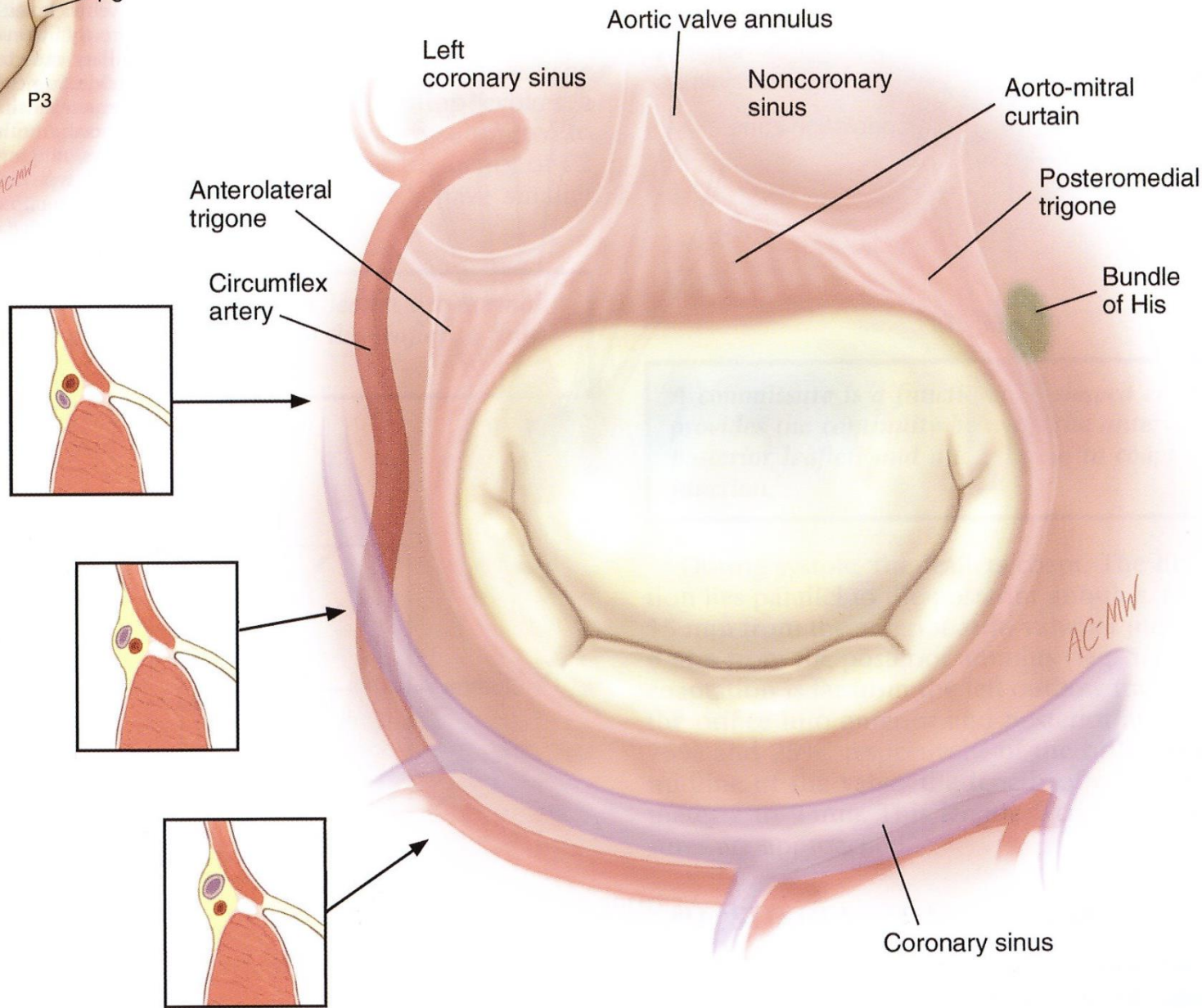
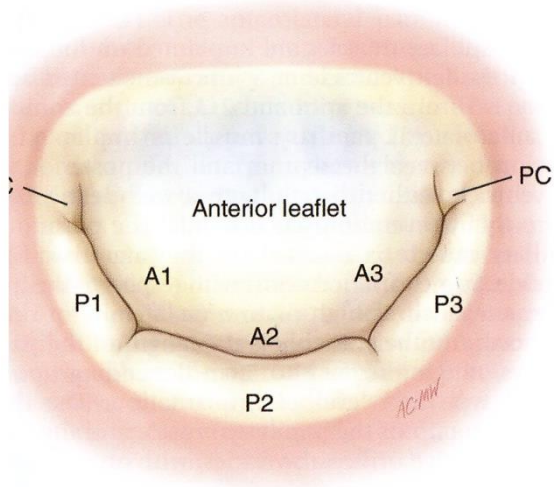
Moderator band; one of the septoparietal trabeculations which arises from the body of the trabecula septomarginalis and crosses to the ventricular free wall.

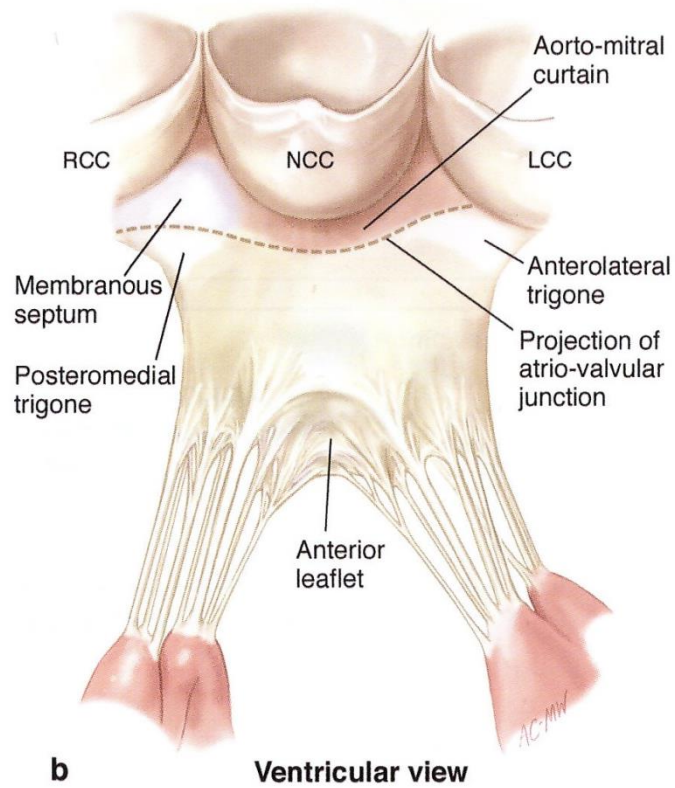
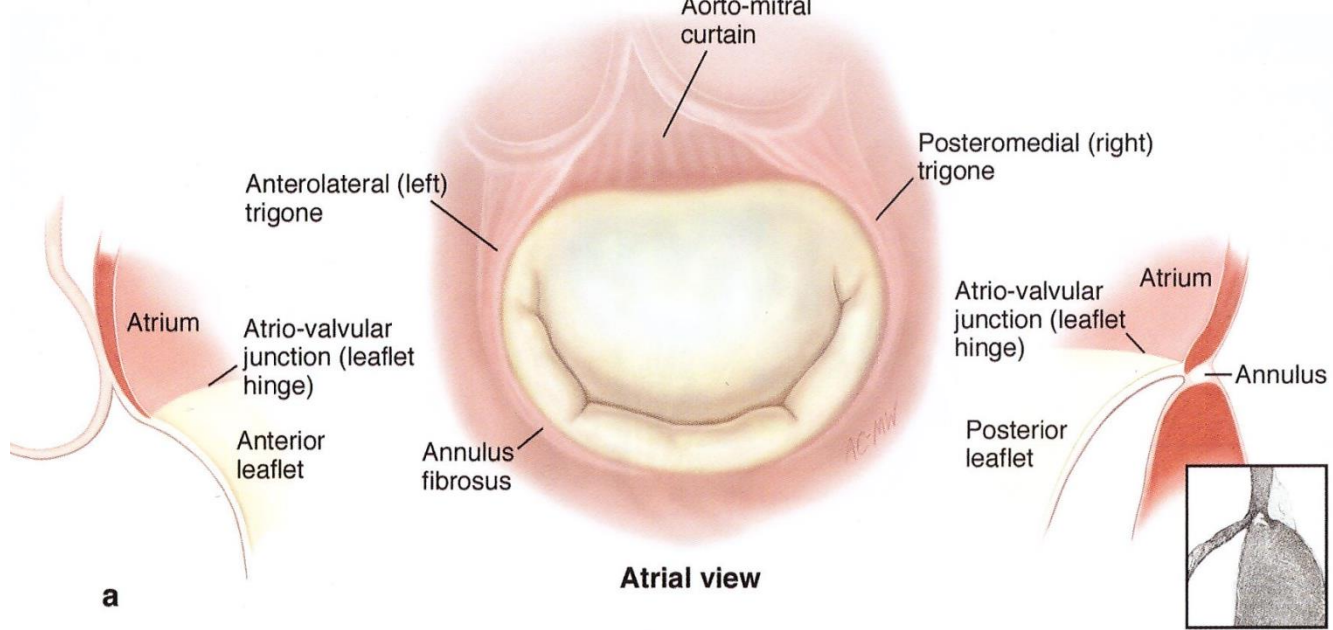


Hum
inar

Internal view of LV







References

- Kouchoukos N, Blackstone E, Hanley F, Kirklin J. Kirklin / Barratt-Boyes. Cardiac Surgery. 4th ed. Elsevier/ USA, 2013
- Carpentier's Reconstructive valve surgery From valve analysis to valve reconstruction. Saunders/USA, 2010
- H. Kurosawa, A.E. Becker, Atrioventricular conduction in congenital heart disease. Springer-Verlag/1987
- Sabiston Textbook of Surgery, 17th ed. Elsevier/2004
- Ciba collection