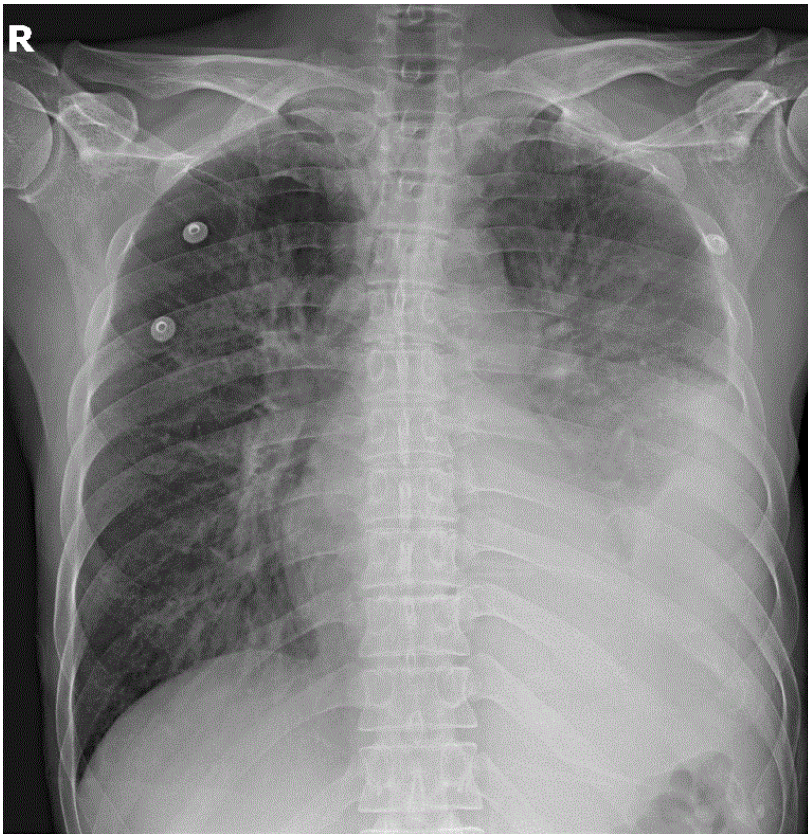


Lung Ultrasound

대한흉부심장혈관외과학회 제10차 전공의 연수교육
2017년 5월 26일(금)
대명리조트 삼척솔비치
인천한림병원
김태식

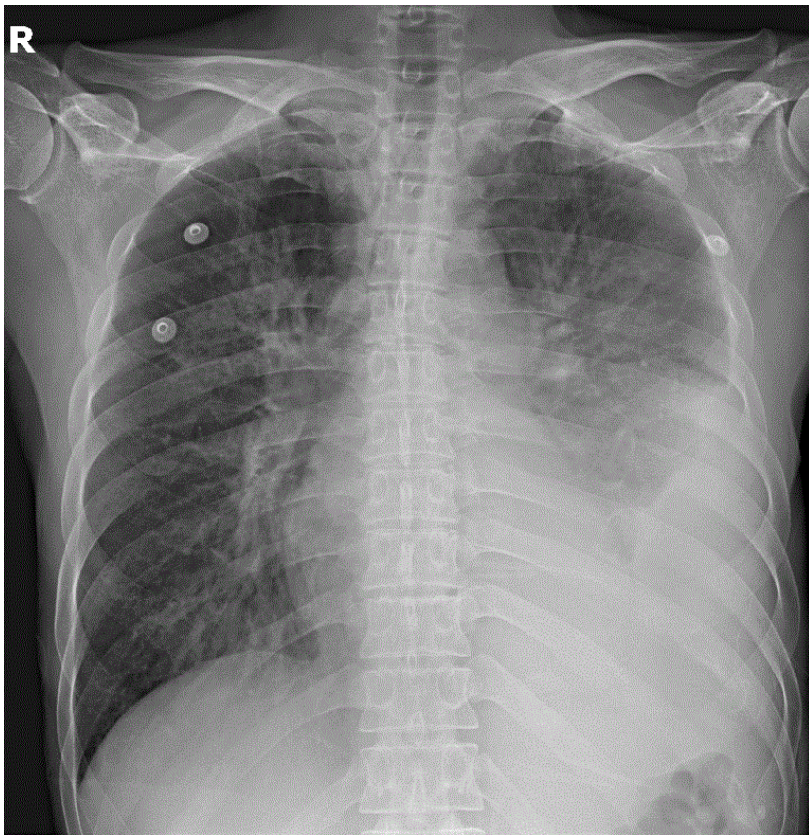
Diagnosis – How?

Lung

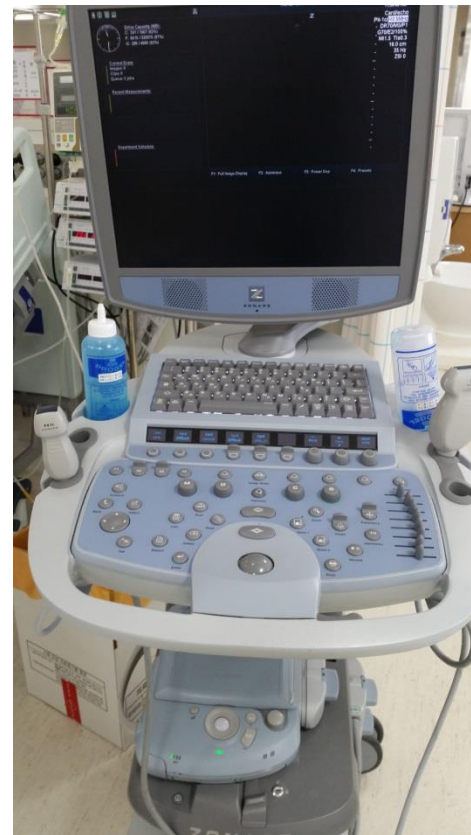

- Auscultation
- ?
-
- Chest x-ray
- CT

Lung



Ultrasound scanner



Ultrasound

- > 20 KHz
- Clinical application: 2 ~ 12 MHz
- not penetrate gas, very slowly pass
- Lung: gas-filled organ

Scanner (Device)

- ✓ Monitor
- ✓ Main body
- ✓ Probe

Ultrasound physics

- Light
- Particle
- **Sound**
 - ✓ **Wave**
 - Frequency
 - Wave length
 - Amplitude
 - ❖ Penetration
 - Reflection
 - Attenuation
 - Resolution

Mode of ultrasonography

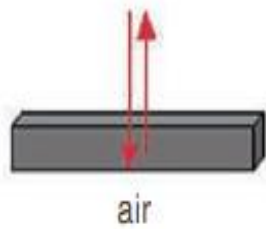
- A-mode
- B-mode
- M-mode

- Doppler mode
 - Color
 - PW(pulse wave)
 - CW(continuous wave)

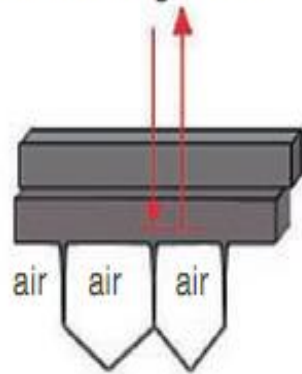
Introduction

- Convex or Linear probe
- >5 MHz
- **Simple!!!**
- Lung: gas-filled organ
- Ultrasound: not penetrate gas, very slowly pass
- **data from pleura**
- **artifacts, mostly**

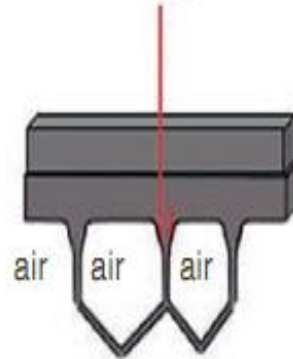
Pneumothorax



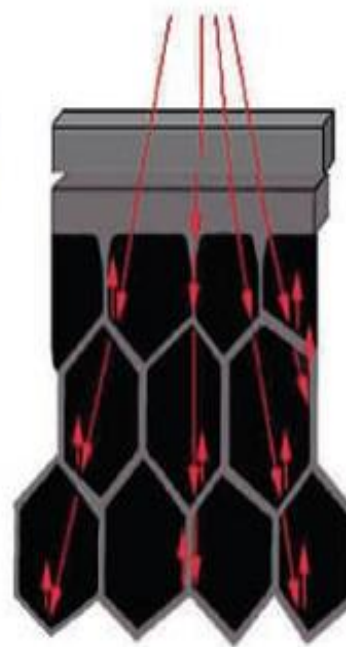
Normal lung surface



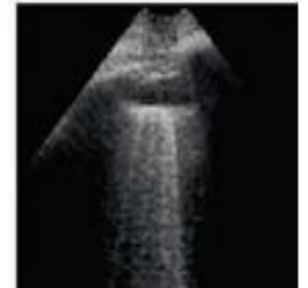
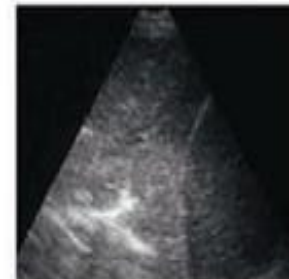
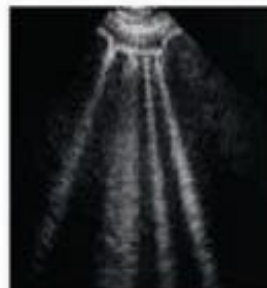
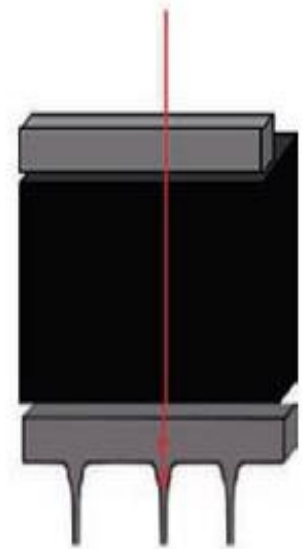
Interstitial syndrome



Alveolar consolidation



Pleural effusion



1

0,98

0,95

0,2

0

AIR/no fluid

AIR/fluid

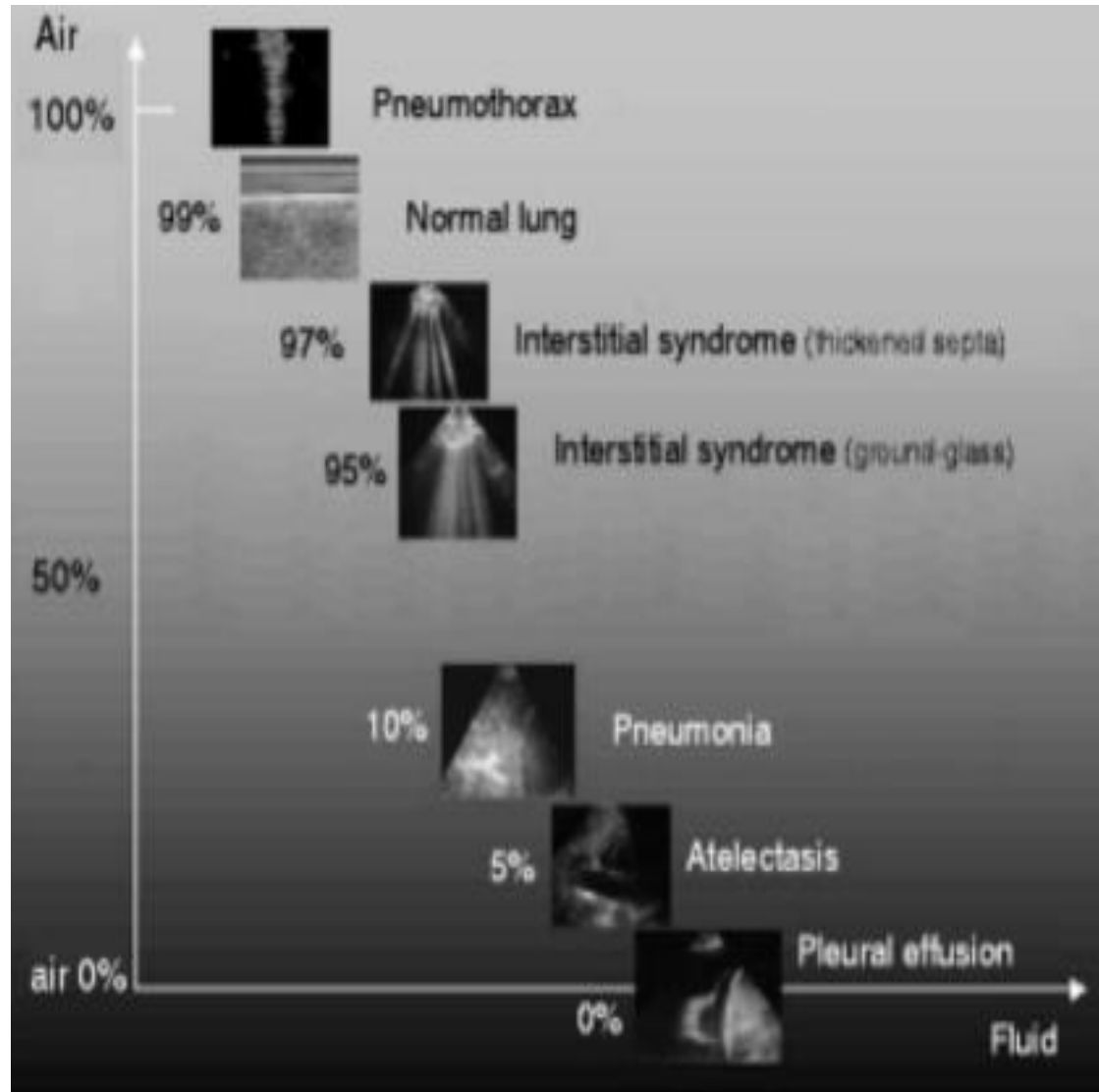
AIR/fluid

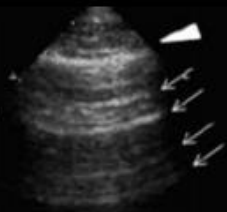
air/FLUID

no air/FLUID

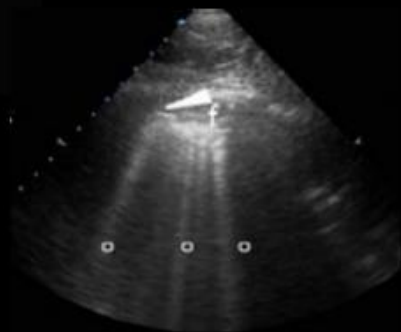
Air-fluid ratio

Air-fluid ratio and Sky-earth axis





Normal aeration

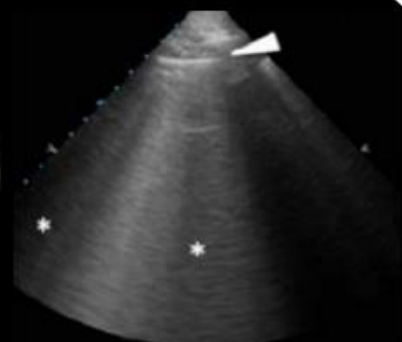


Moderate: Multiple well-spaced B

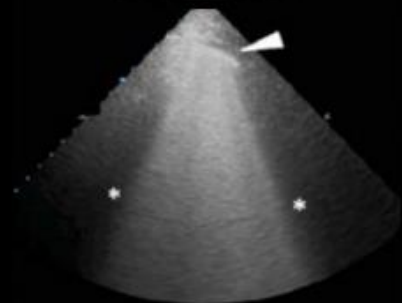
- Interstitial process (thickened ILS)
 - Regularly spaced B-lines
 - Edema/ fibrosis
- Alveolar process
 - Irregularly spaced B-lines
 - Disseminated foci of pn/ ongoing, but not complete yet, atelectasis

Aerated

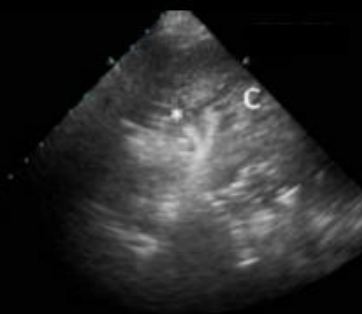
Quantitative estimation of aeration loss with LUS (whatever it's etiology)



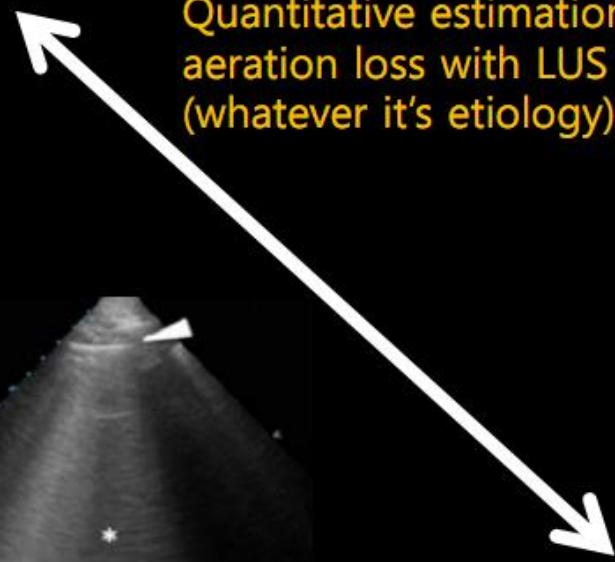Severe:
closely spaced/ coalescent B
GGO on CT



Complete:
ultrasound consolidations
Complete loss of aeration



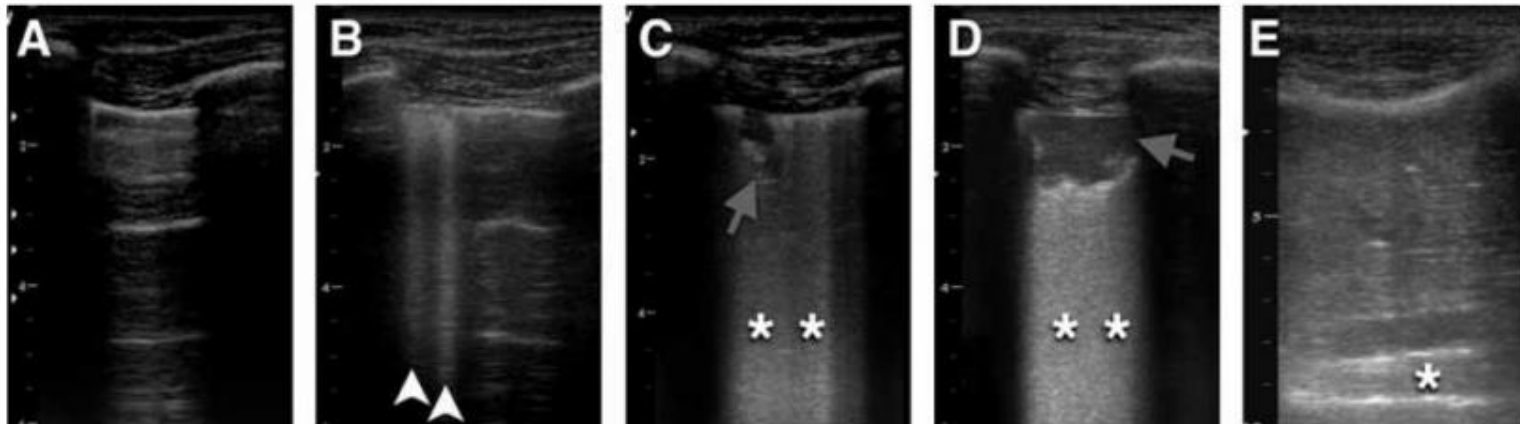
Non-aerated



Gabriele Via
Daniel Lichtenstein
Francesco Mojoli
Giuseppe Rodi
Luca Neri
Enrico Storti
Catherine Klersy
Giorgio Iotti
Antonio Braschi

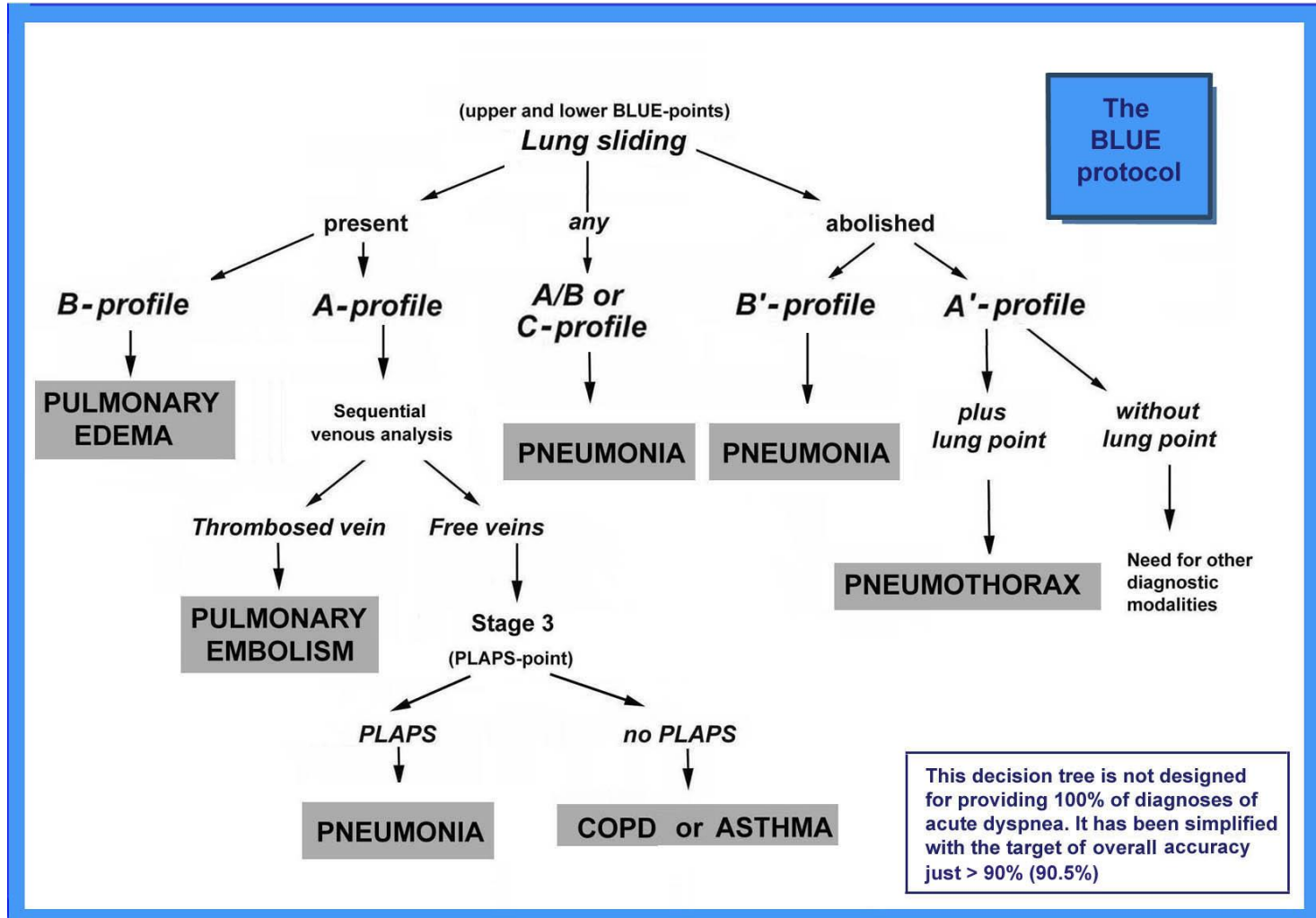
Whole lung lavage: a unique model for ultrasound assessment of lung aeration changes

A continuum corresponding to a given degree of aeration



Normal → B-lines and pleural irregularities → ↑ B-line numbers and density
→ sub-pleural consolidations → enlarged and deepened consolidations

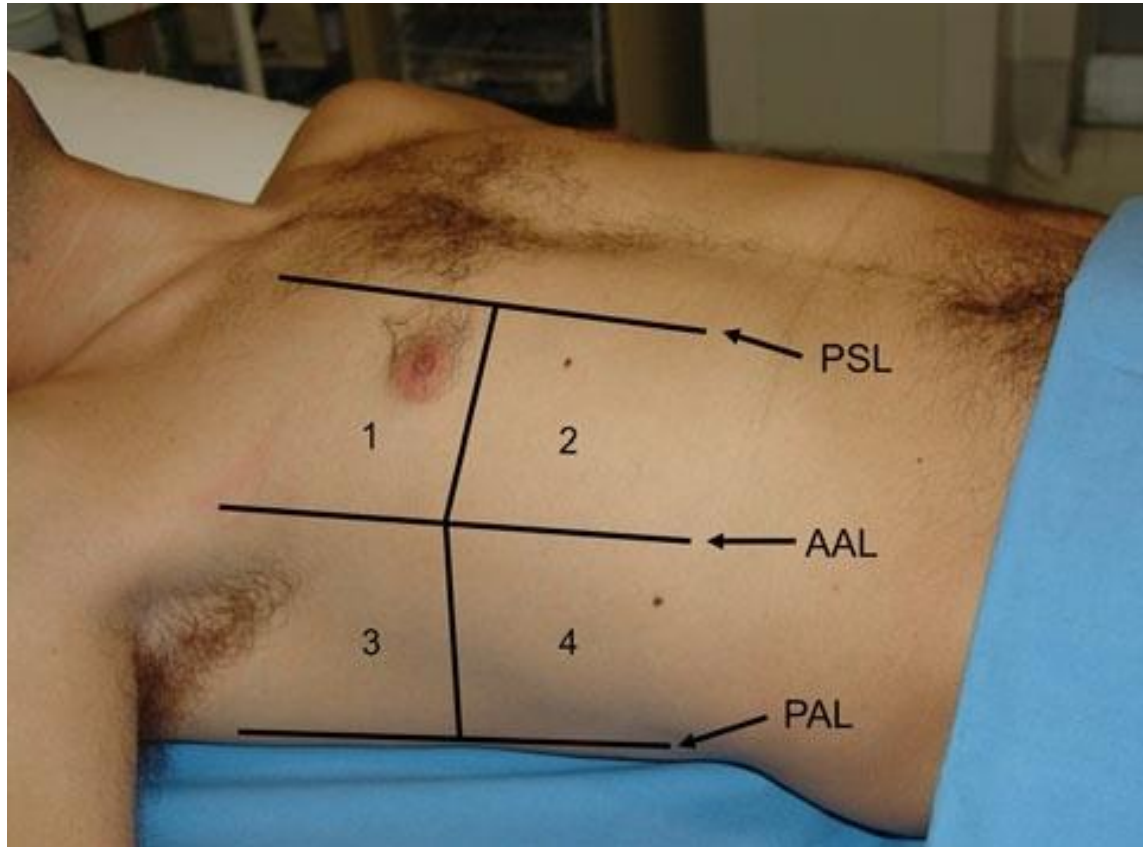
BLUE protocol



화면에서 보이는 것들: "Sign"

- Bat sign
- Lung point
- A line
- Stratosphere sign
- Lung sliding
- Quad sign
- Seashore sign
- Sinusoid sign
- B line
- Shred sign
- Lung rockets
- Tissue like sign
- Lung pulse

Zone



Sign & Pathology

- Bat sign → Lung location
- A-line → Normal lung surface
- Lung sliding
- Seashore sign

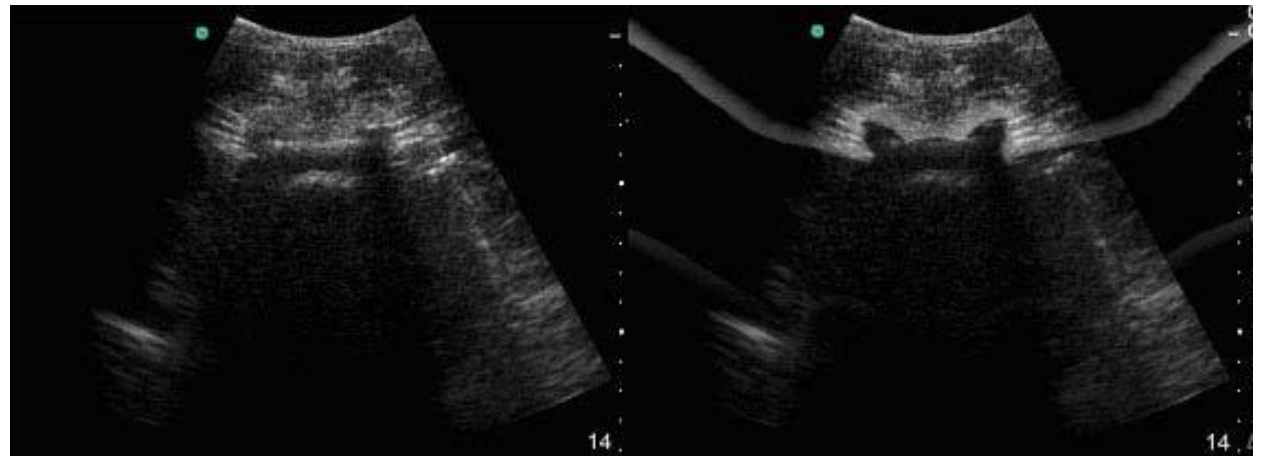
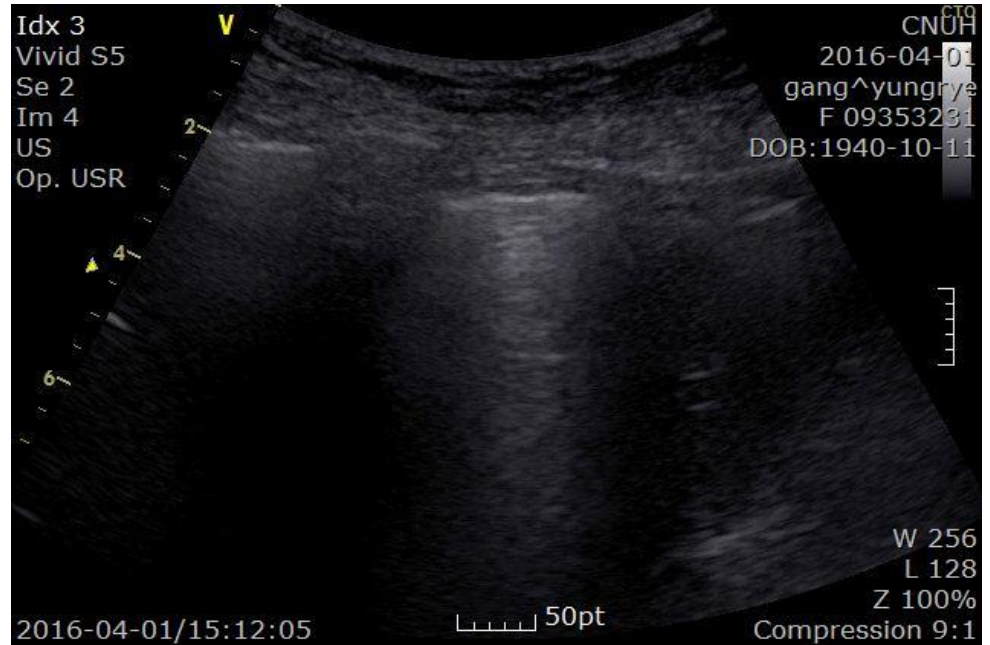
- B-line → Alveolar interstitial syndrome
- Lung rockets

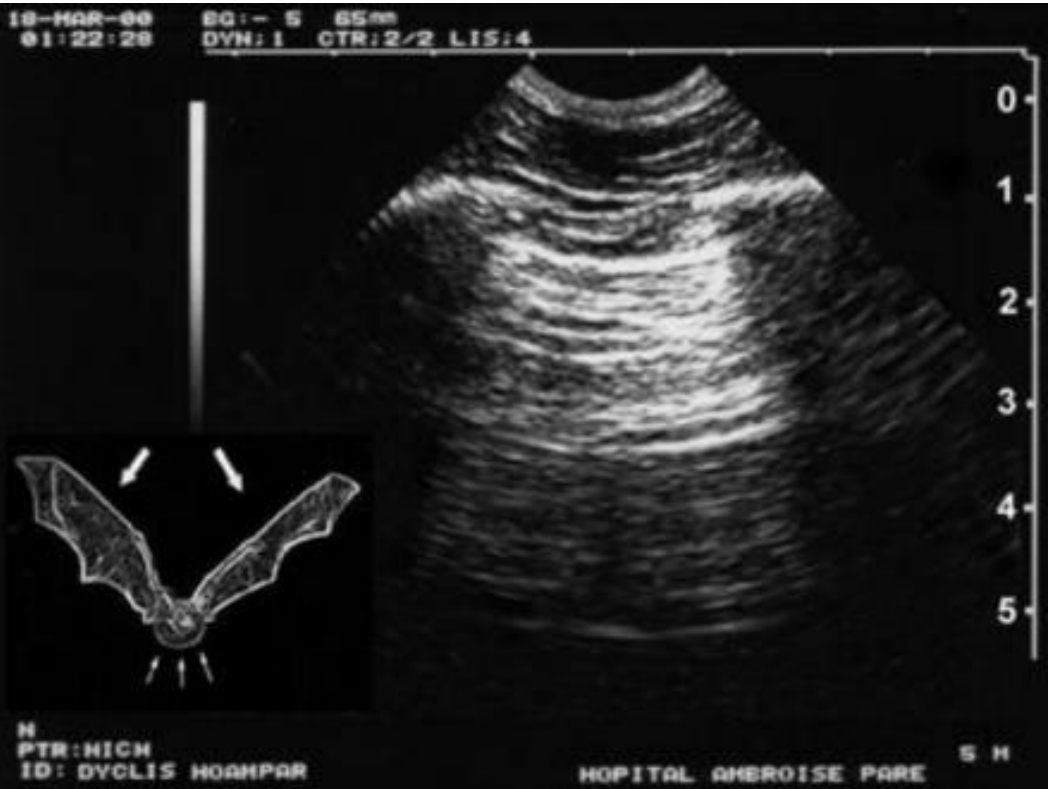Sign & Pathology

- Lung point → Pneumothorax
- Stratosphere sign
- Quad sign → Pleural effusion
- Sinusoid sign
- Shred sign → Alveolar consolidation
- Tissue like sign
- Lung pulse → Normal or Atelectasis

Bat sign

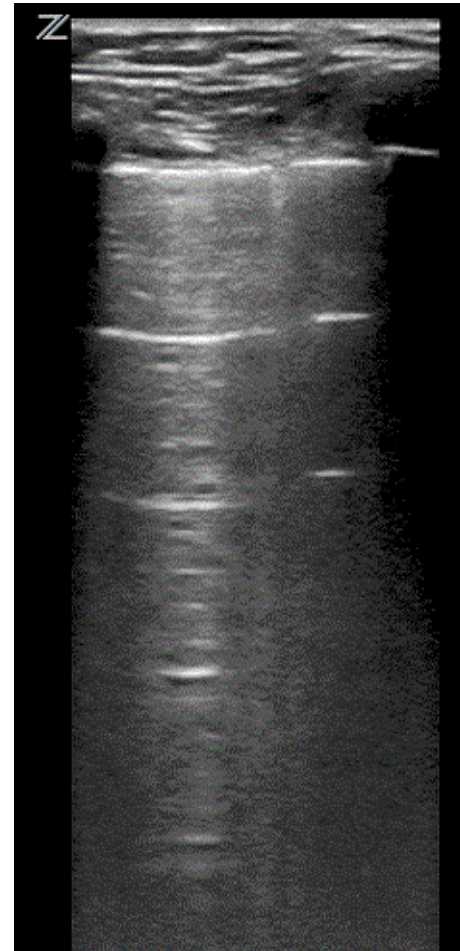
- Landmark of lung
- Rib & Pleura & Rib





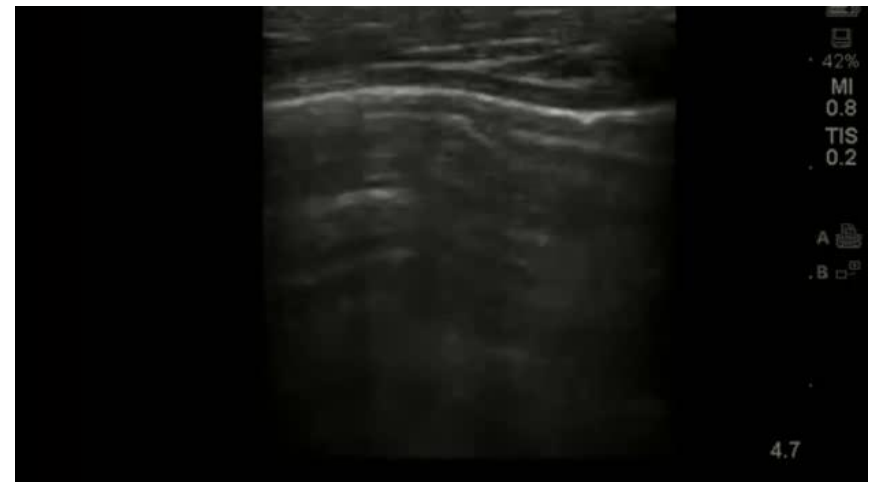
A-line

- horizontal
- regularly spaced
- hyper-echoic
- Reverberation
- Air(+)
- Normal




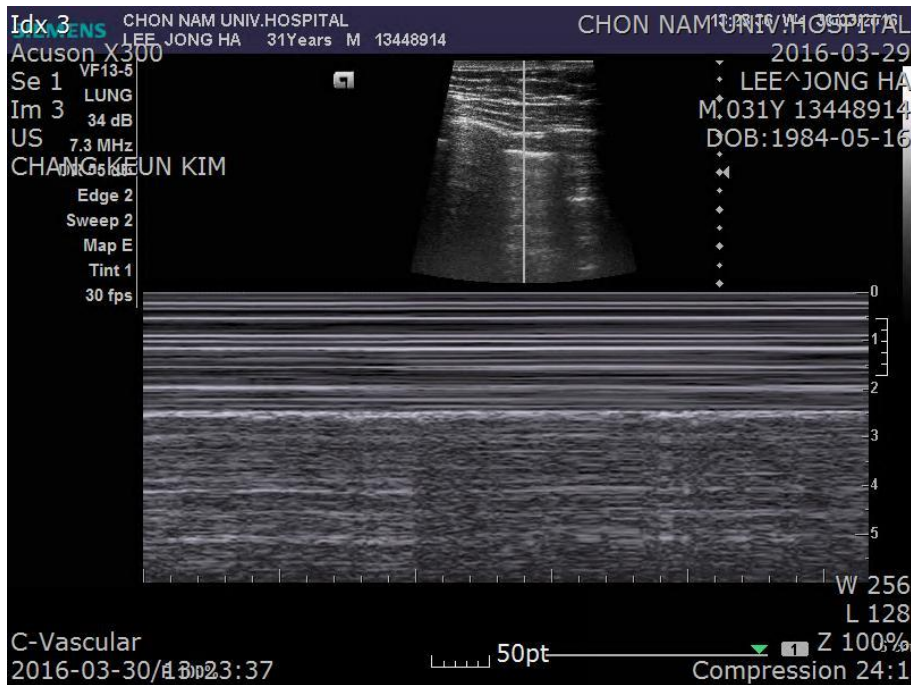
Lung sliding

- visceral pleura movement
- (-): pneumothorax, pleural adhesion, total atelectasis
- A-line + lung sliding
= A profile
- M-mode: seashore sign



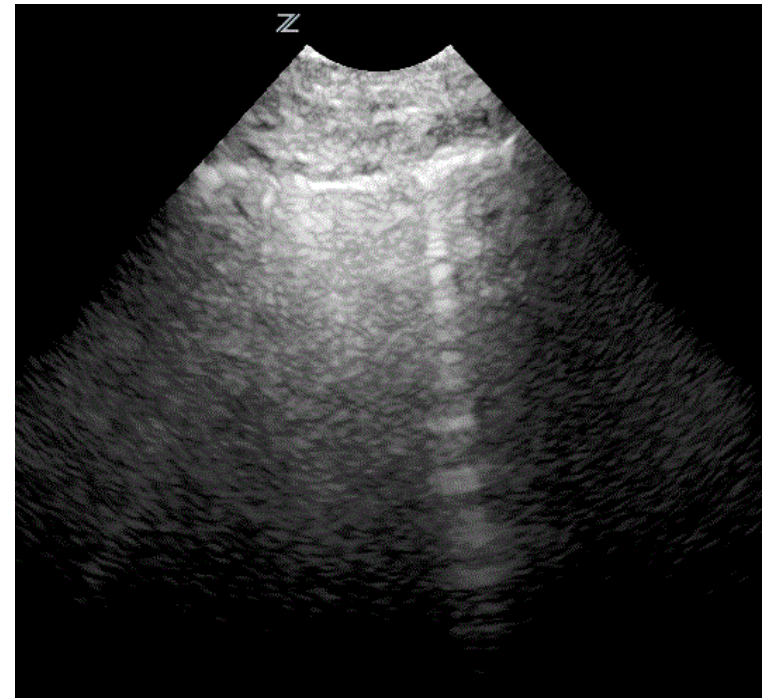
Seashore sign

- M-mode



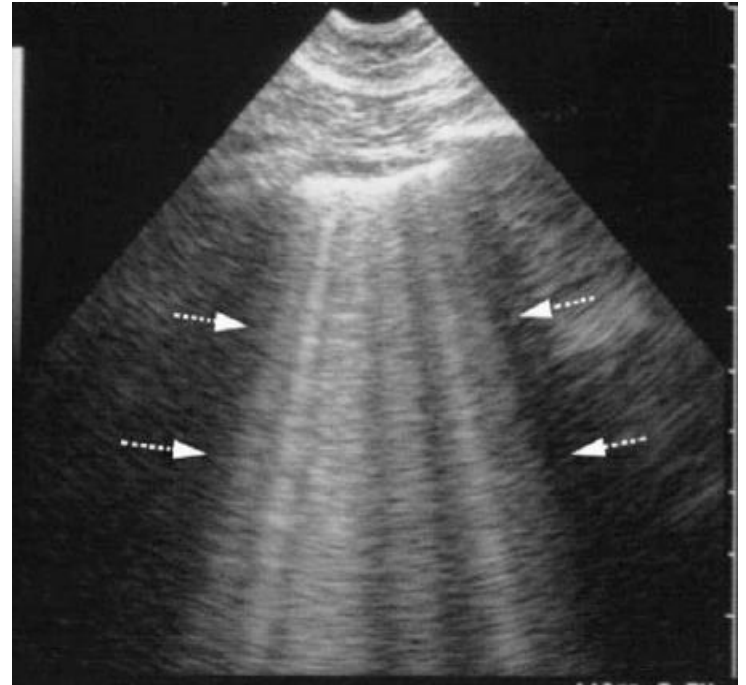
B-line

- vertical
- hyper-echoic
- to the edge of the screen
- move with respiration

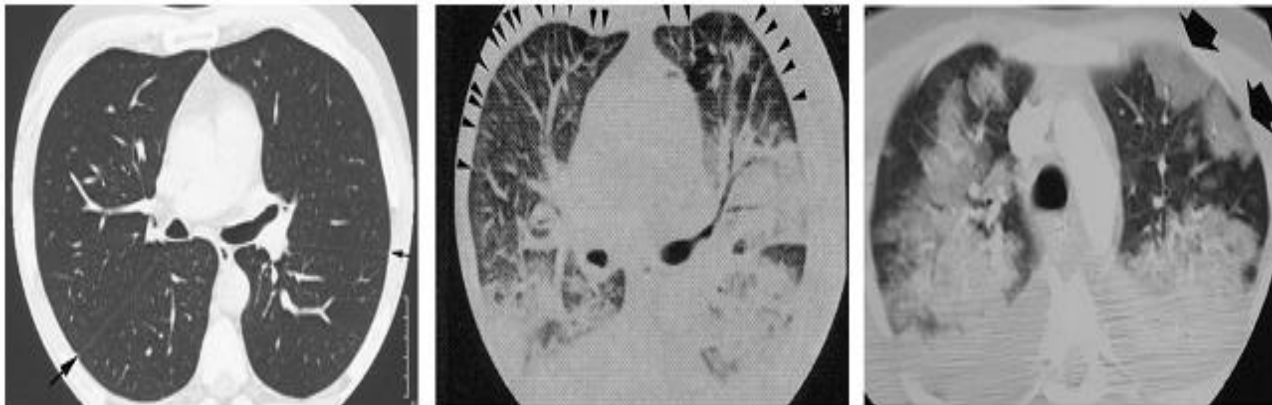
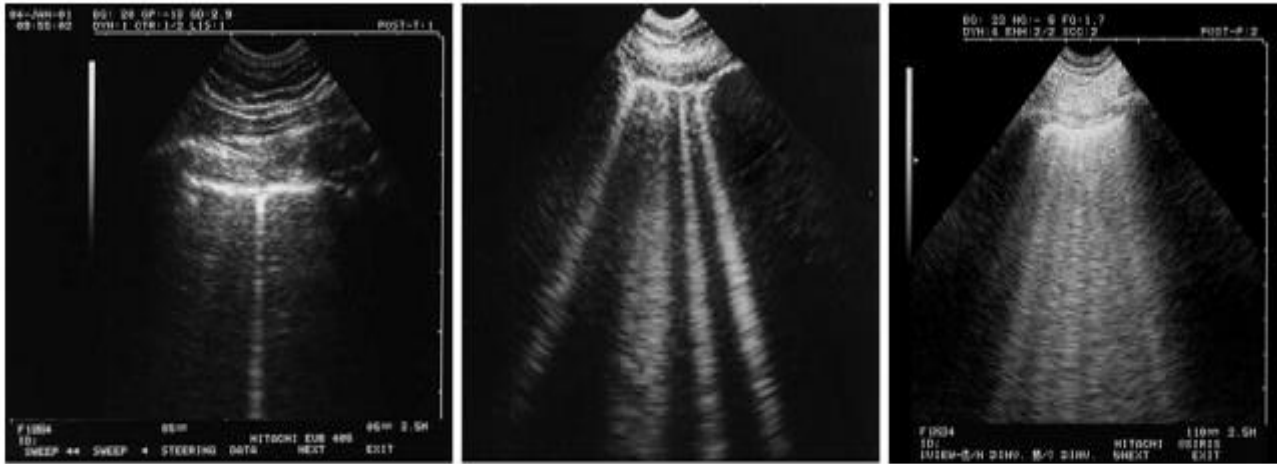


Lung rockets

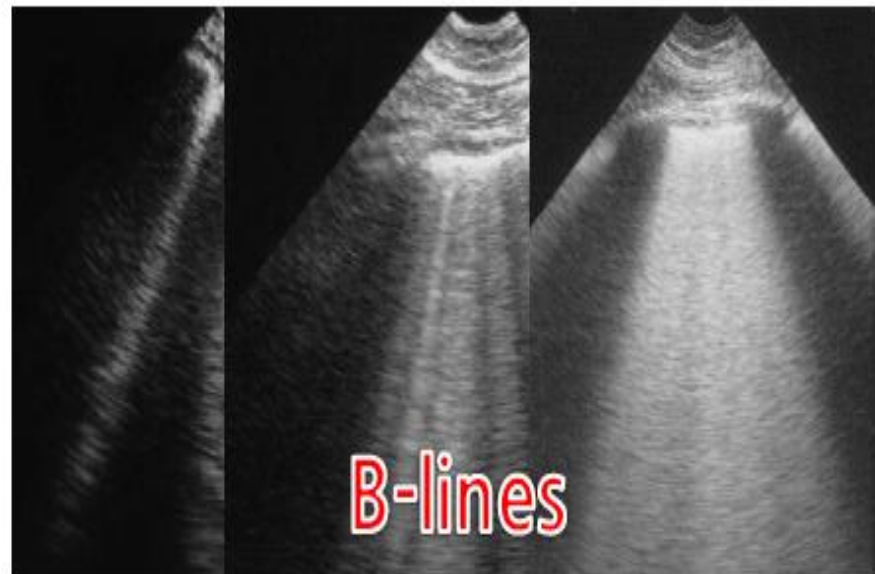
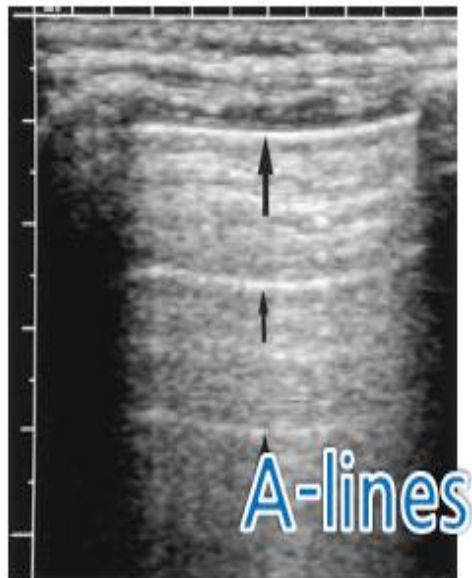
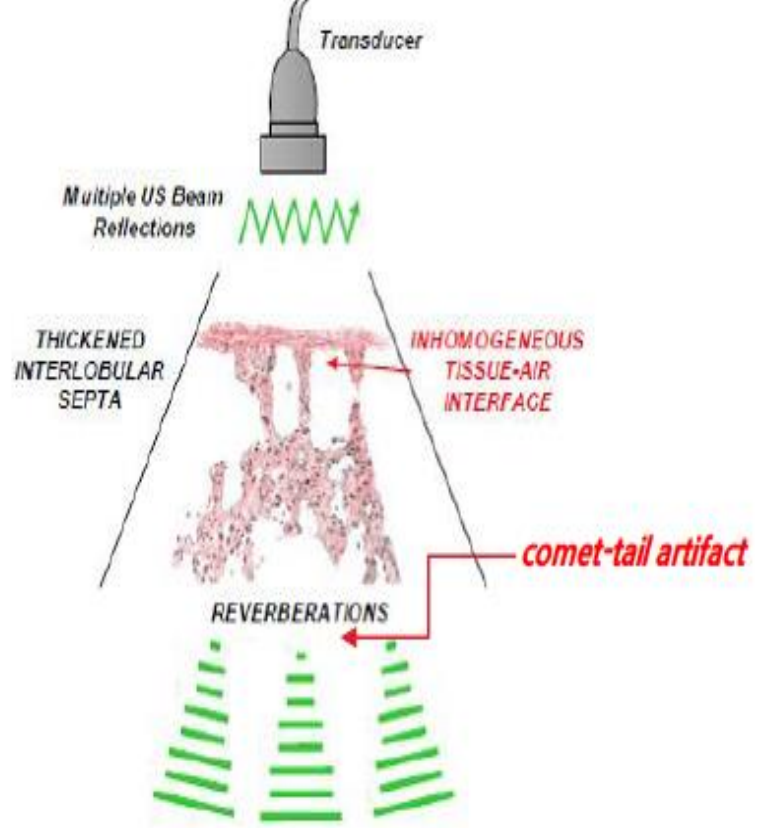
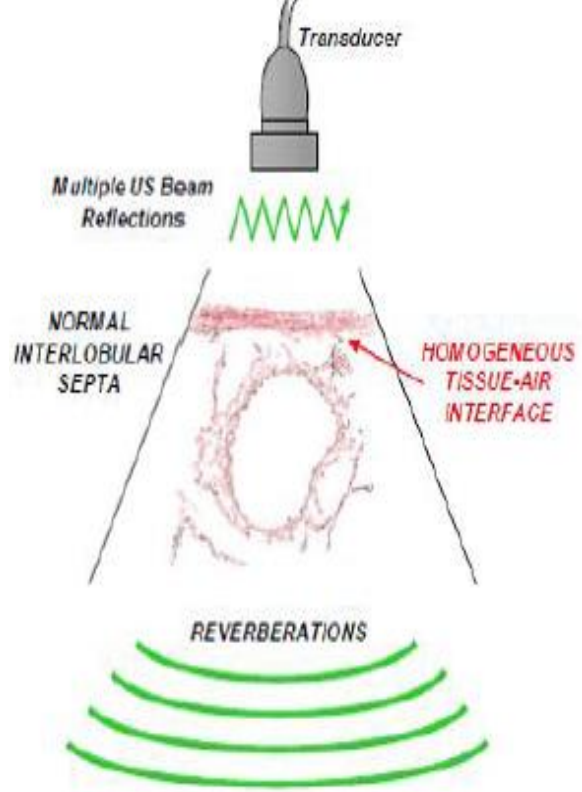
- ≥ 3 on one ICS
- Alveolar interstitial syndrome
- pathologic
- Lung rockets + lung sliding = B profile

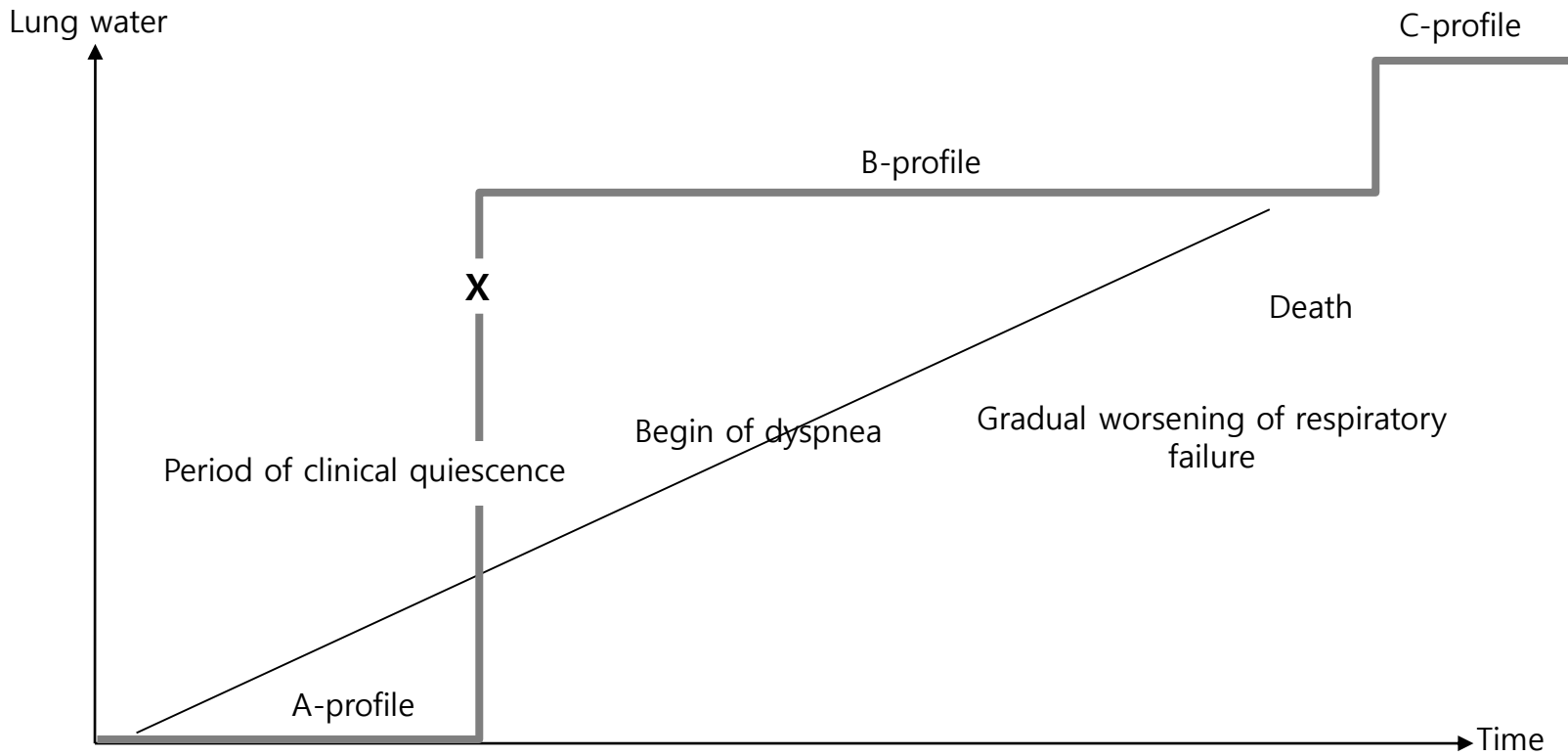


B-Lines



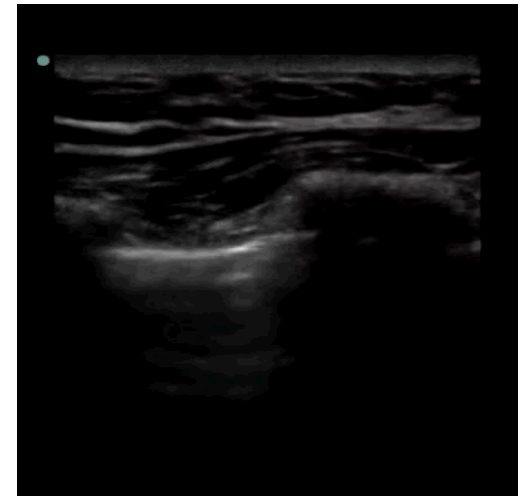
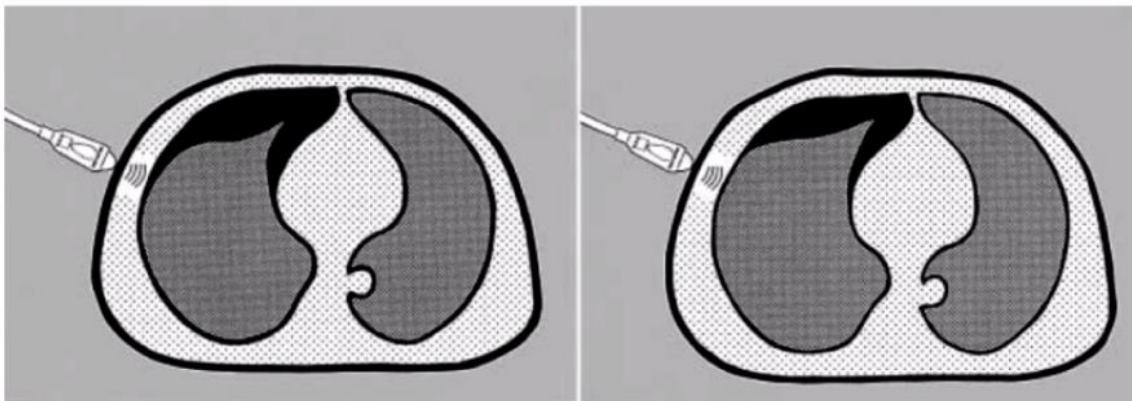
Lichtenstein D. Chest 2008;134:117-125





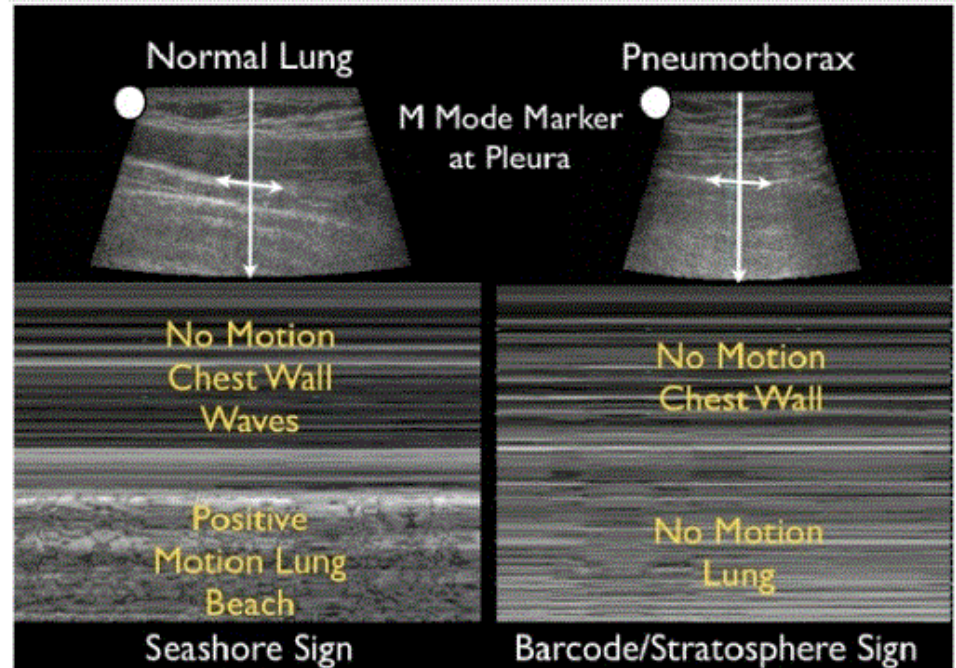
Lung point

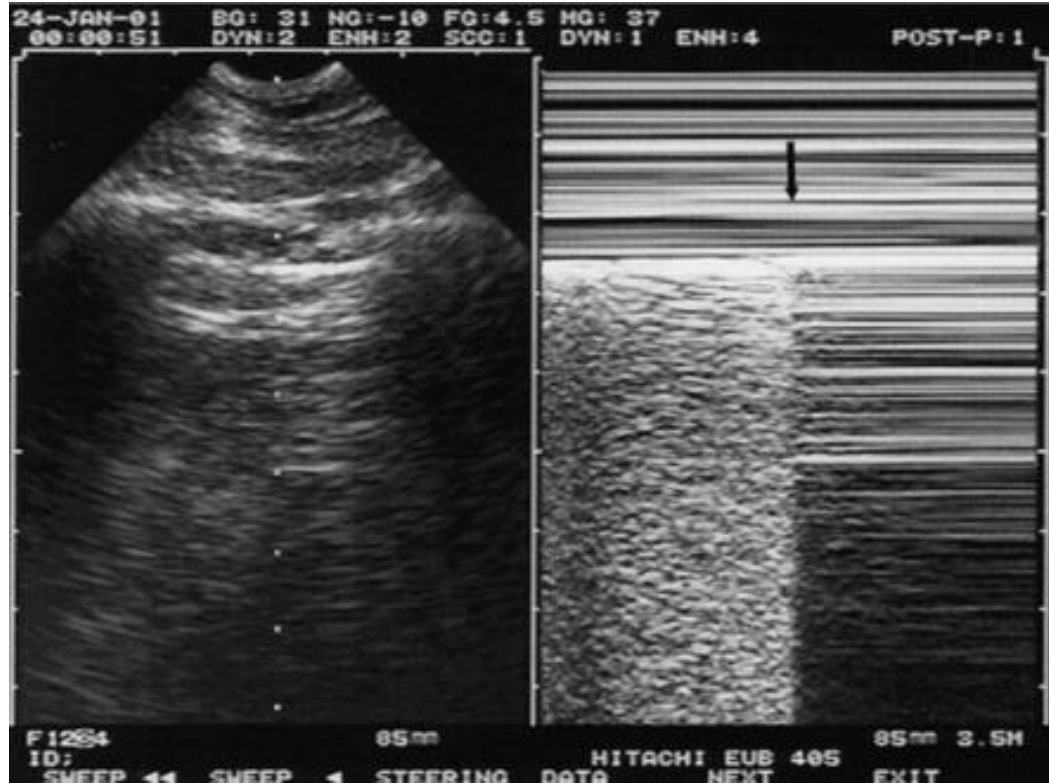- Lung sliding: preserved, and then absent
- Indicator of pneumothorax
- (-): massive pneumothorax (total collapse)



Stratosphere sign

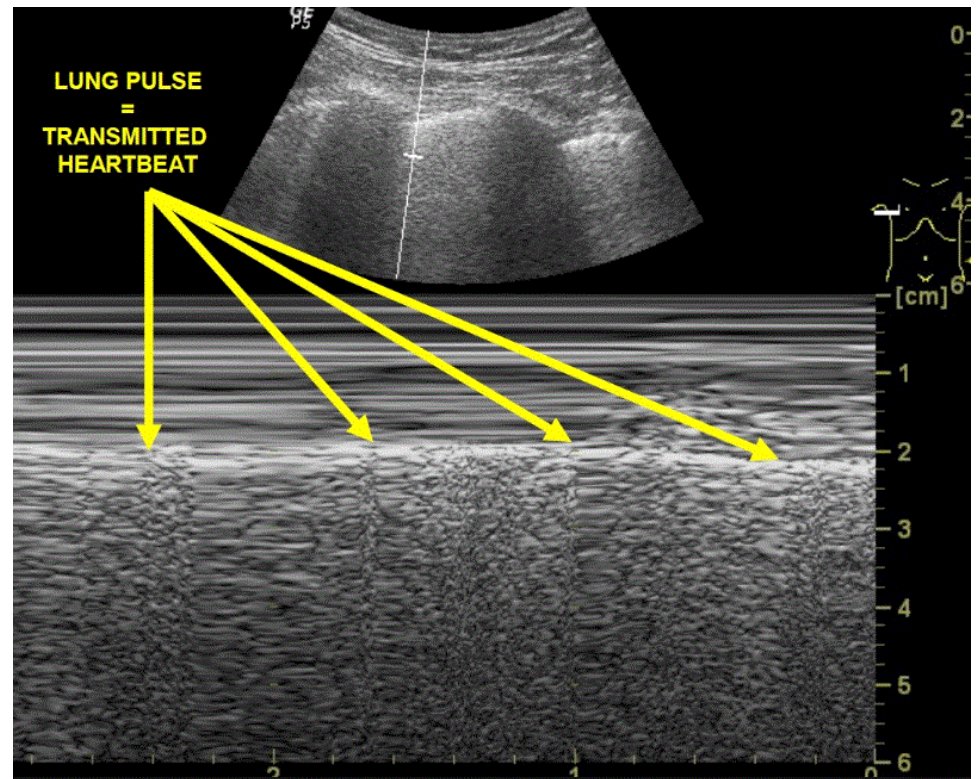
- M-mode
- Pneumothorax
- Absence of lung sliding
- Barcode sign

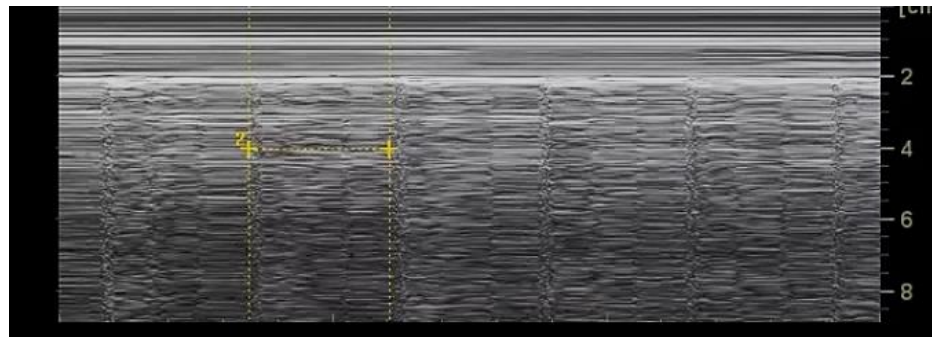
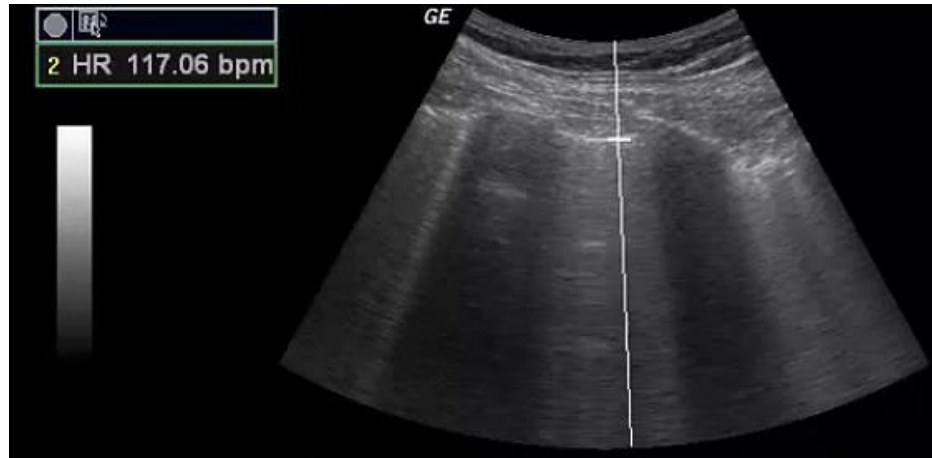




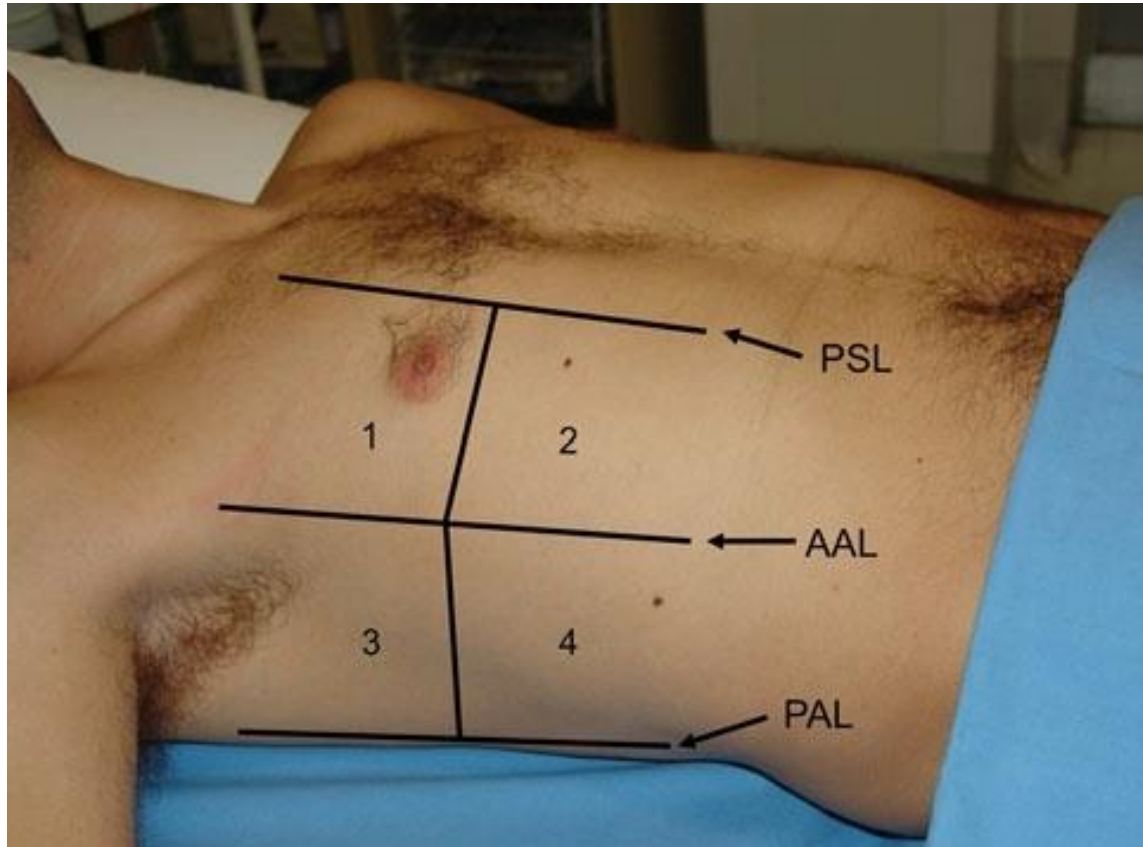
Lung pulse

- M-mode
- Heart beat
- Normal: Lt > Rt
- Atelectasis



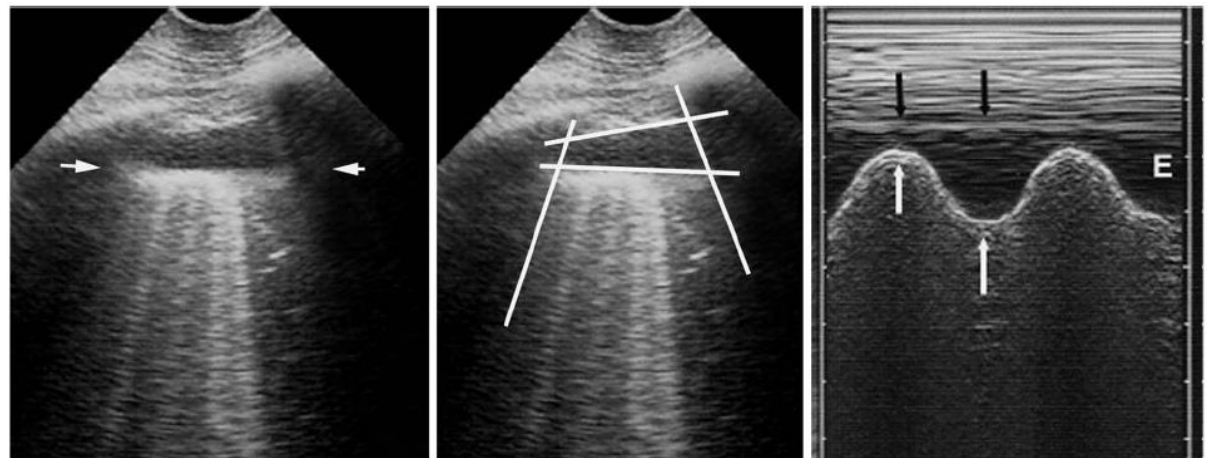


Zone



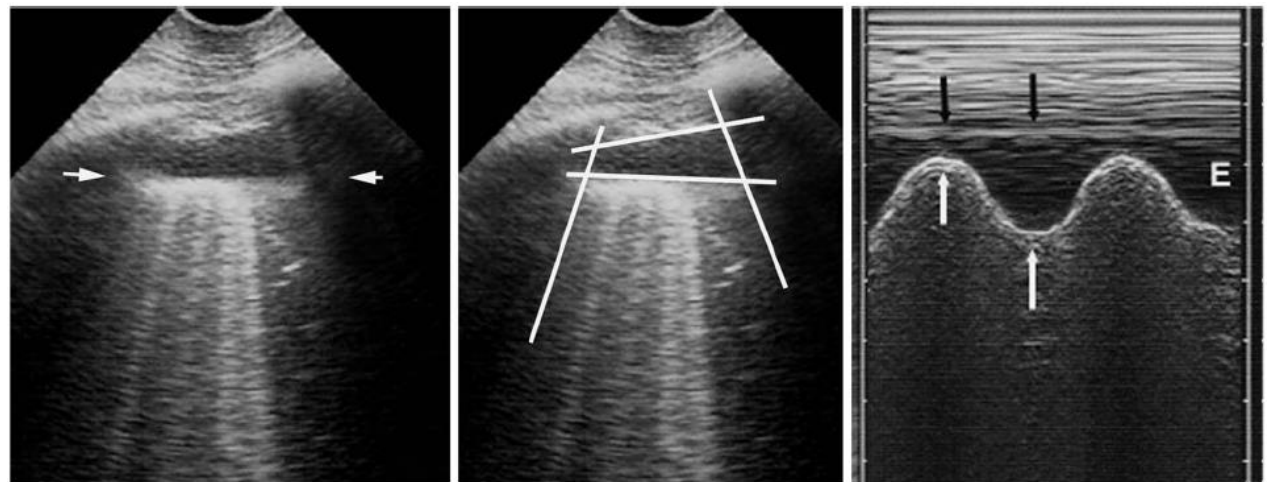
Quad sign

- PLAPS point
 - Posterior &/or Lateral, Alveolar consolidation &/or Pleural Syndrome
- dependent position
- pleural effusion, hemothorax
- visceral pleural, parietal pleura, 2 ribs



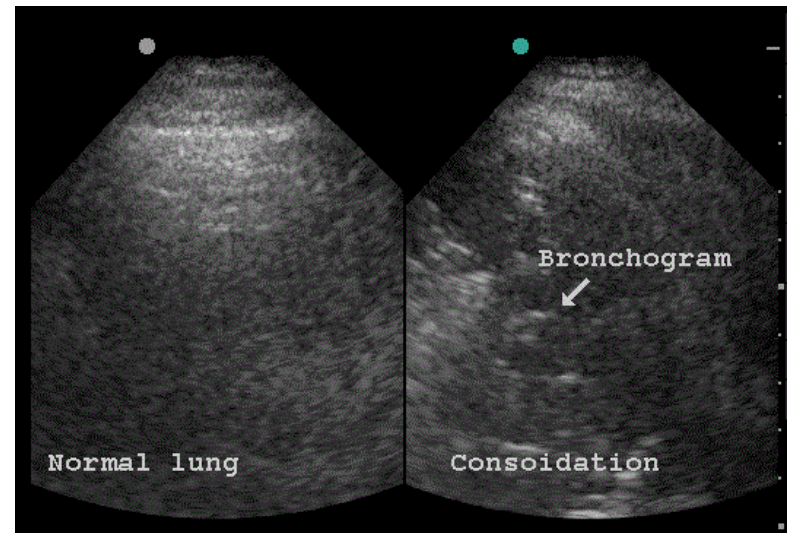
Sinusoid sign

- M-mode
- sine curve
- Movement of visceral pleura(lung) by respiration



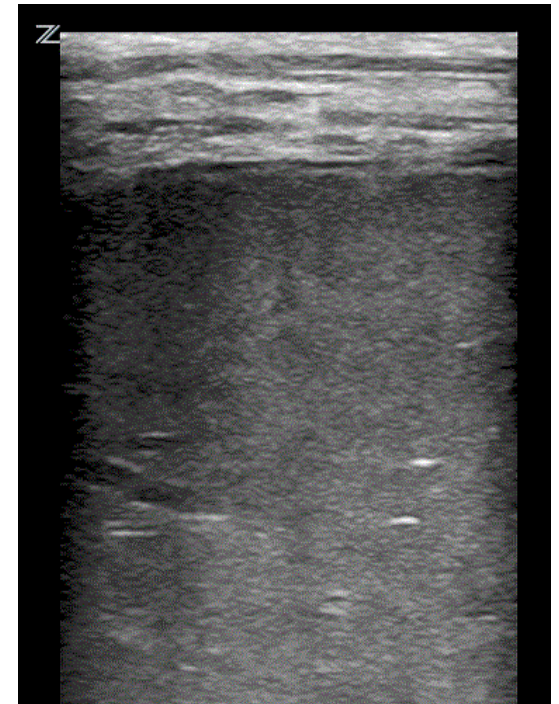
Shred sign

- alveolar consolidation: water rich
- Mixed pattern: aerated lung & alveolar consolidation



Tissue like sign

- translobar consolidation
- Hepatization: looking like the liver



Normal? Pathologic?

- Bat sign
- A line
- Lung sliding
- Seashore sign
- B line
- Lung rockets
- Lung point
- Stratosphere sign
- Quad sign
- Sinusoid sign
- Shred sign
- Tissue like sign
- Lung pulse

Normal? Pathologic?

- Bat sign
- A line
- Lung sliding
- Seashore sign
- B line
- Lung rockets
- Lung point
- Stratosphere sign
- Quad sign
- Sinusoid sign
- Shred sign
- Tissue like sign
- Lung pulse

B-mode? M-mode?

- Bat sign
- A line
- Lung sliding
- Seashore sign
- B line
- Lung rockets
- Lung point
- Stratosphere sign
- Quad sign
- Sinusoid sign
- Shred sign
- Tissue like sign
- Lung pulse

B-mode? M-mode?

- Bat sign
- A line
- Lung sliding
- **Seashore sign**
- B line
- Lung rockets
- Lung point
- **Stratosphere sign**
- Quad sign
- **Sinusoid sign**
- Shred sign
- Tissue like sign
- **Lung pulse**

Static? Dynamic?

- Bat sign
- A line
- Lung sliding
- Seashore sign
- B line
- Lung rockets
- Lung point
- Stratosphere sign
- Quad sign
- Sinusoid sign
- Shred sign
- Tissue like sign
- Lung pulse

Static? Dynamic?

- Bat sign
- A line
- **Lung sliding**
- Seashore sign
- **B line**
- **Lung rockets**
- **Lung point**
- Stratosphere sign
- Quad sign
- **Sinusoid sign**
- Shred sign
- Tissue like sign
- **Lung pulse**

in the Hands-on session...

- Bat sign
- A line
- Lung sliding
- Seashore sign
- B line
- Lung rockets
- Lung point
- Stratosphere sign
- Quad sign
- Sinusoid sign
- Shred sign
- Tissue like sign
- Lung pulse