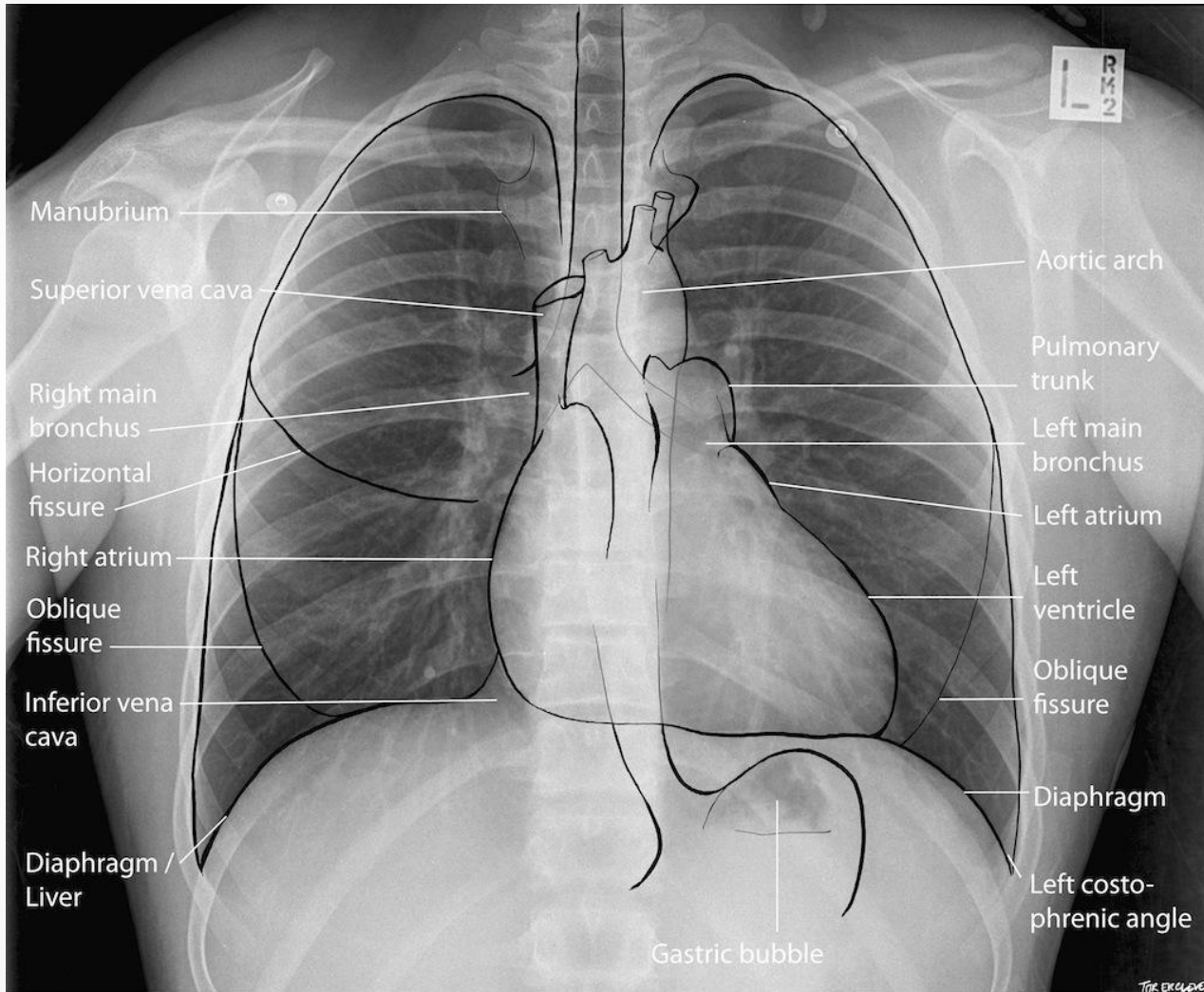


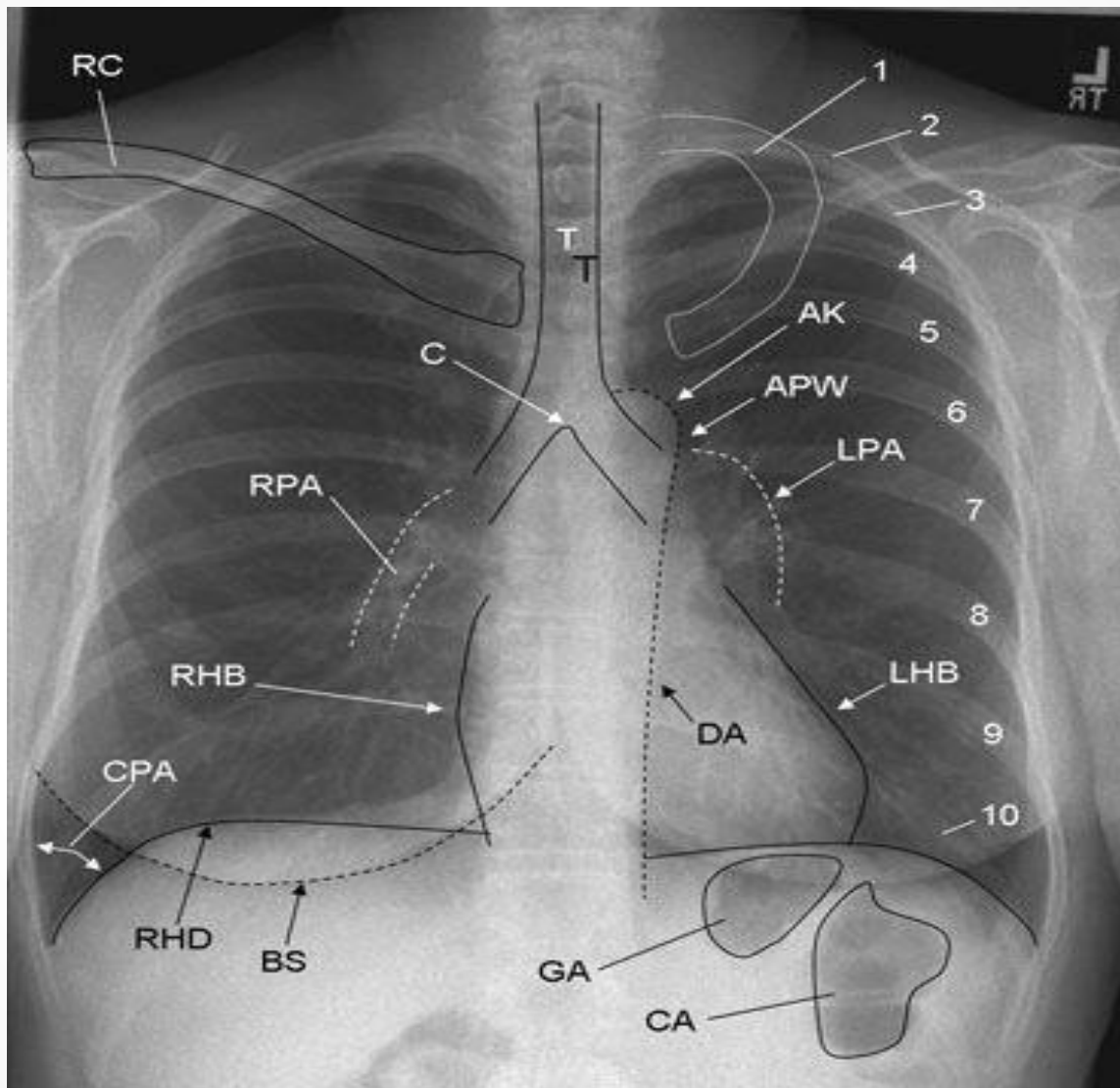
1년차가 알아야 할 흉부영상

이성수

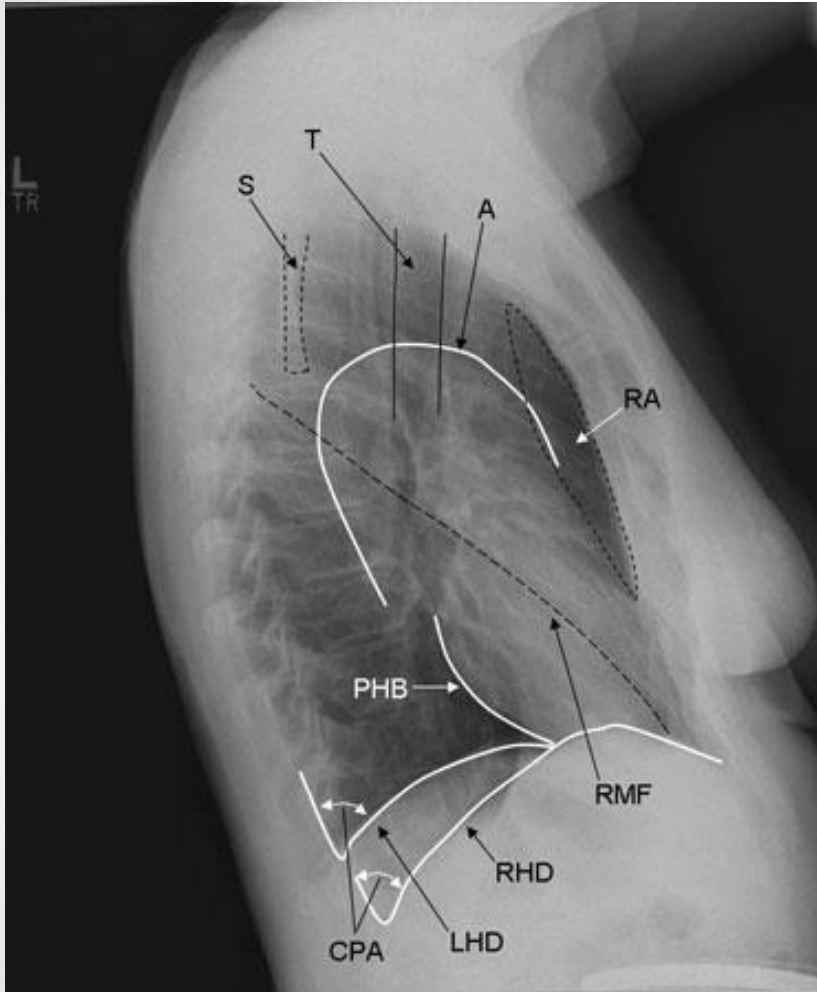
연세대학교 강남세브란스병원

흉부외과

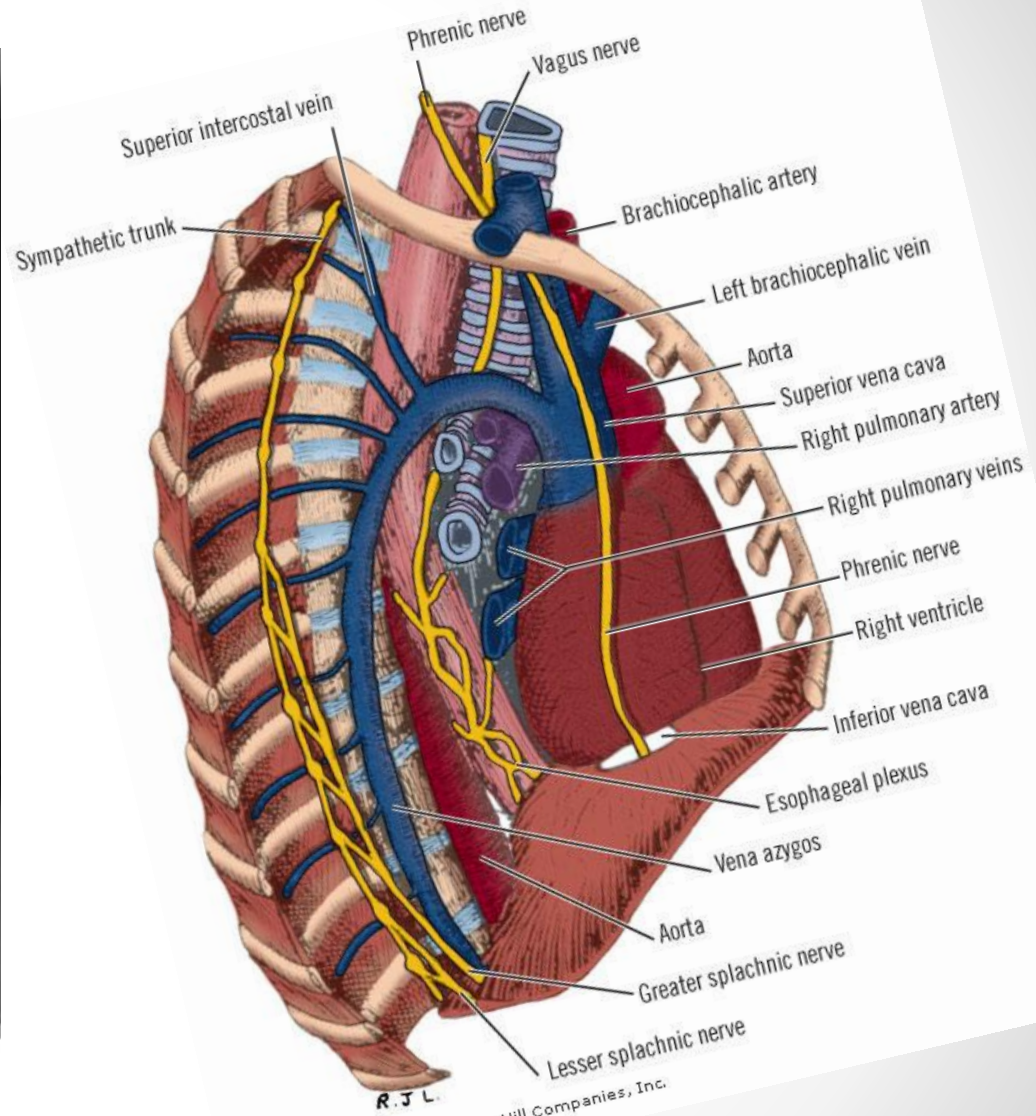




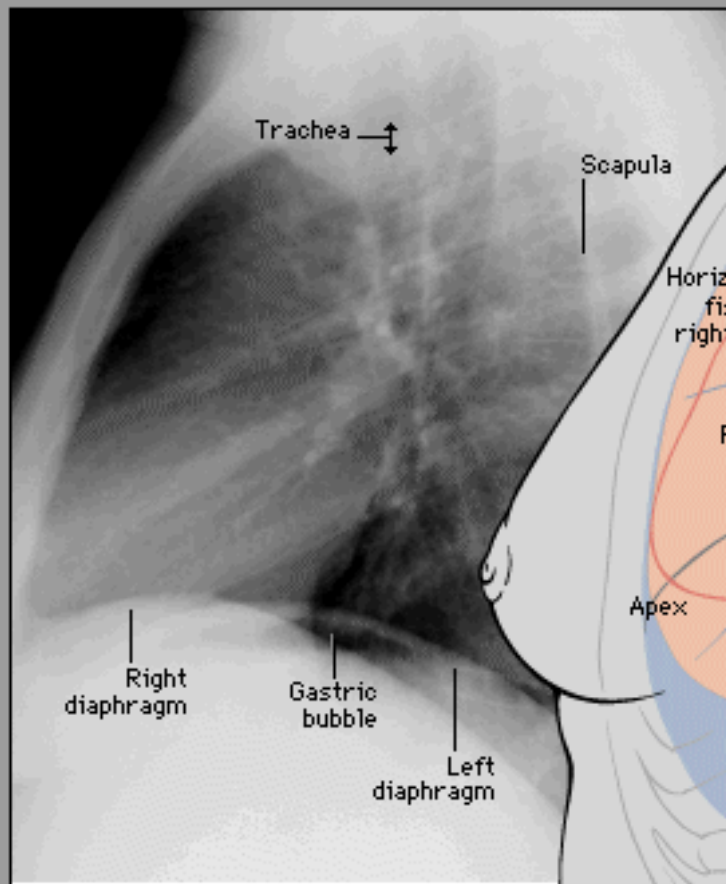
Copyright ©2006 by The McGraw-Hill Companies, Inc.
All rights reserved.



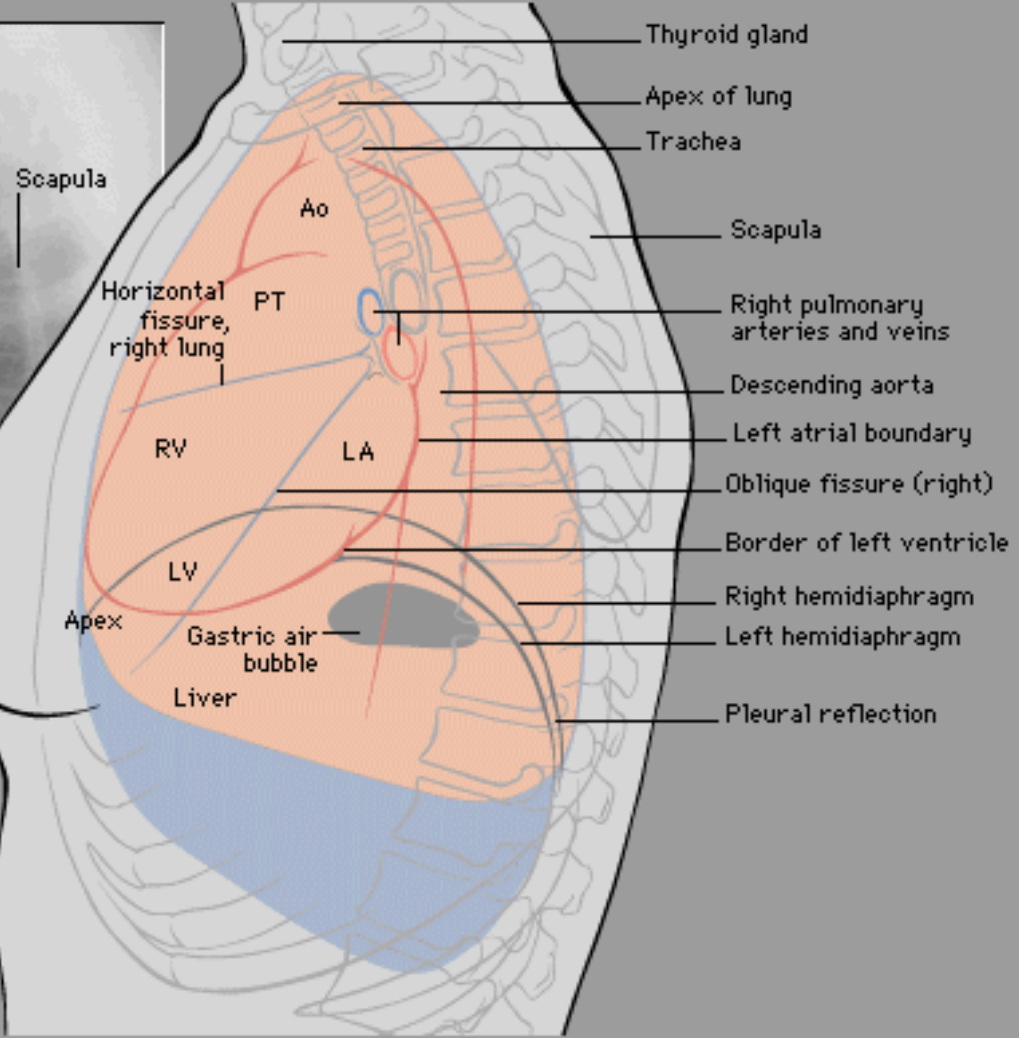
Copyright ©2006 by The McGraw-Hill Companies, Inc.
All rights reserved.



R J L.
Copyright ©2006 by The McGraw-Hill Companies, Inc.
All rights reserved.



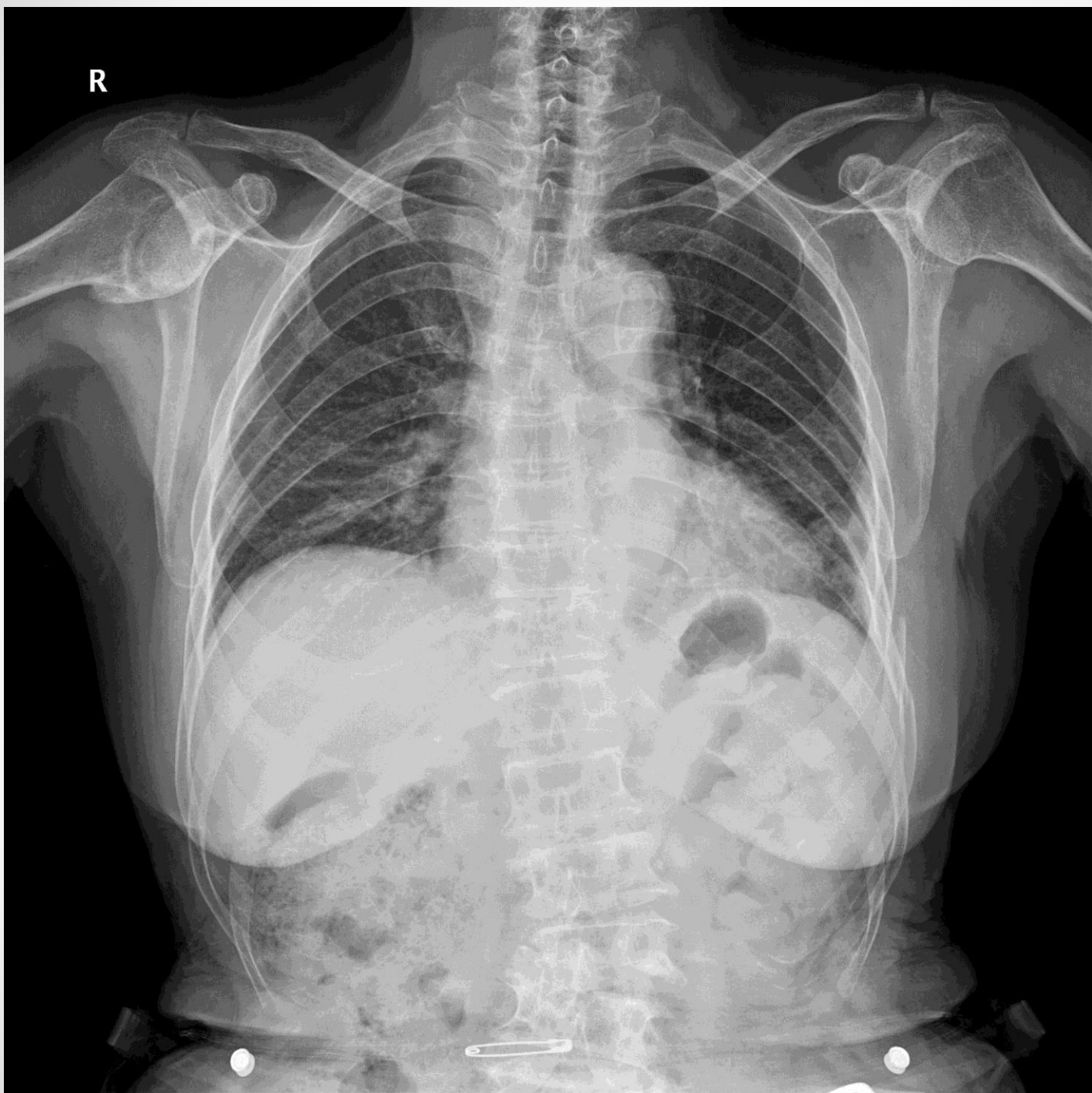Note breast shadow on female patients

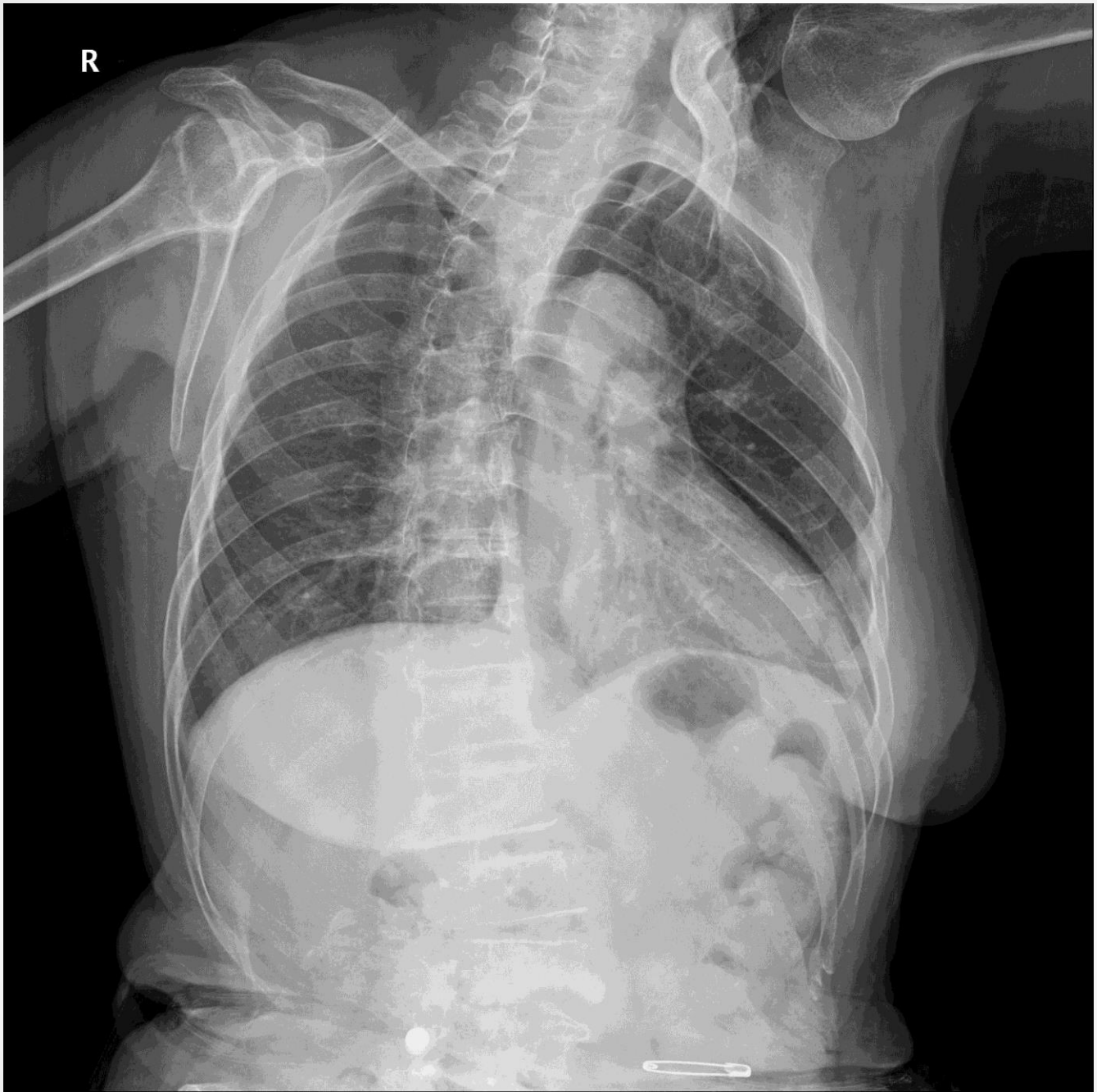


chapter 1

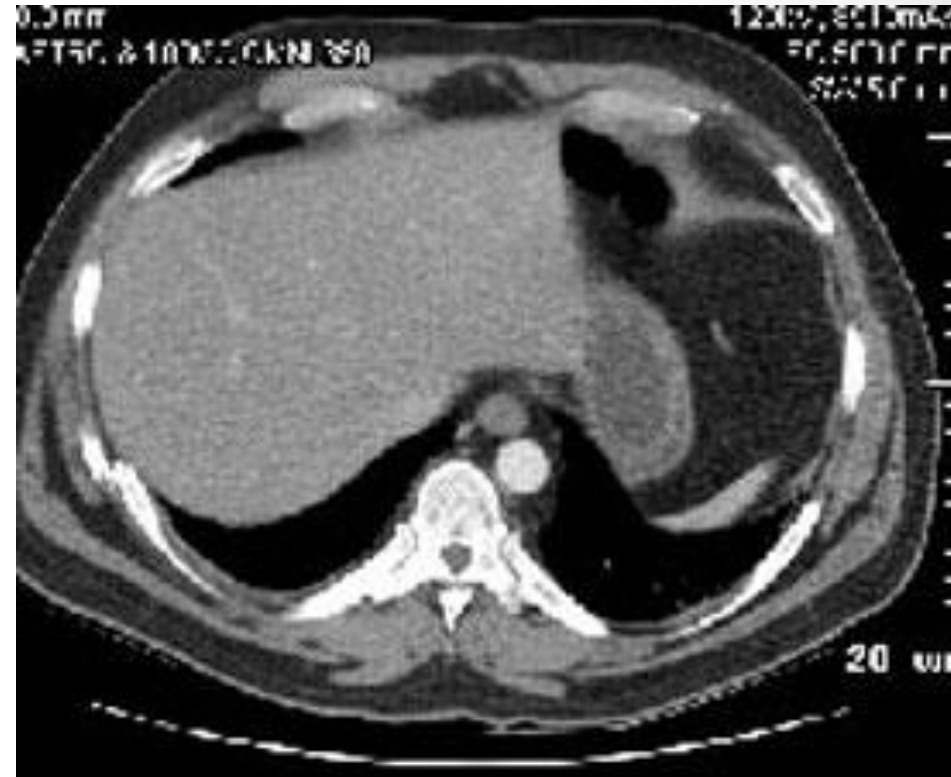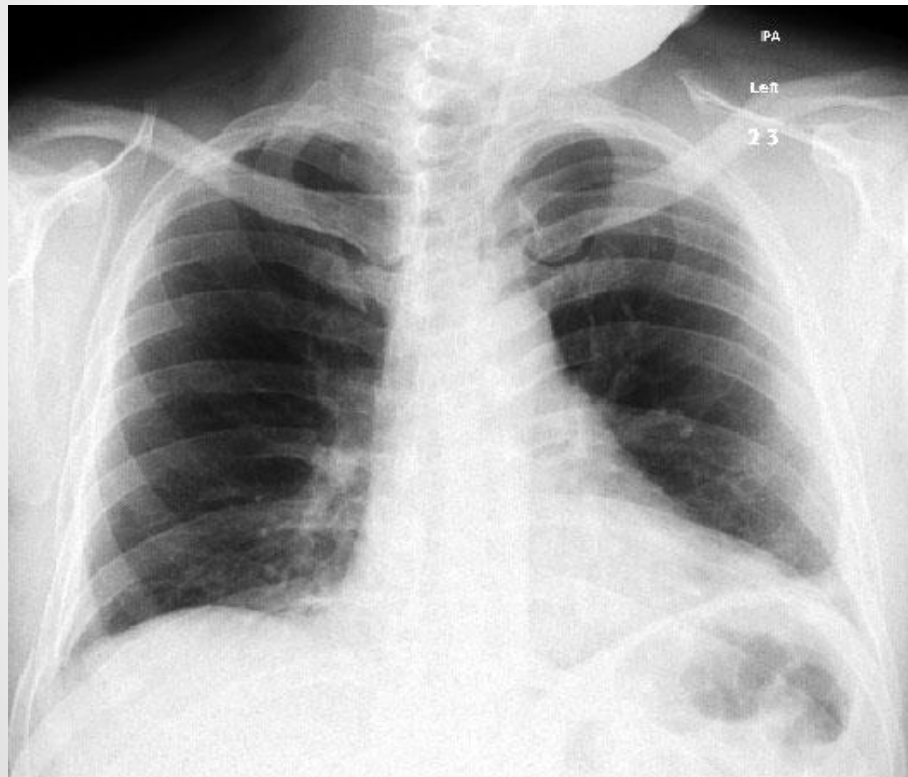
- Rib Fx.
- Pneumothorax
- Pleural effusion

R

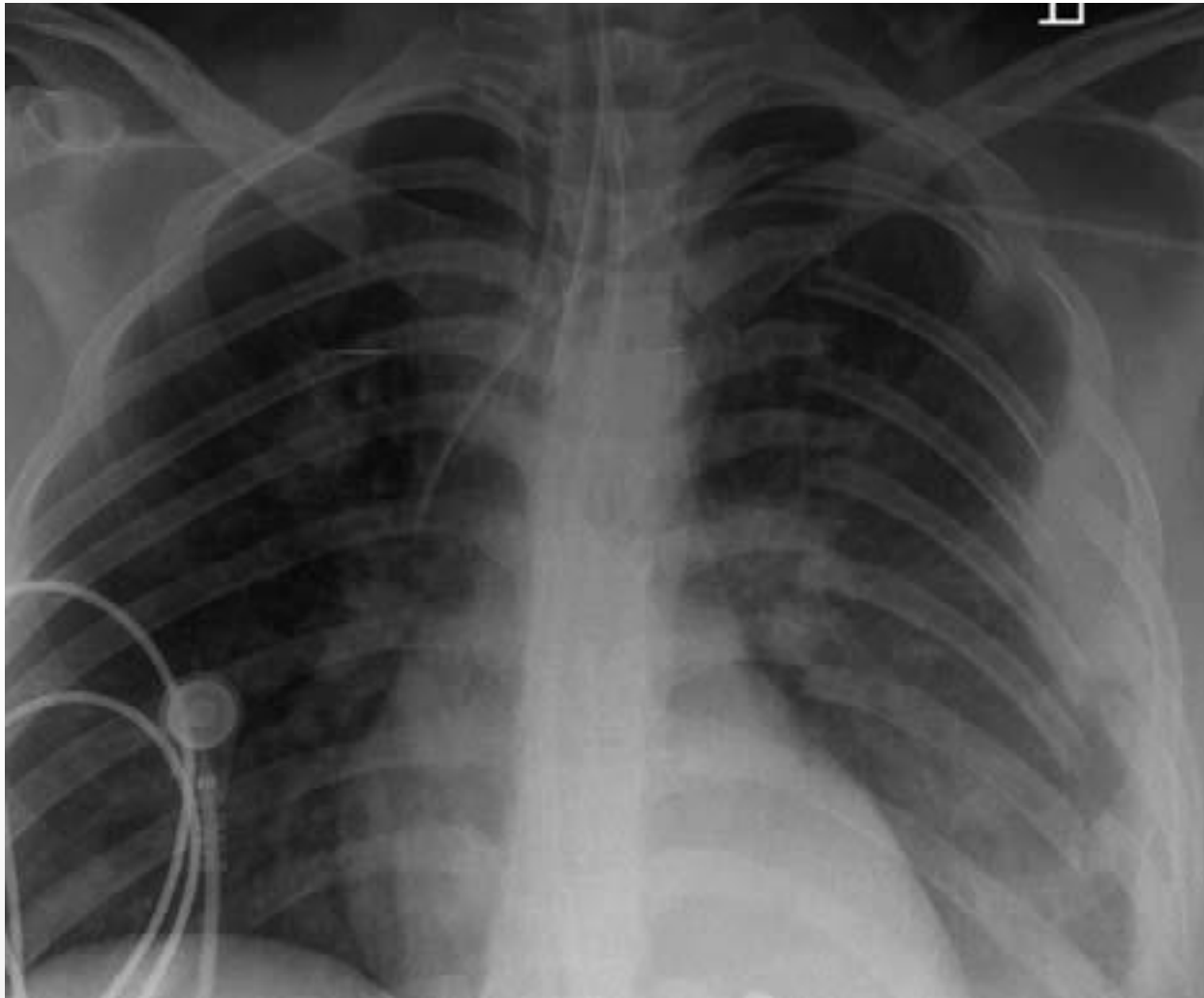




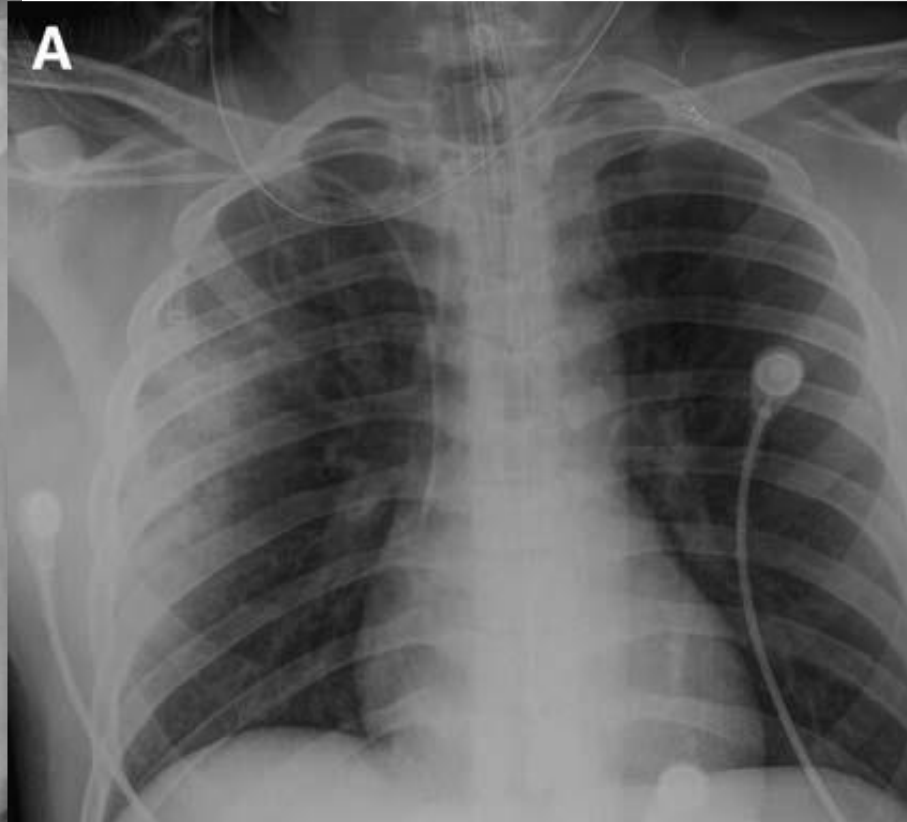
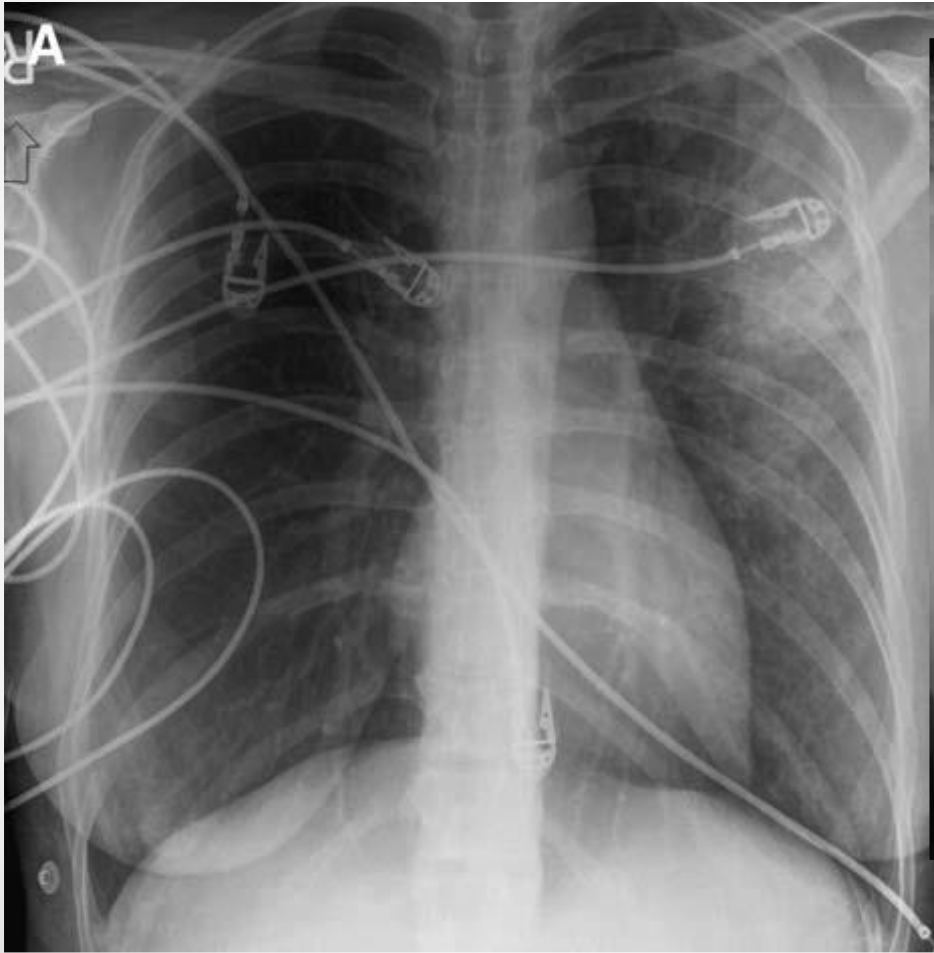
Rib fracture - single



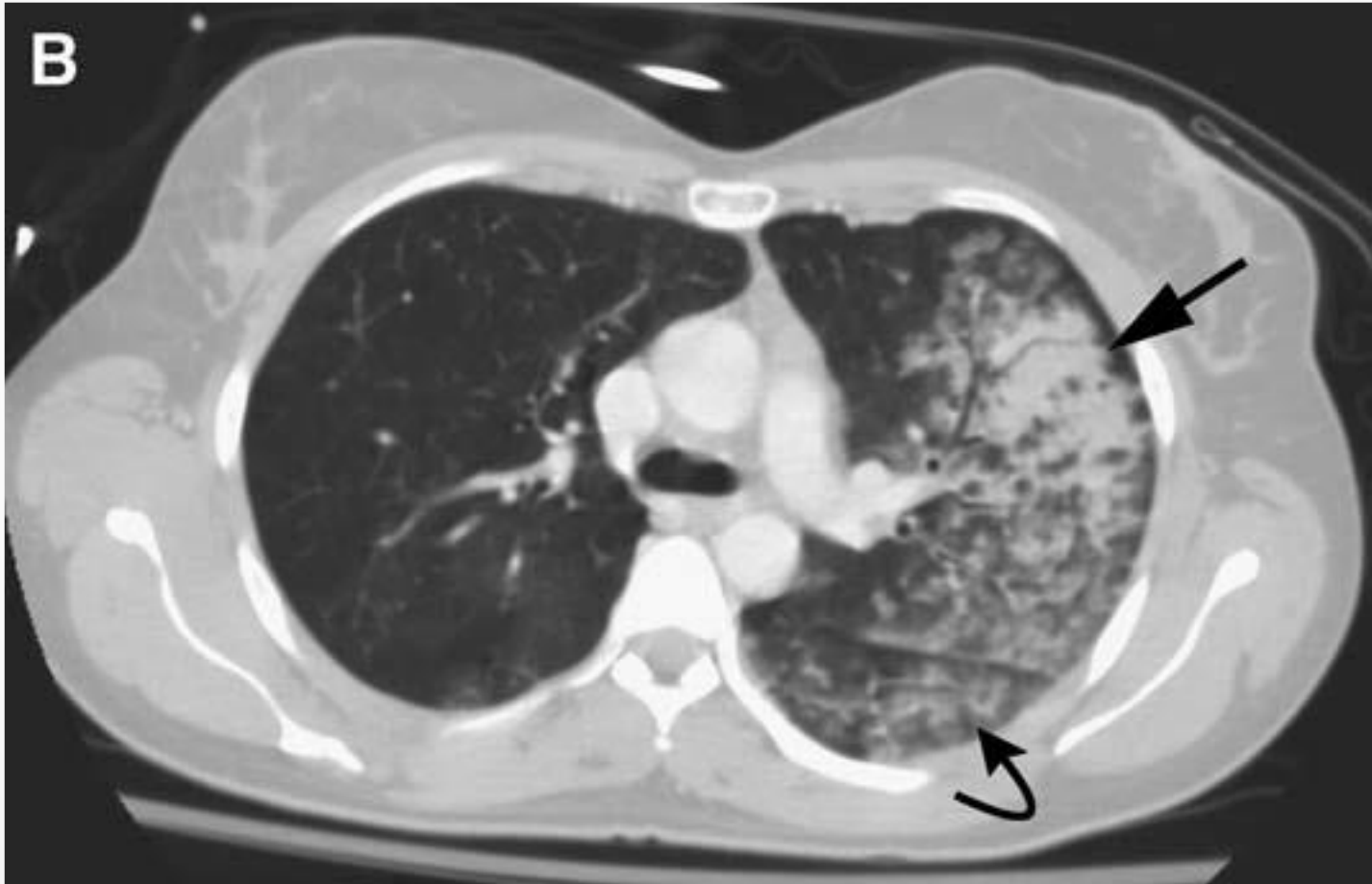Rib fracture - multiple



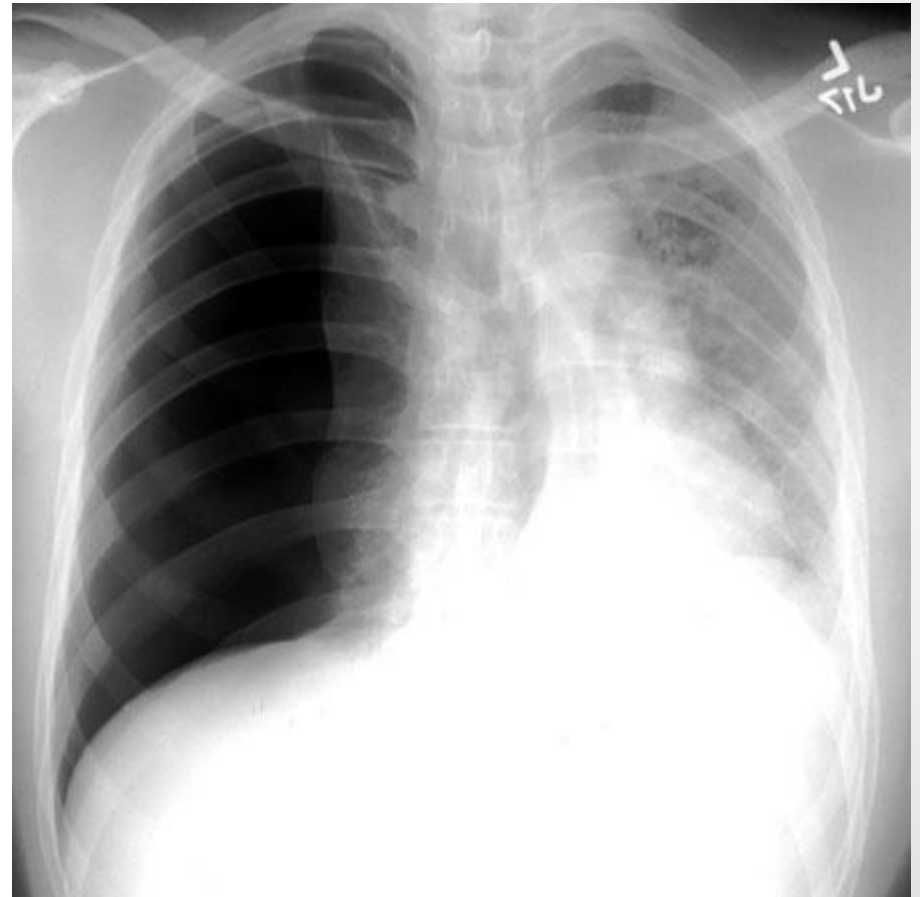
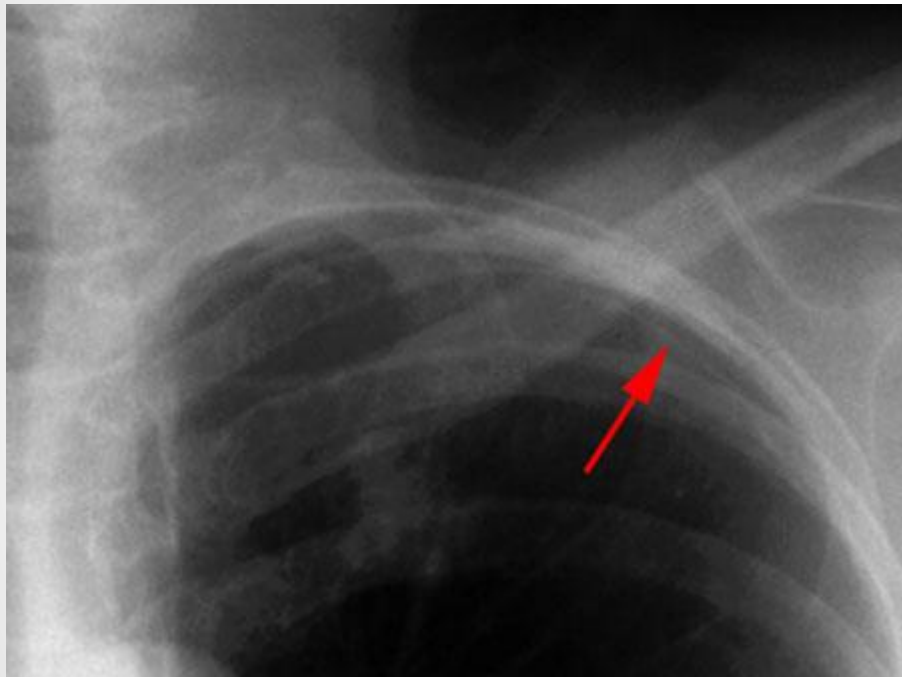
Lung contusion



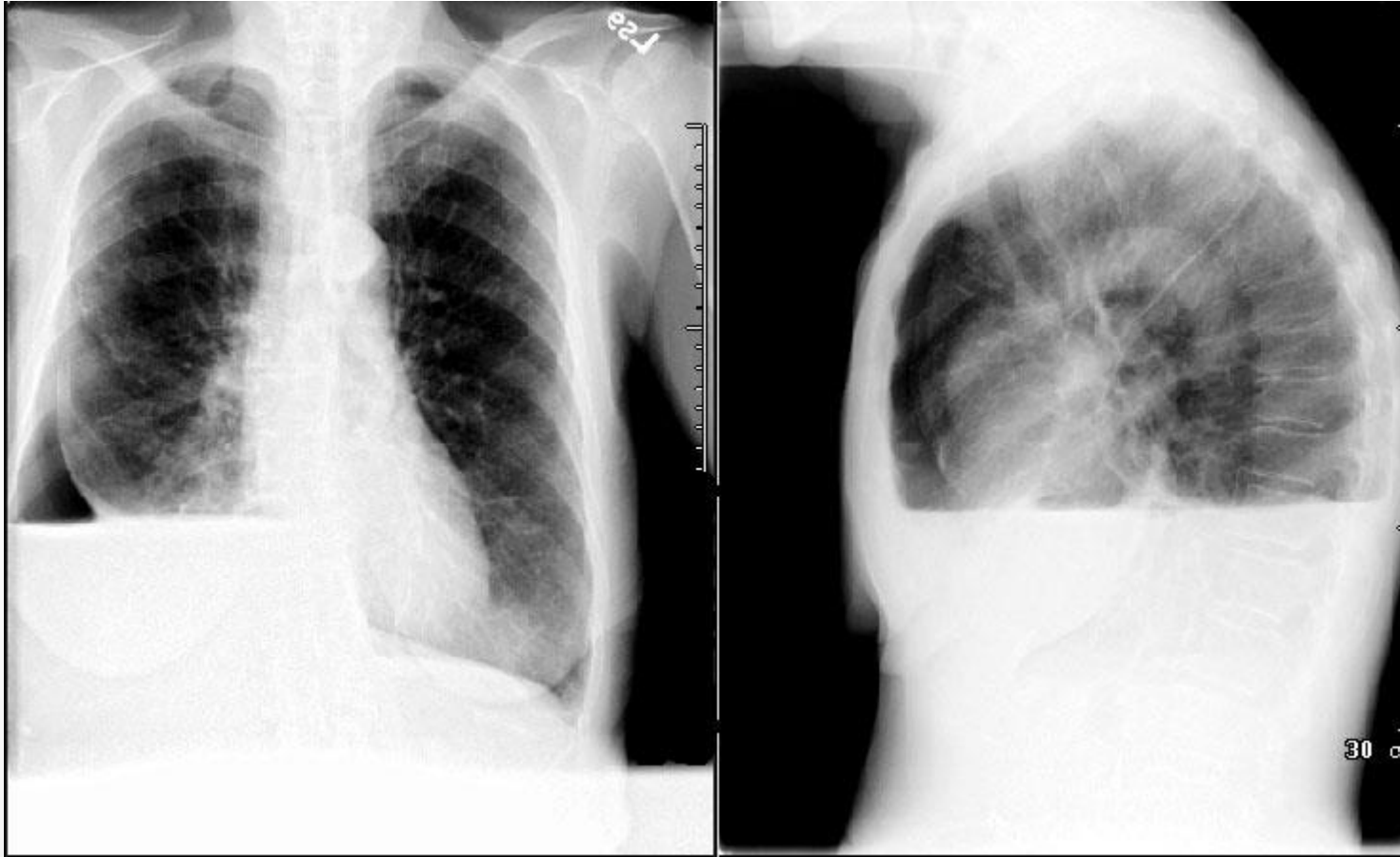Lung contusion



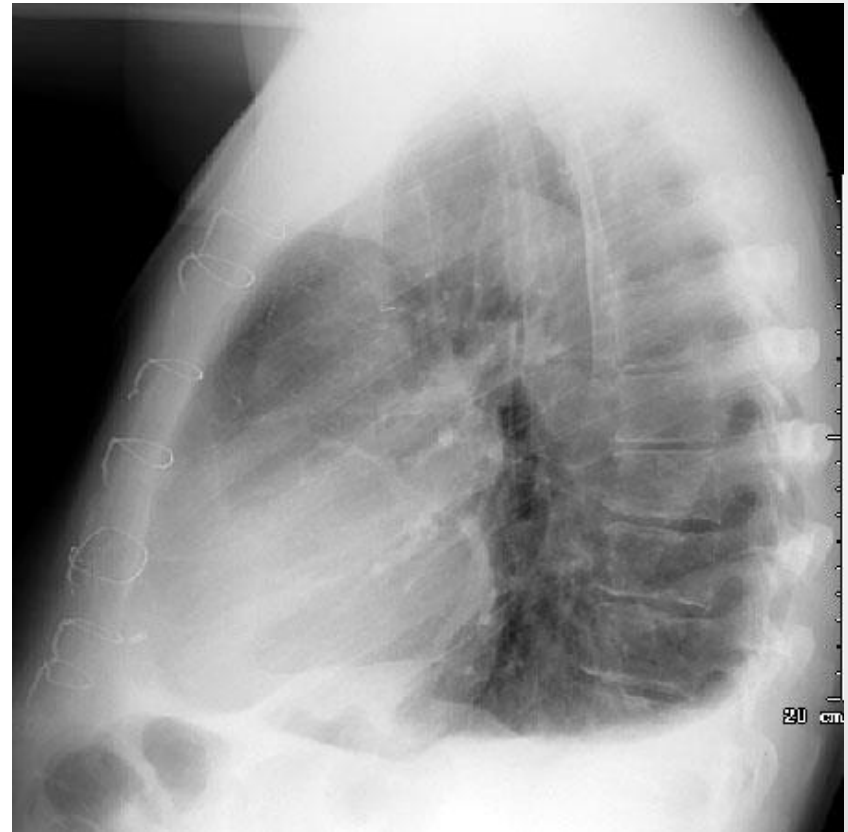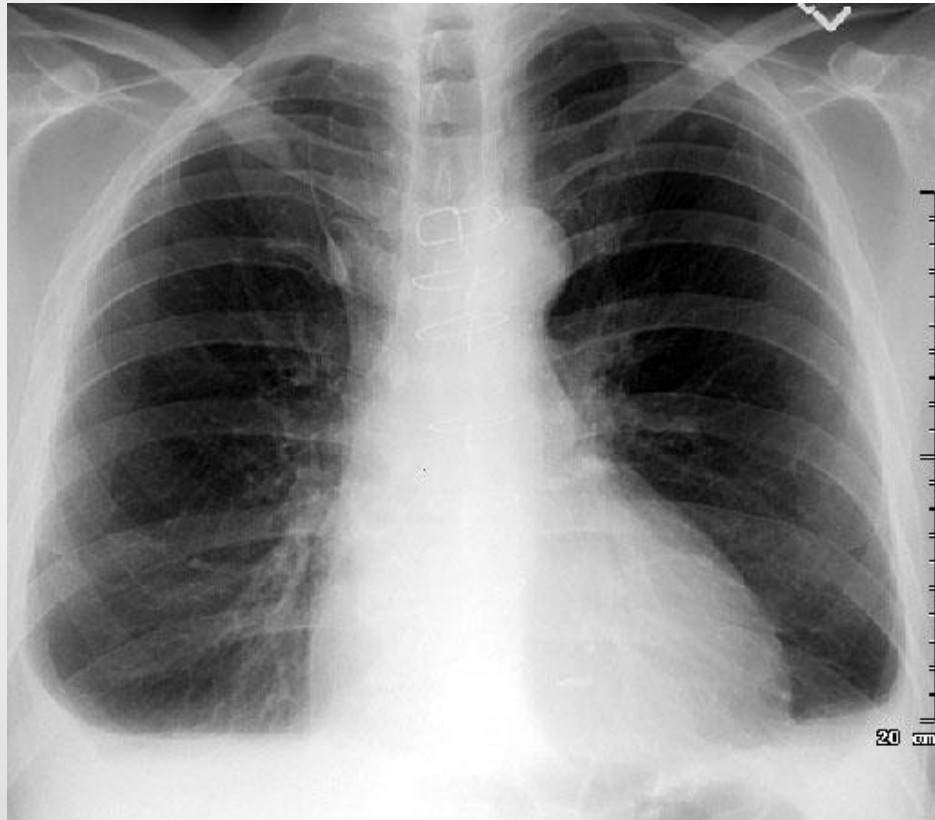
Pneumothorax



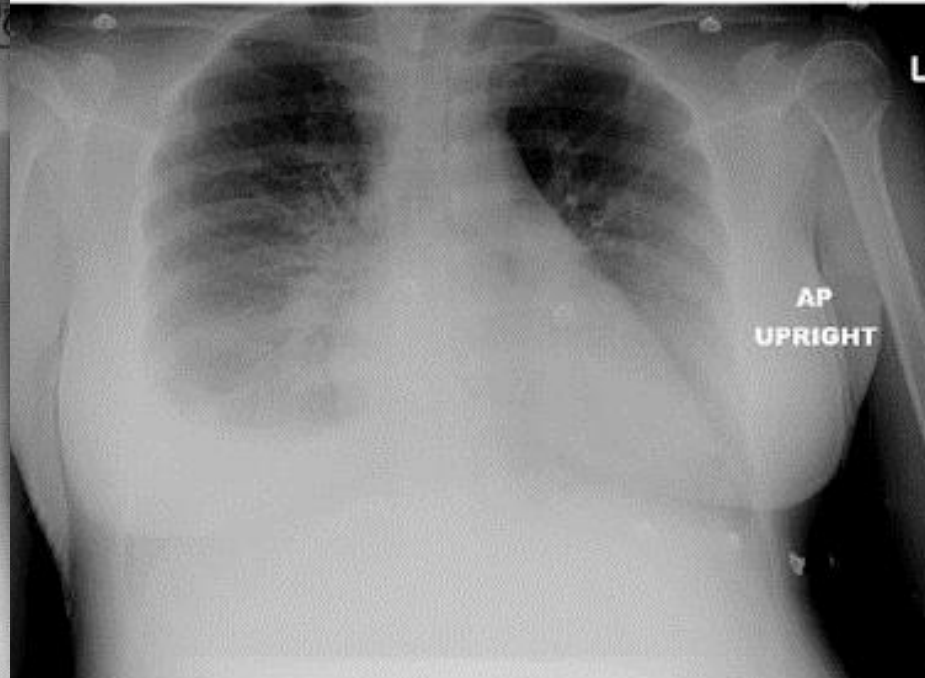
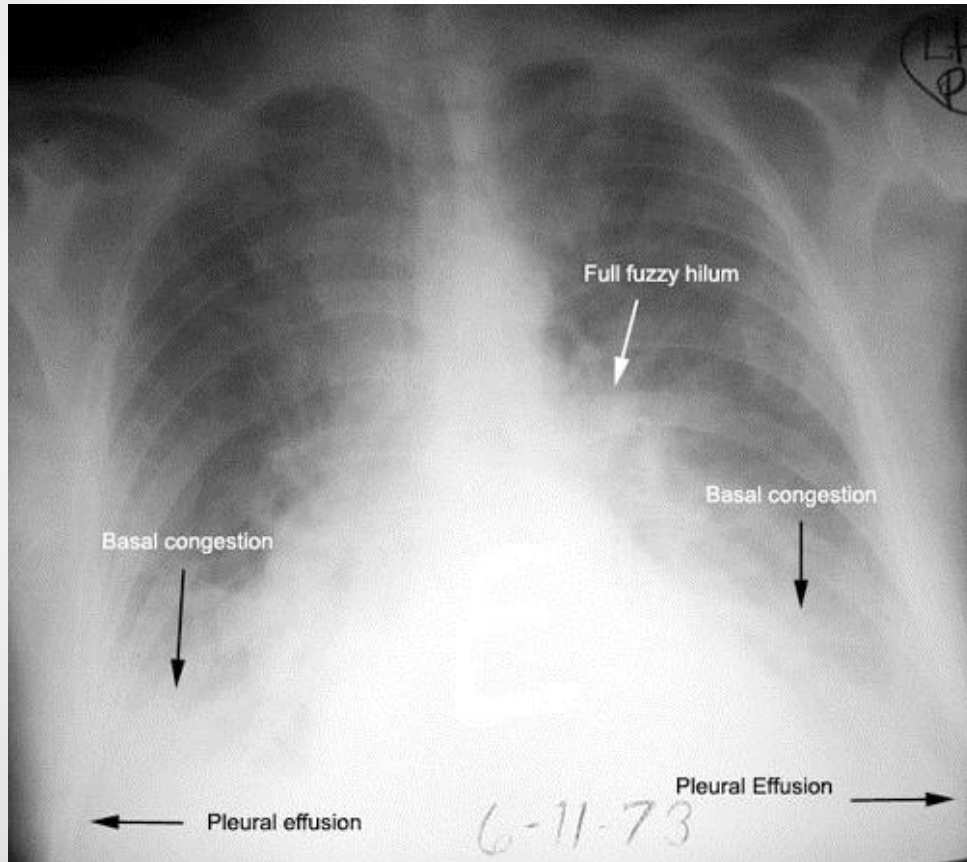
Hydropneumothorax

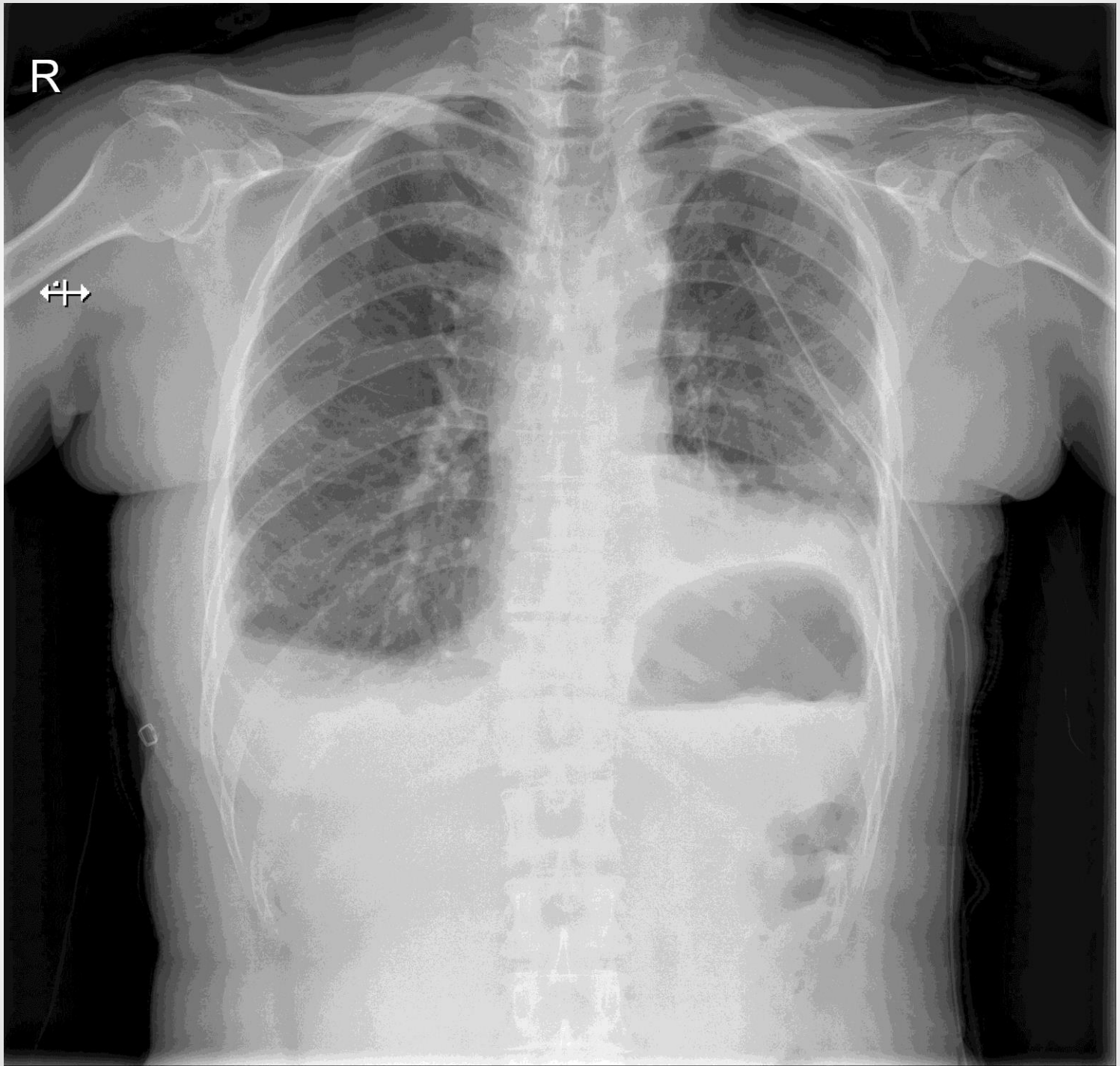


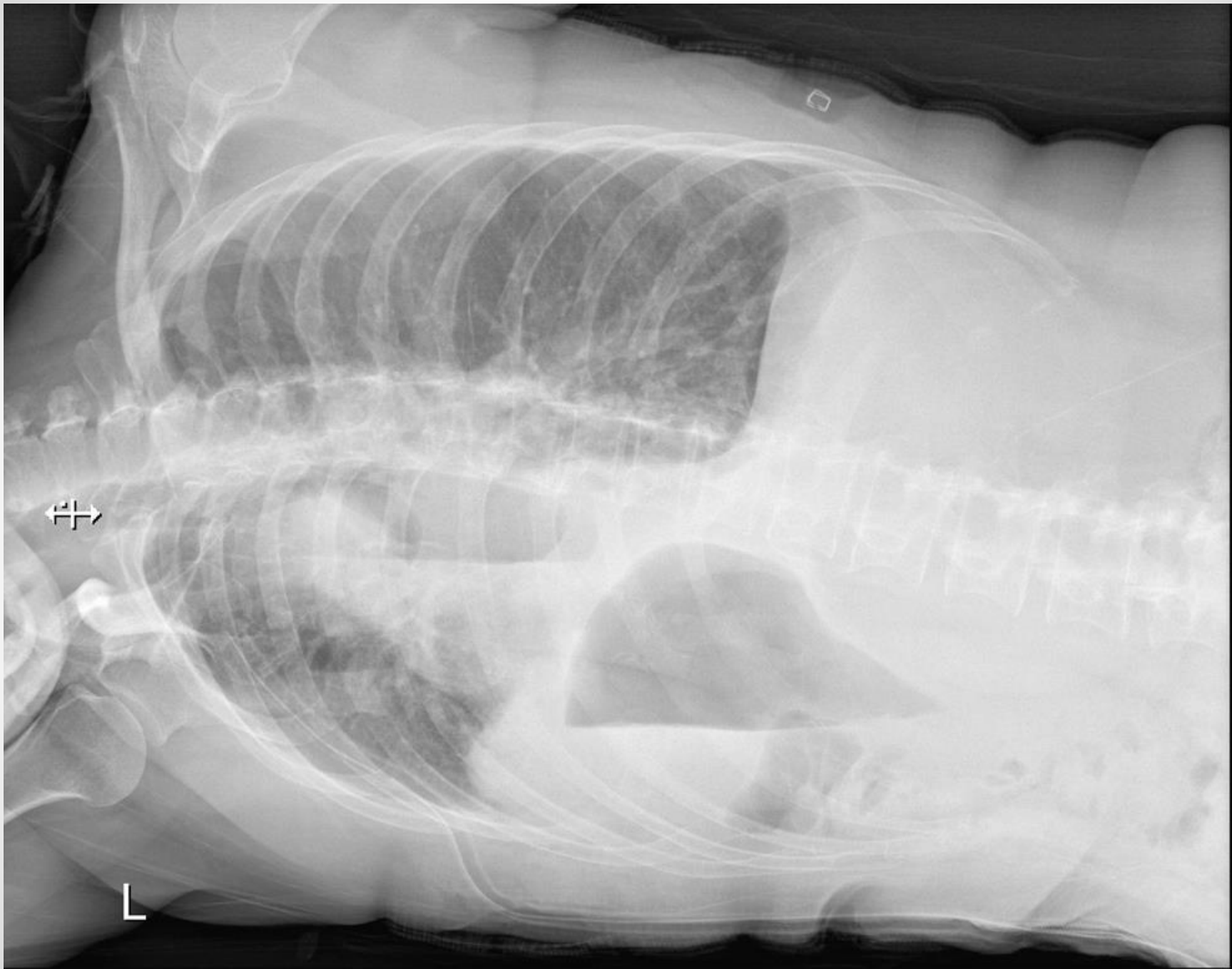Pleural effusion - chest PA

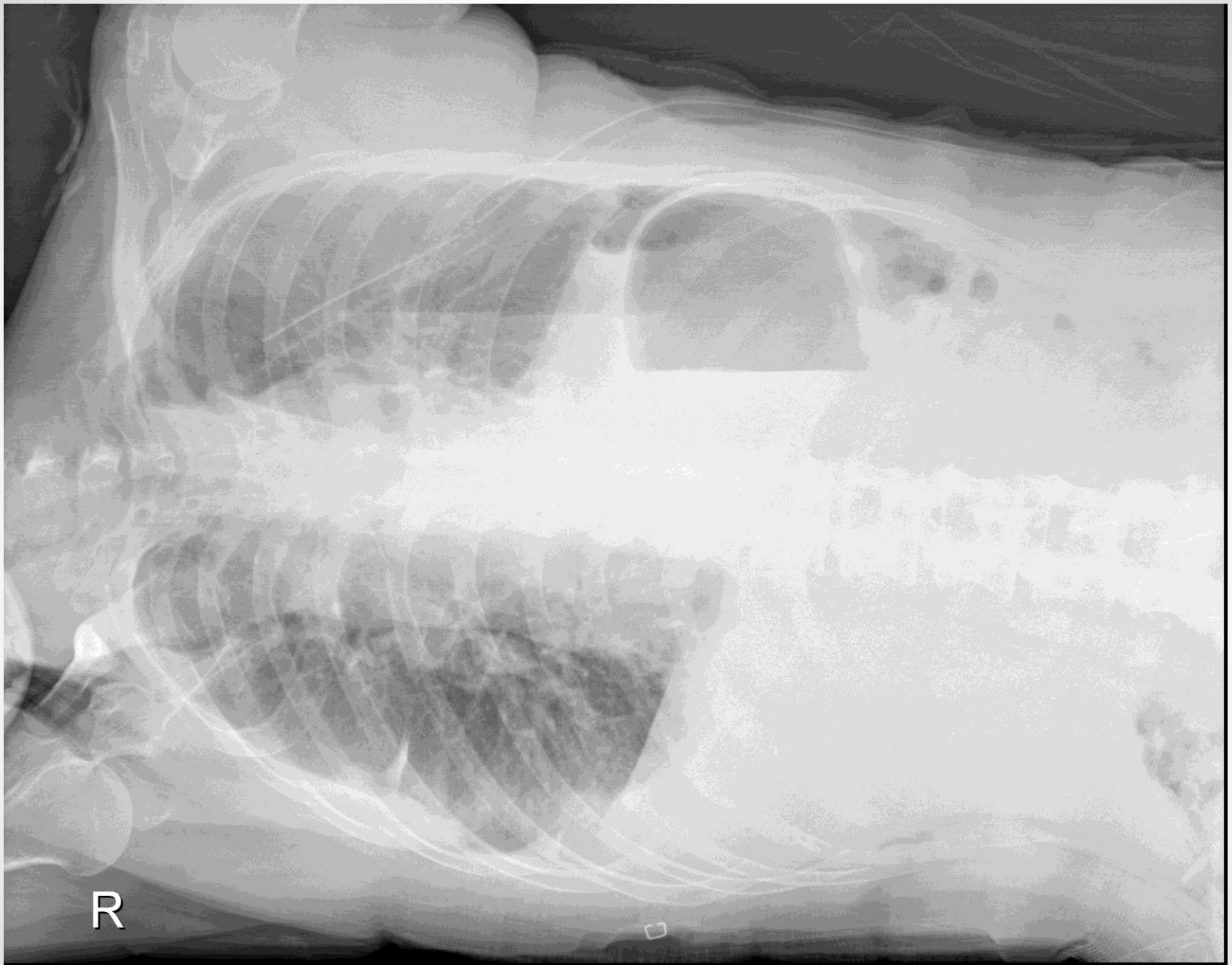

Pleural effusion - chest AP









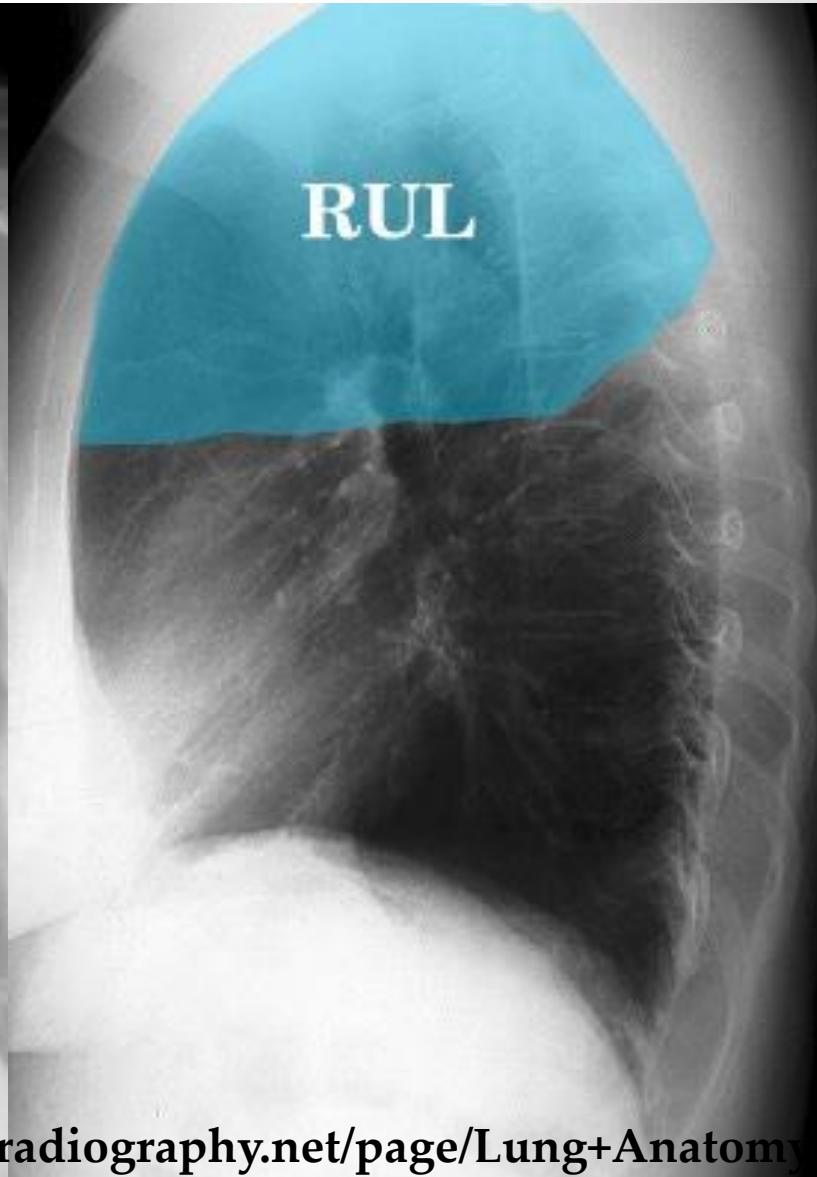
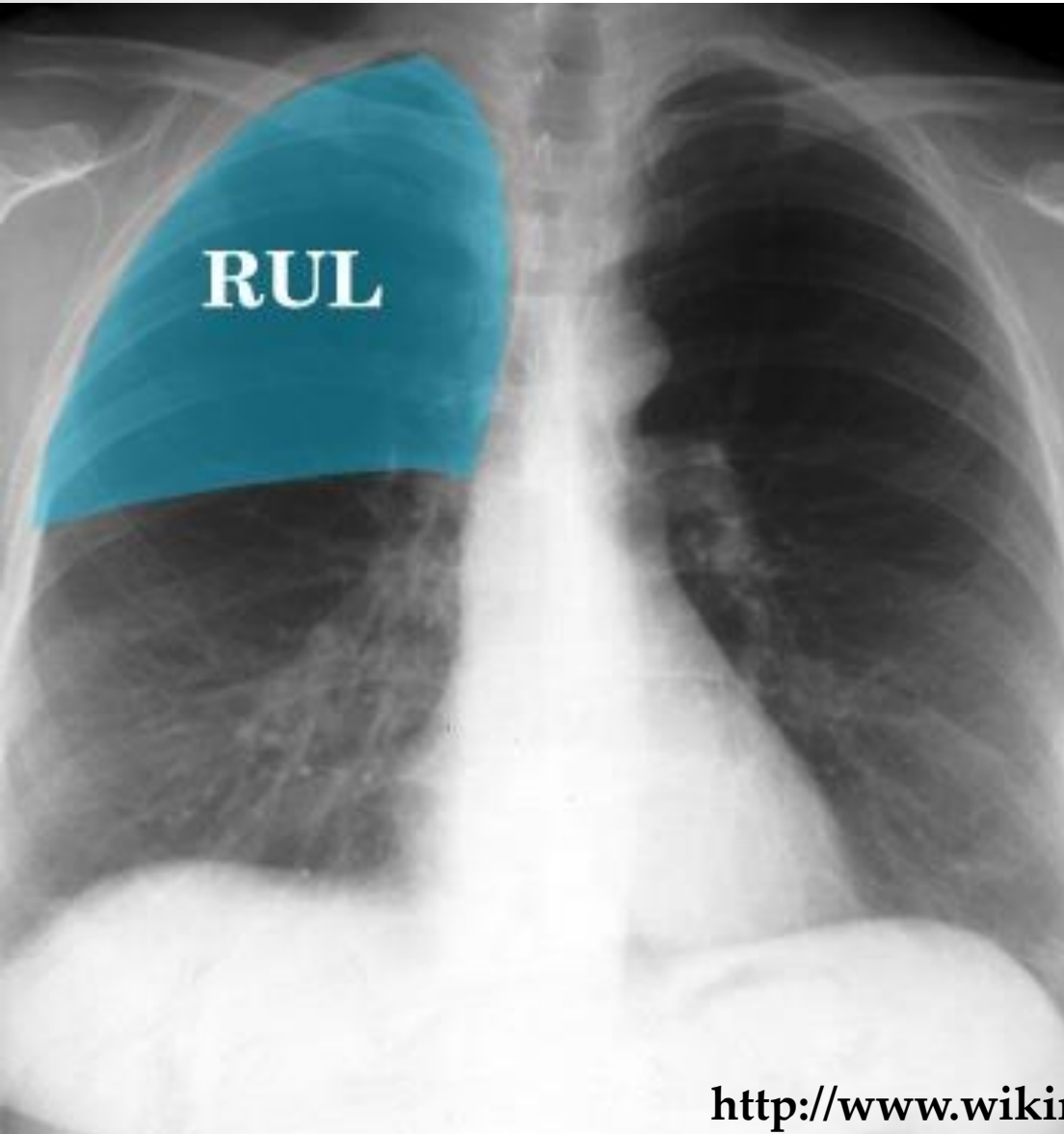
chapter 2 Lung

Atelectasis

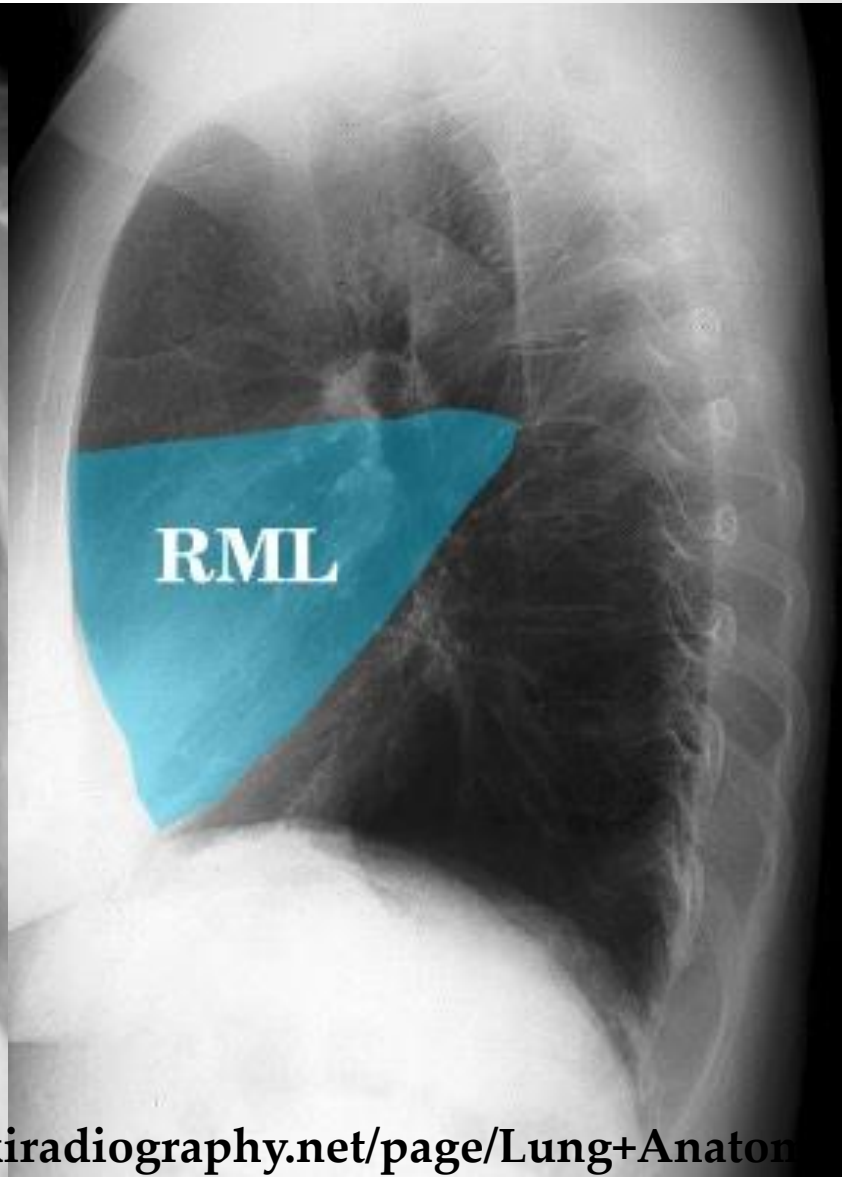
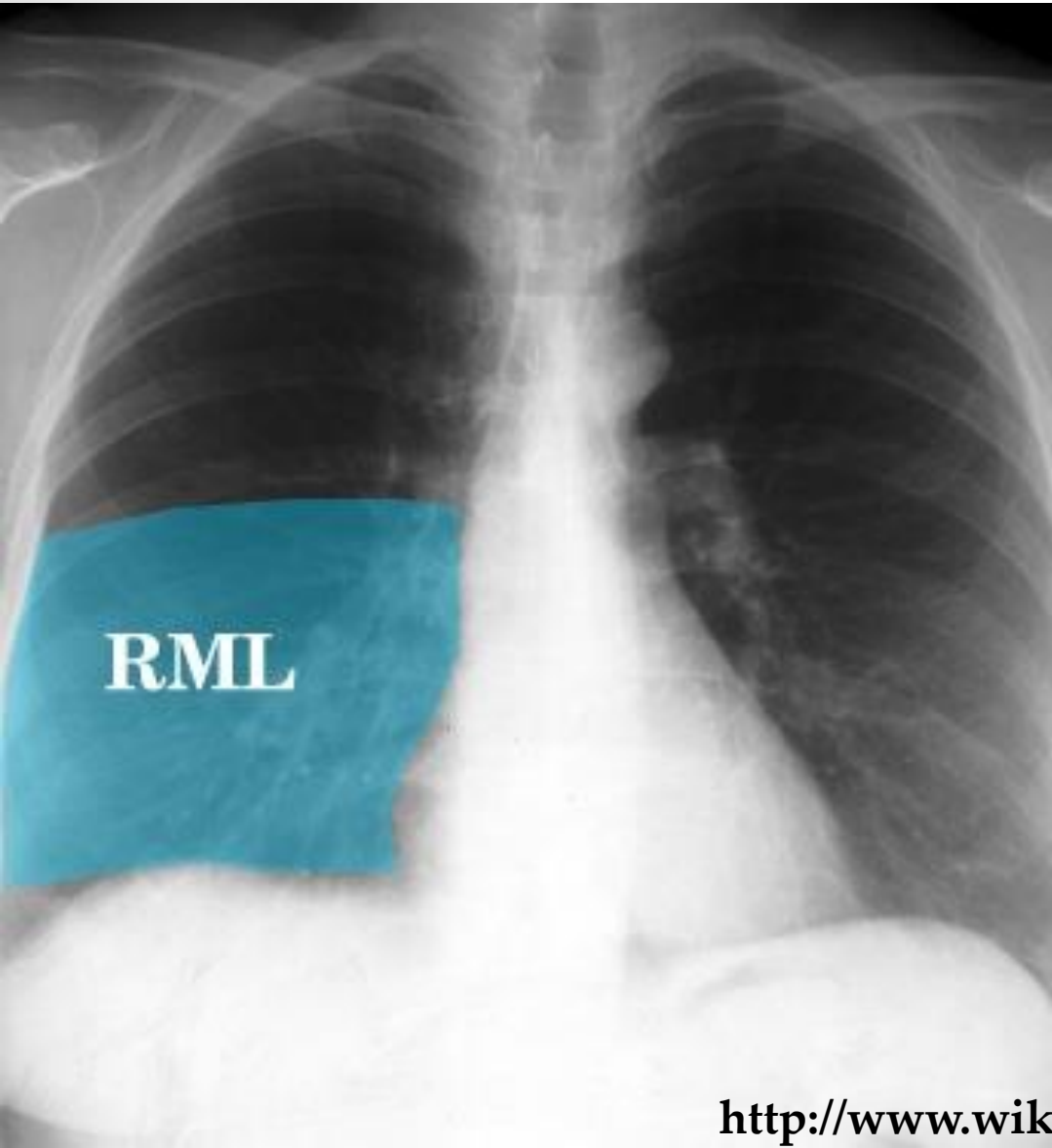
Pneumonia

Pulmonary emphysema

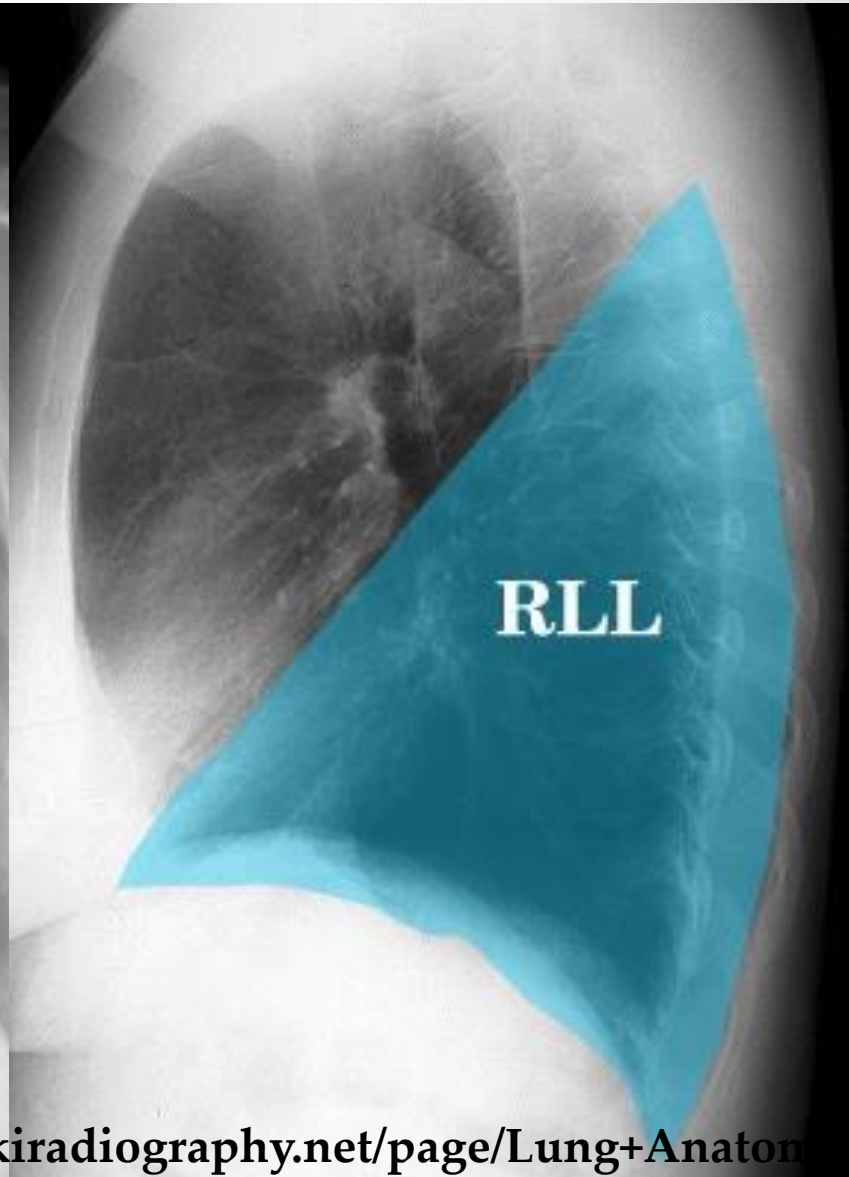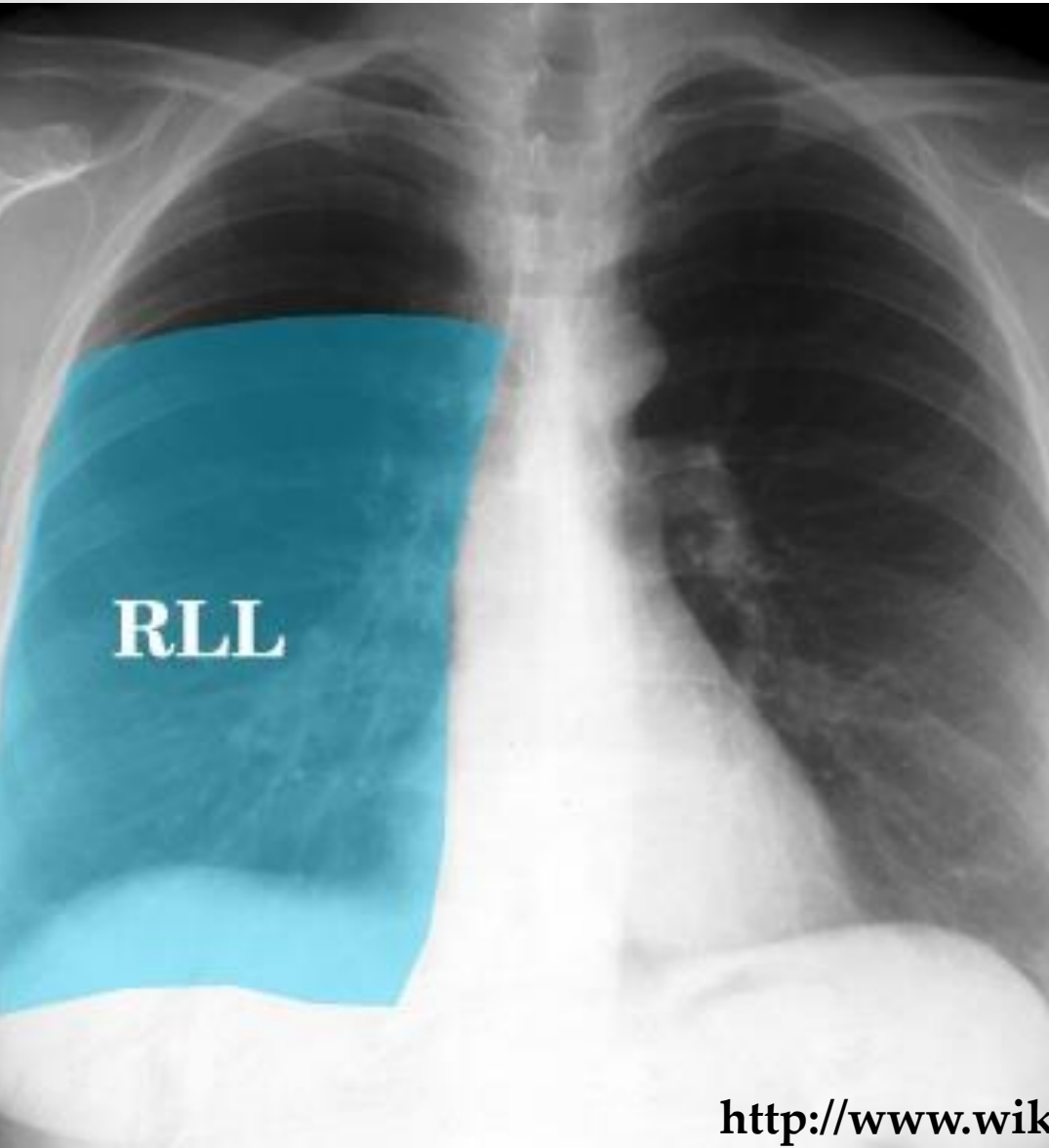
Lobe



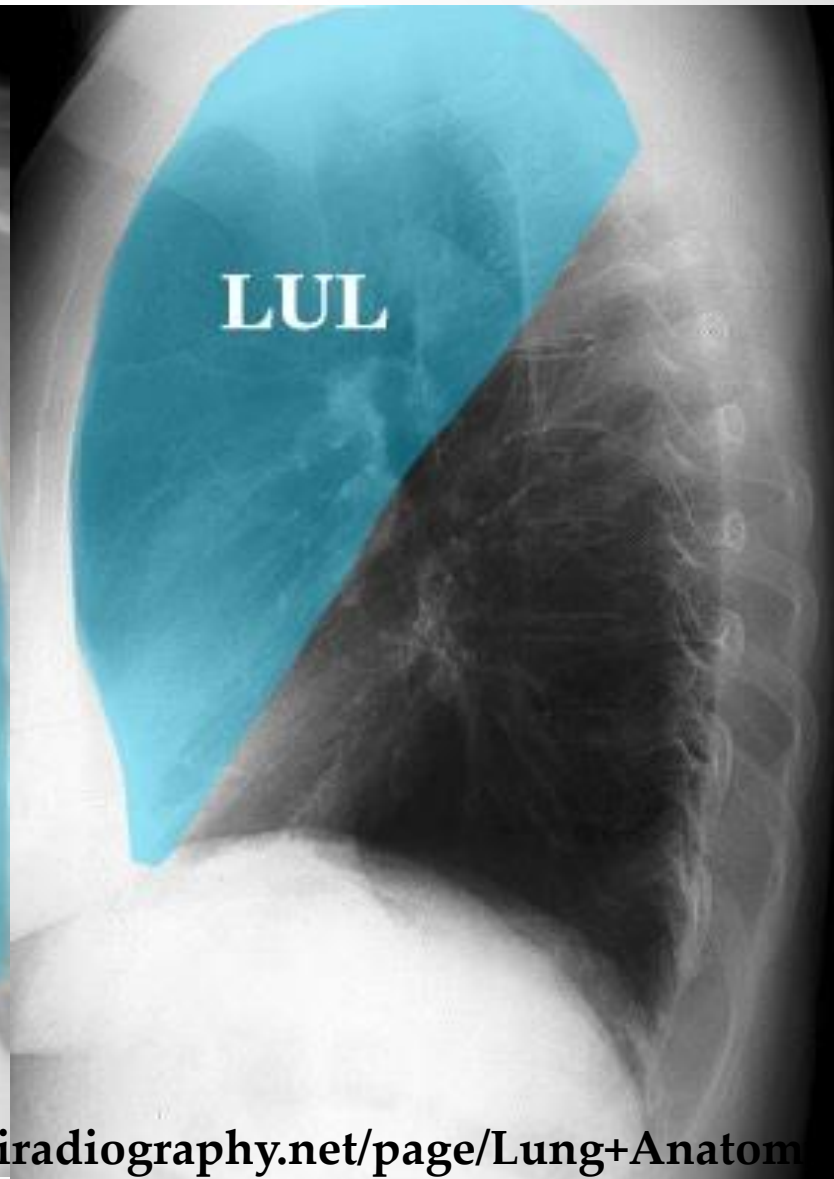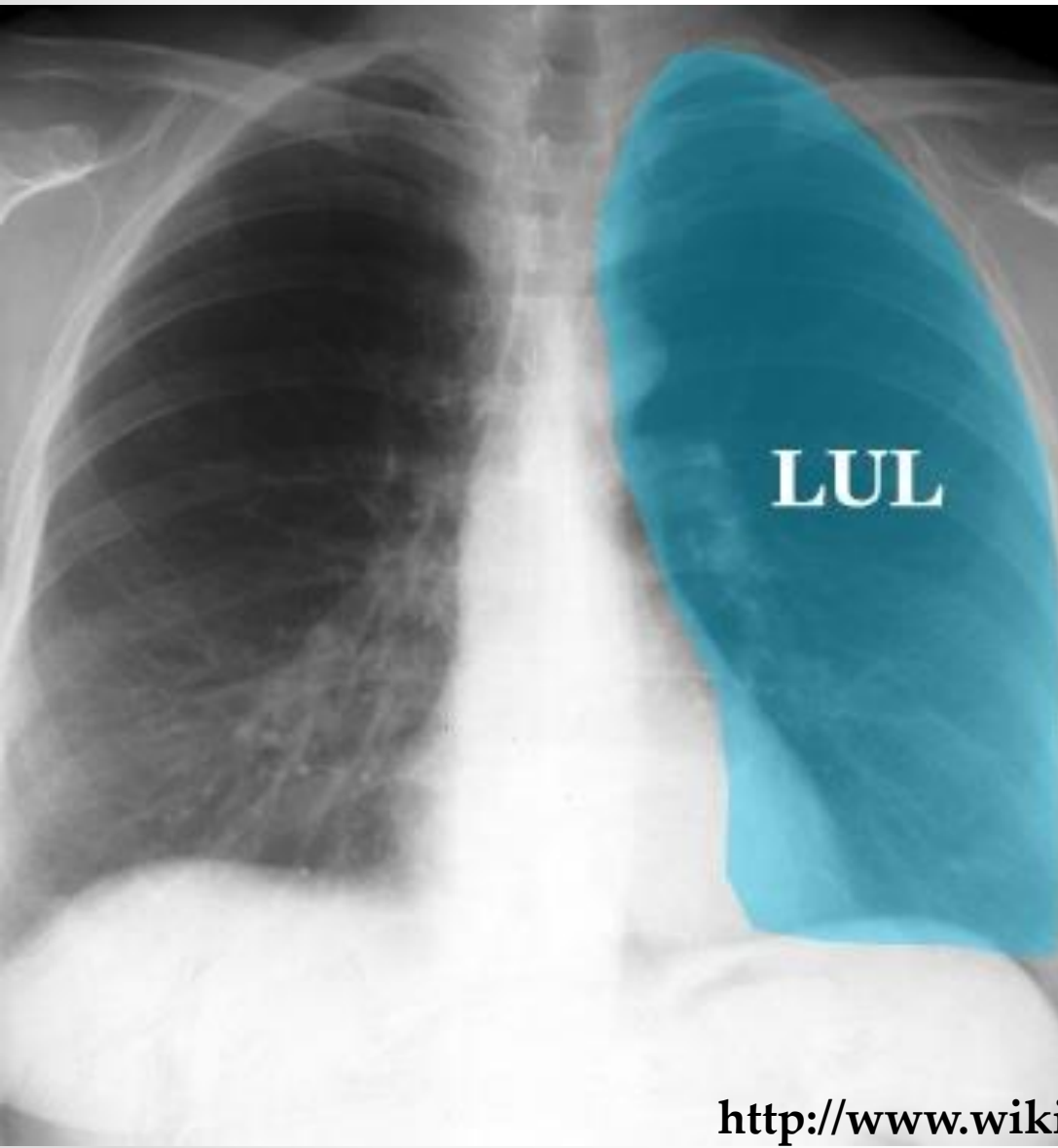
Lobe



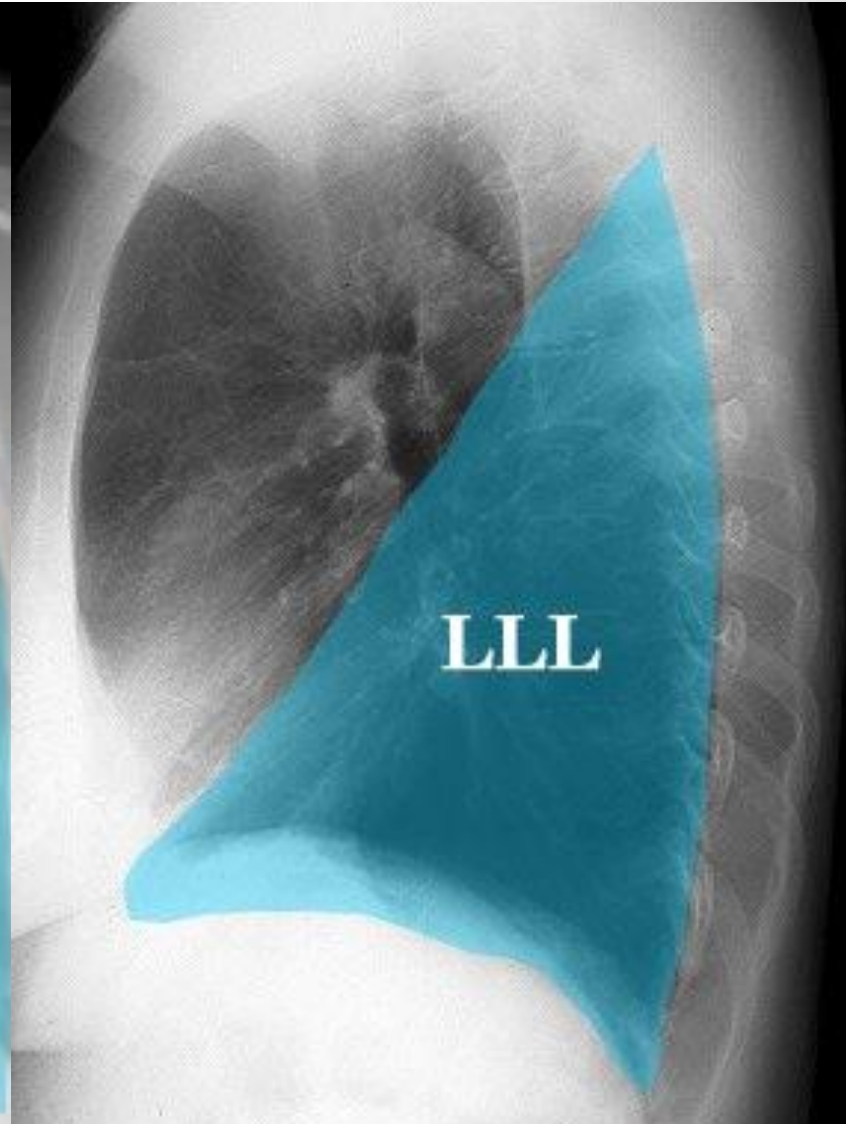
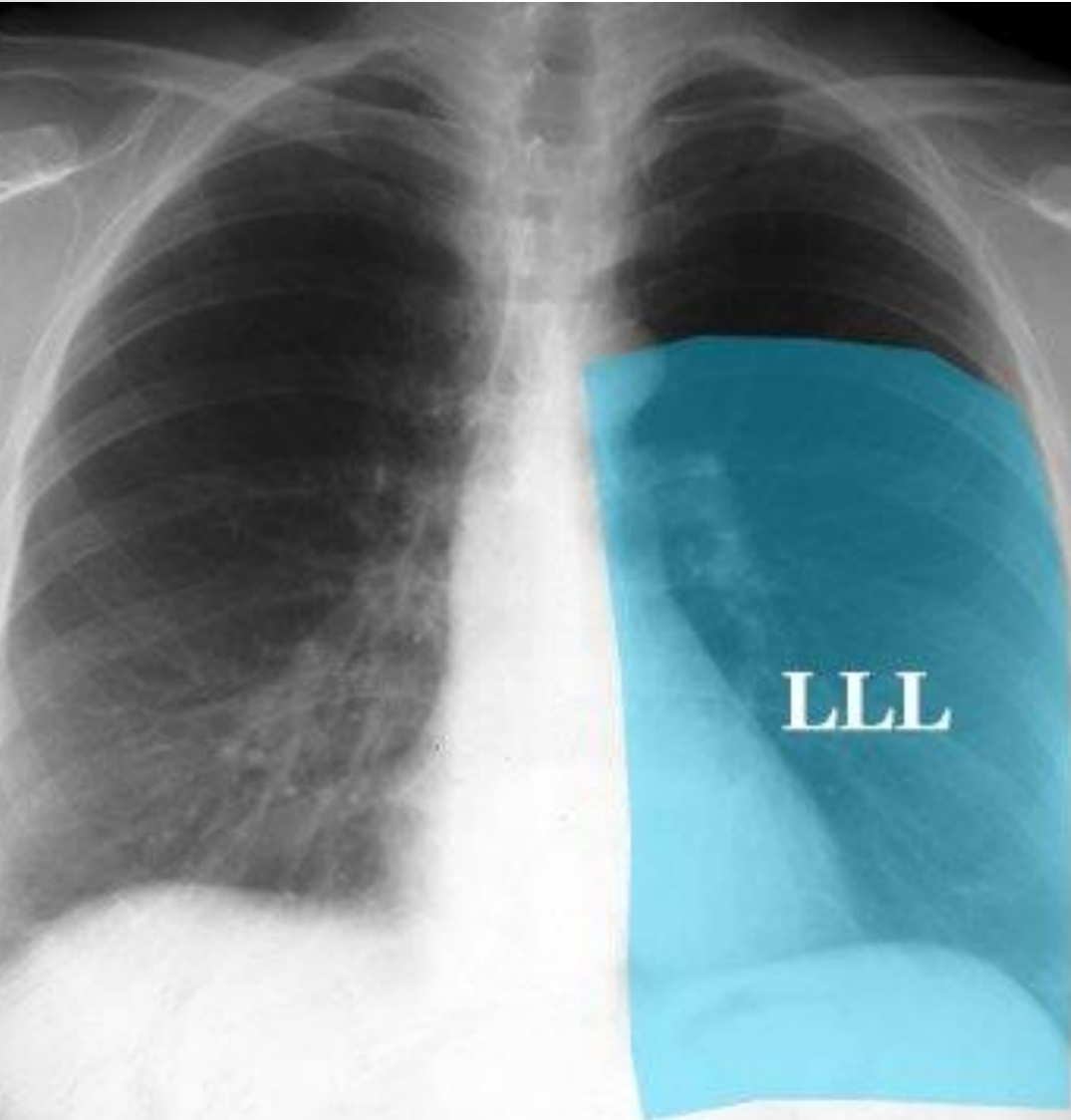
Lobe



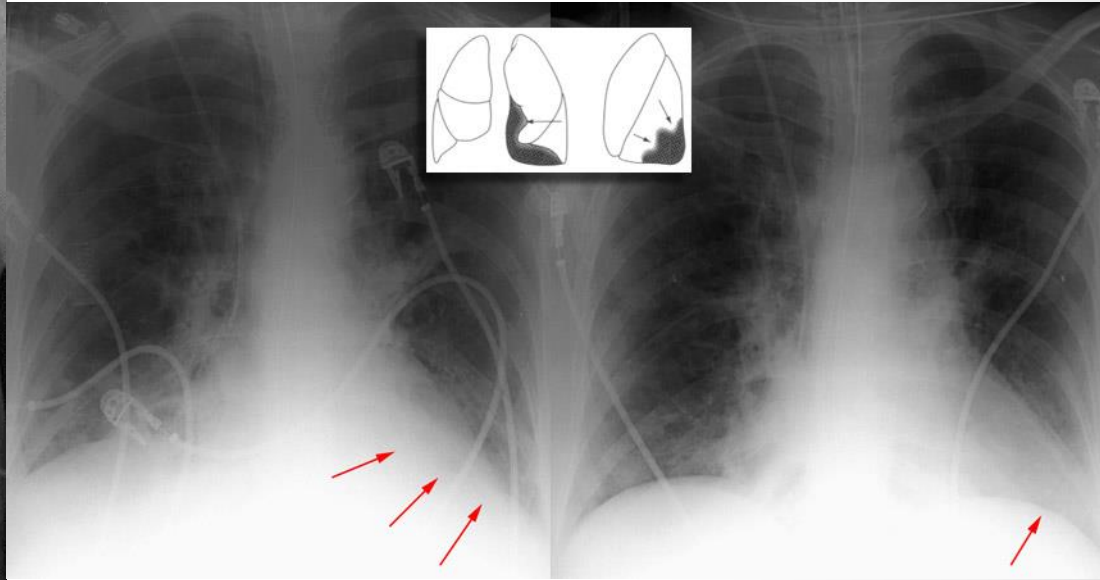
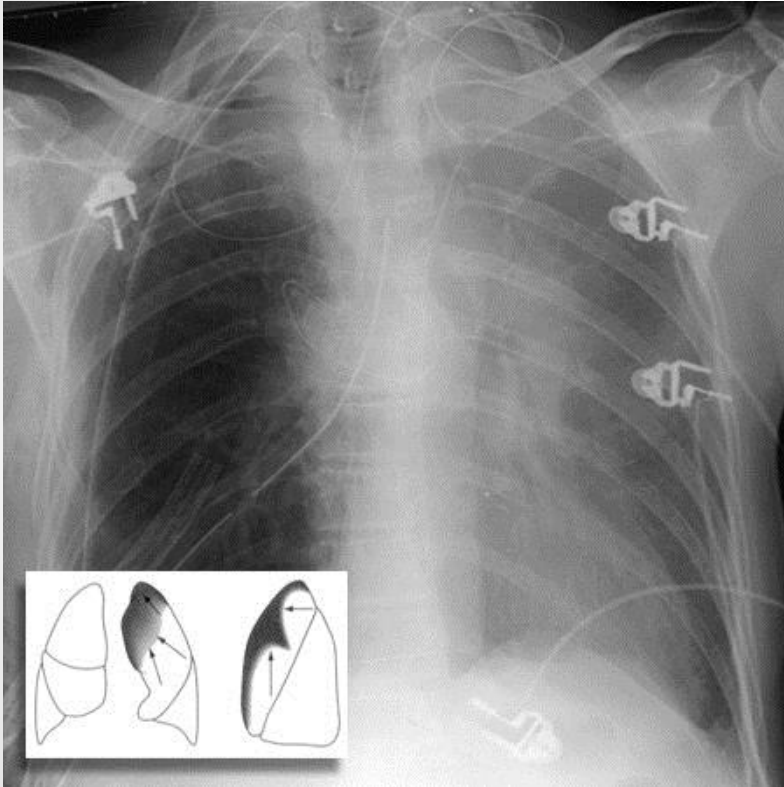
Lobe



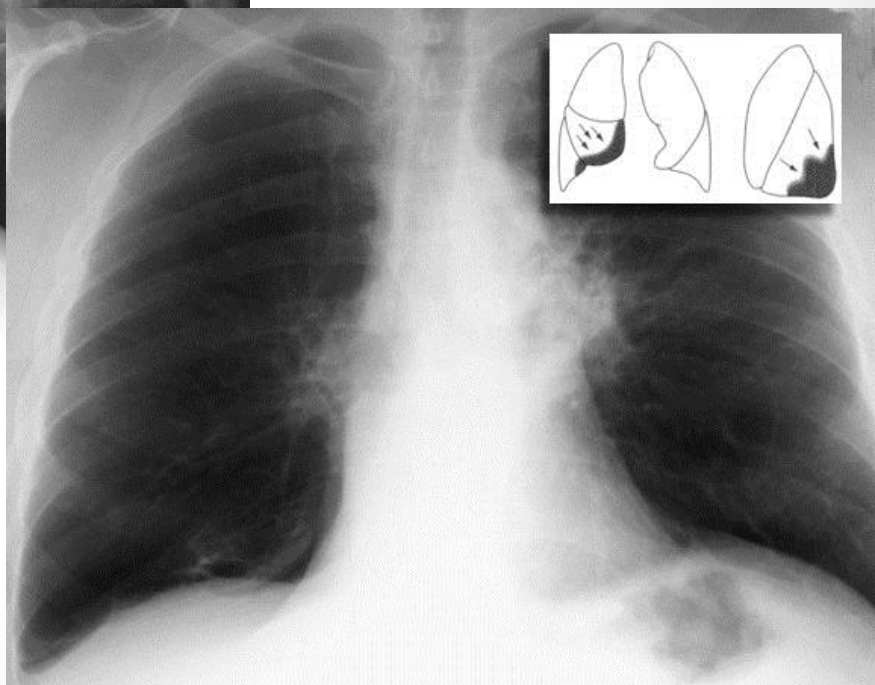
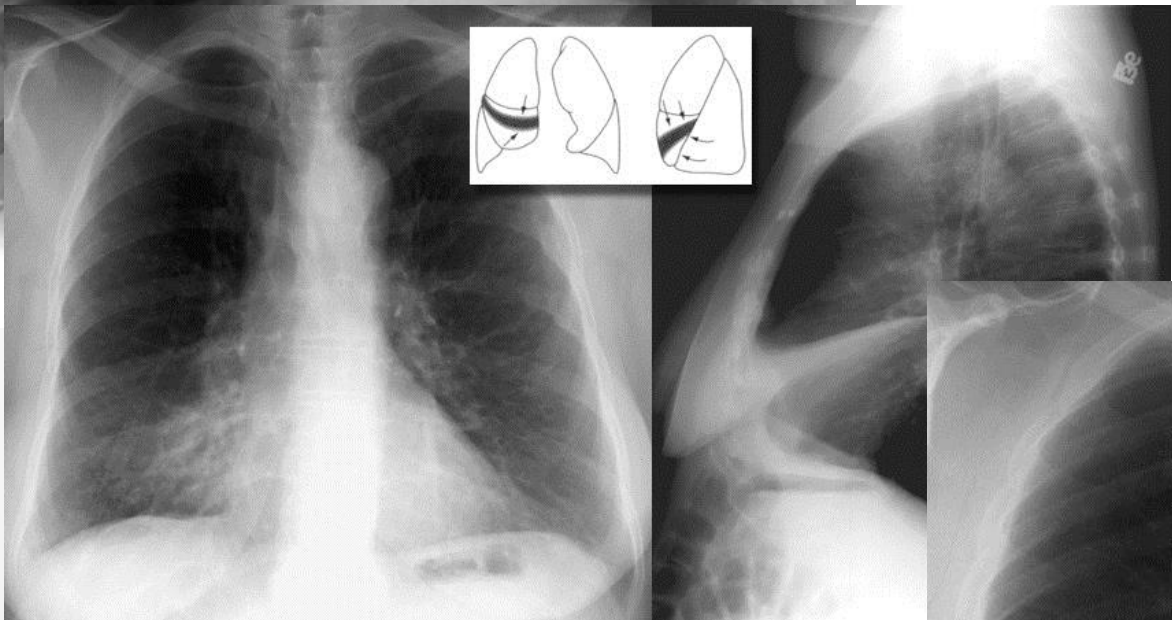
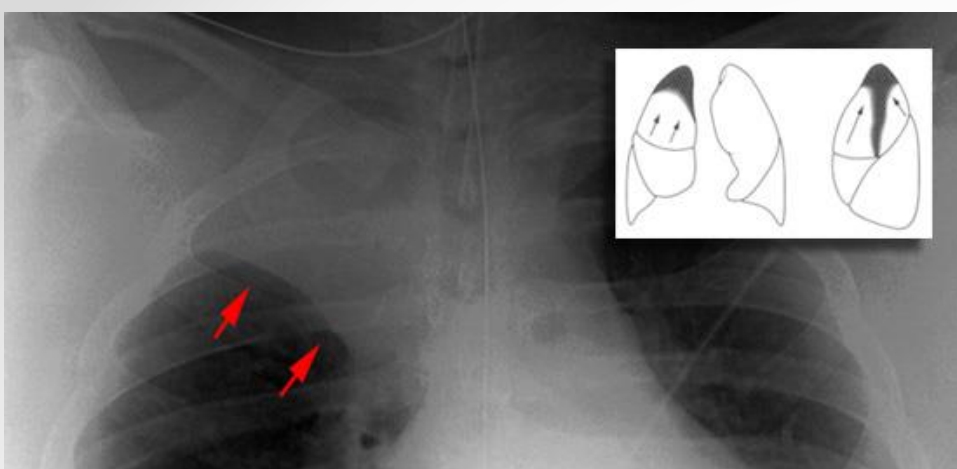
Lobe



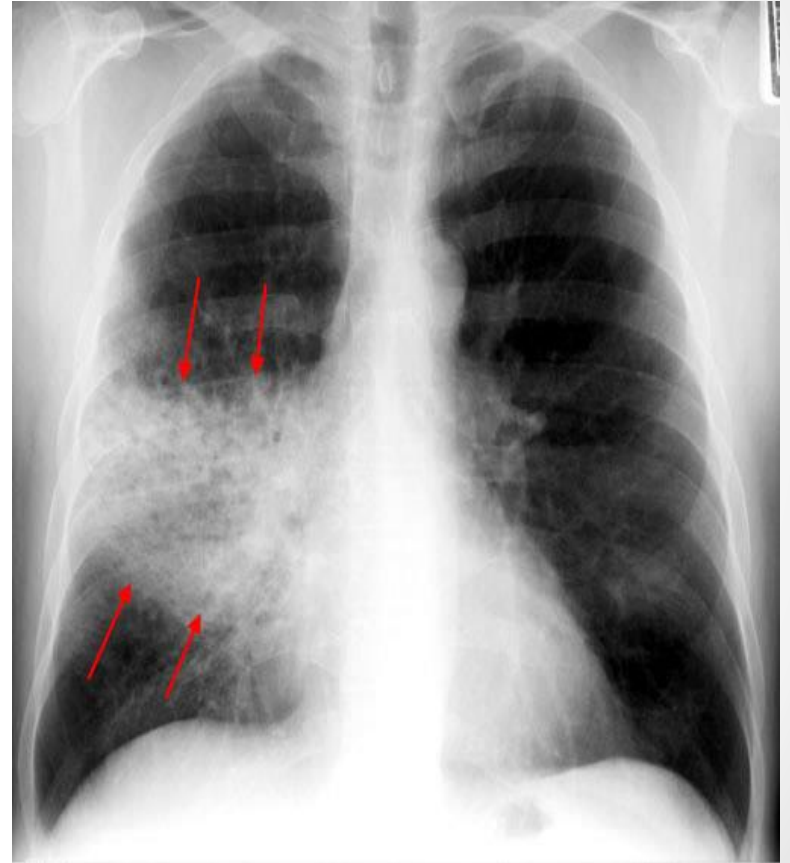
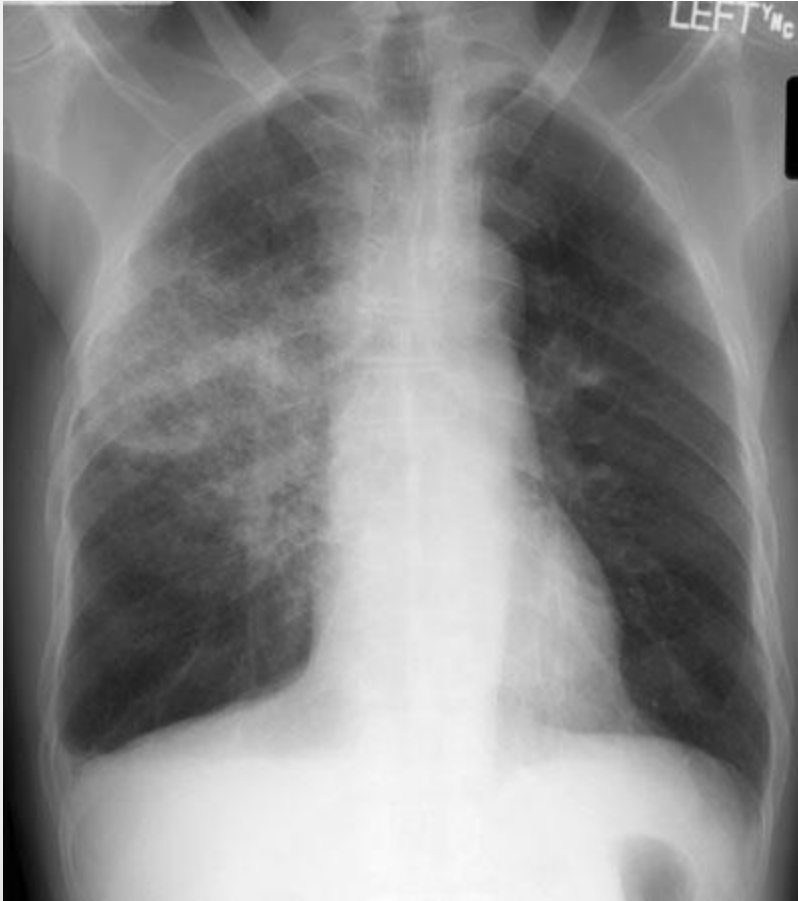
Atelectasis – LUL, LLL



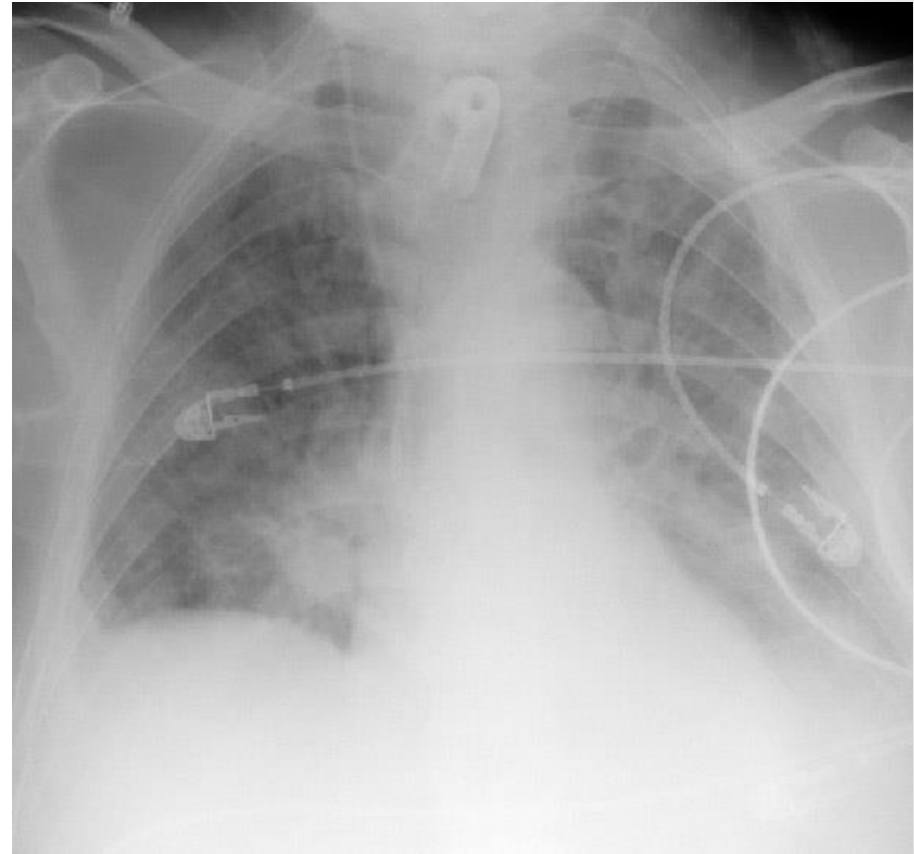
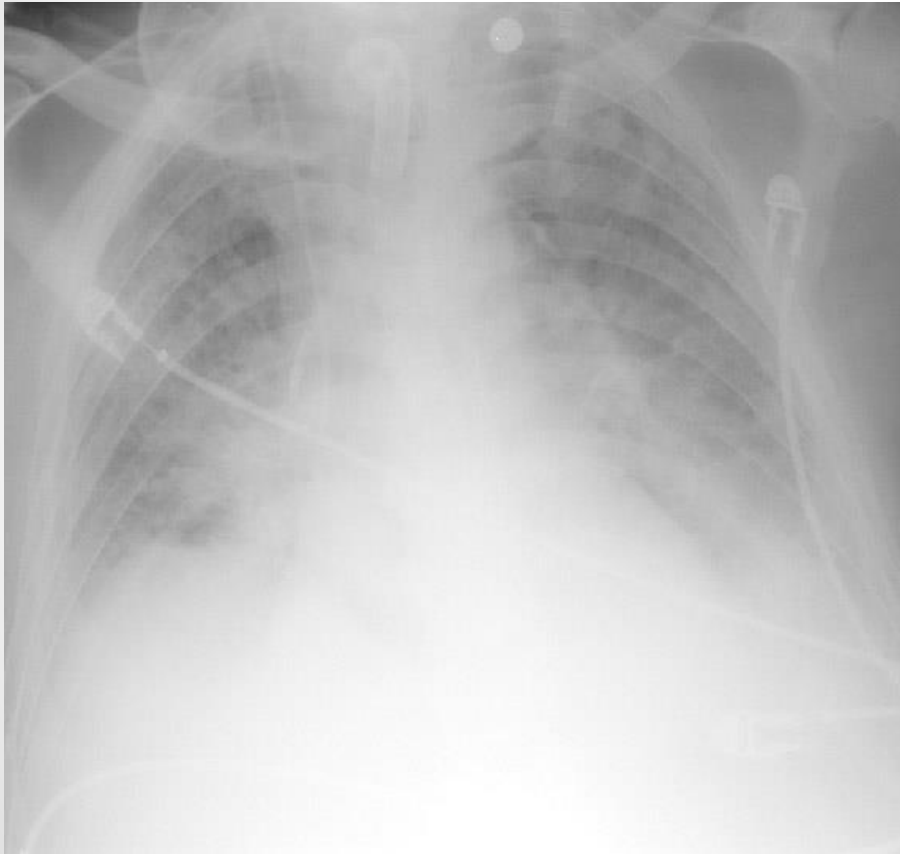
UL, RML, RLL



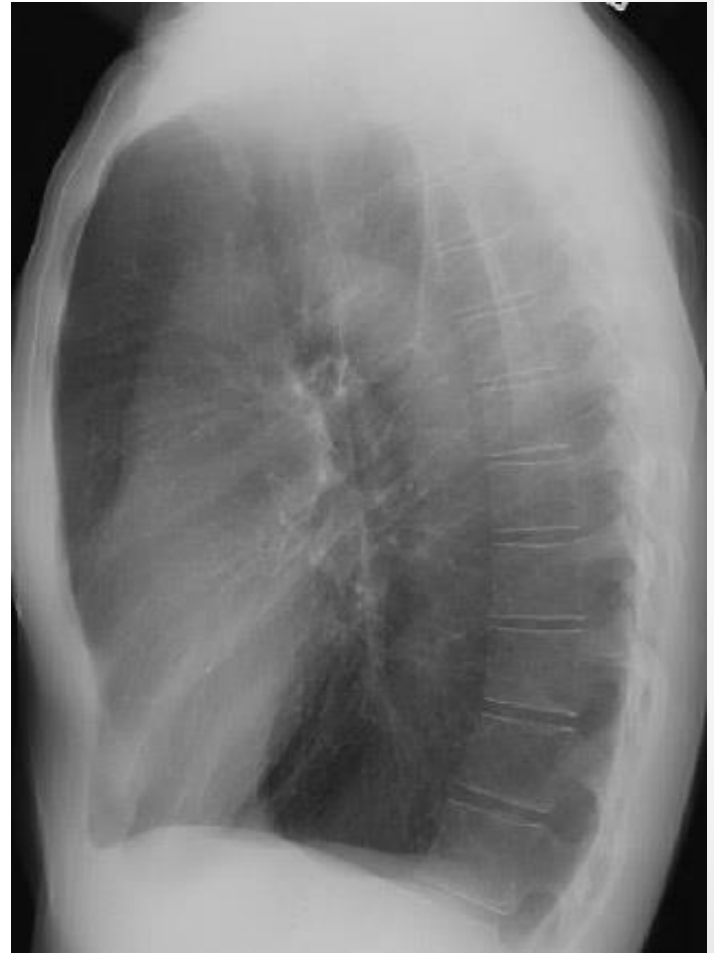
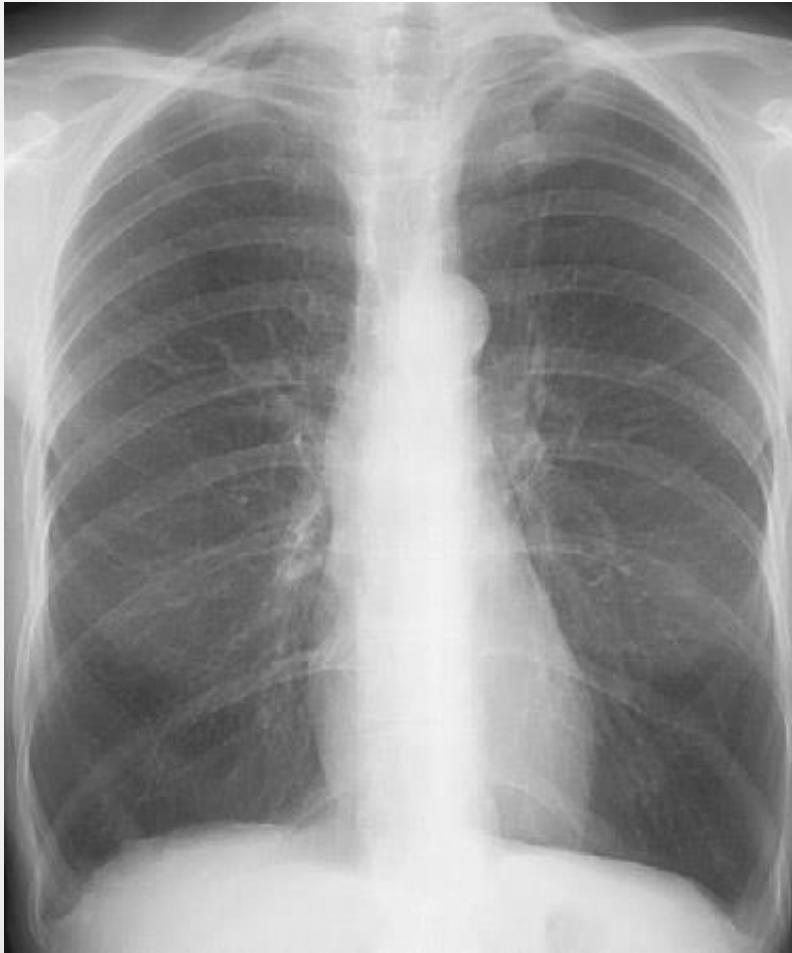Pneumonia

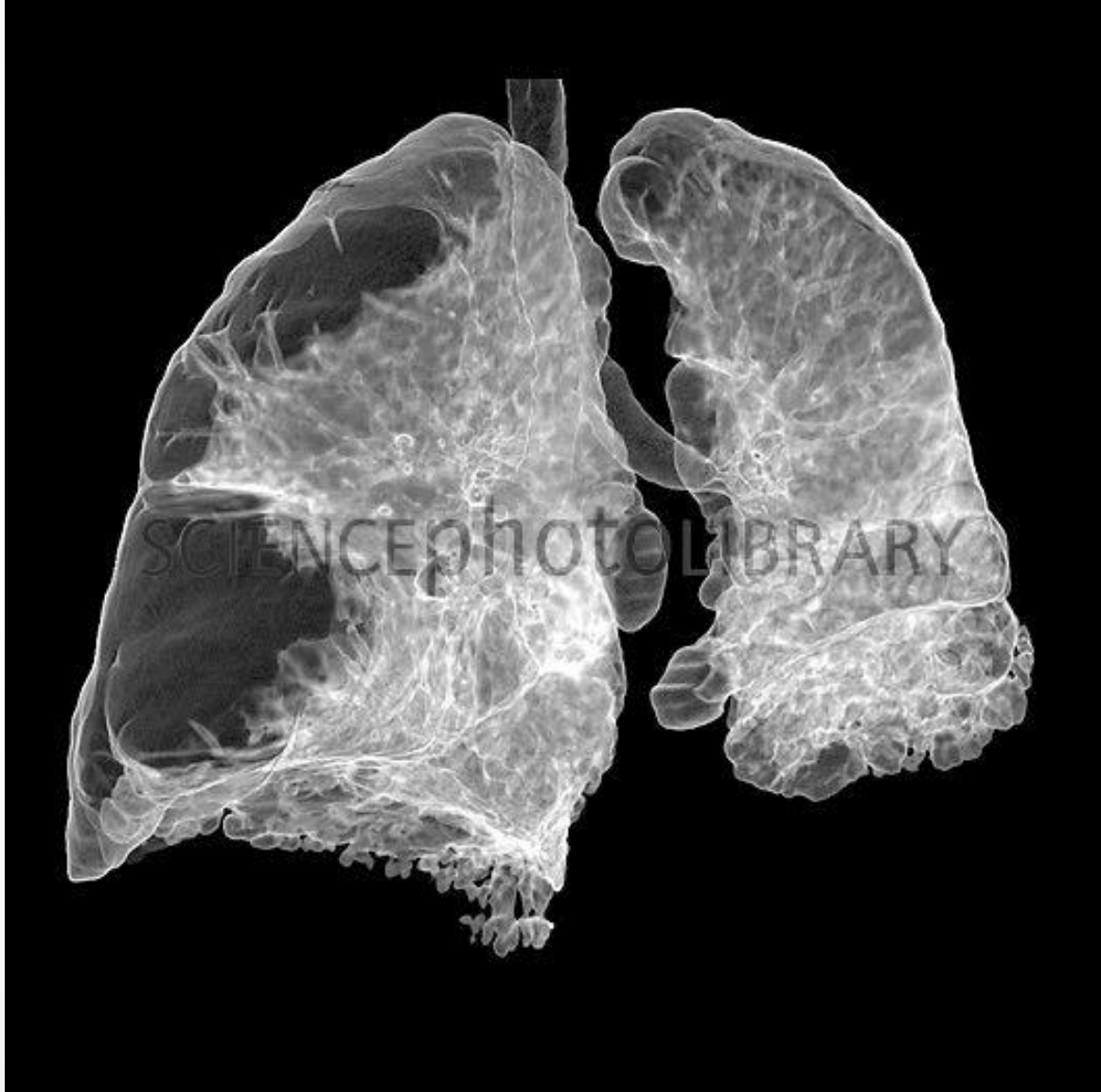


Pulmonary Edema



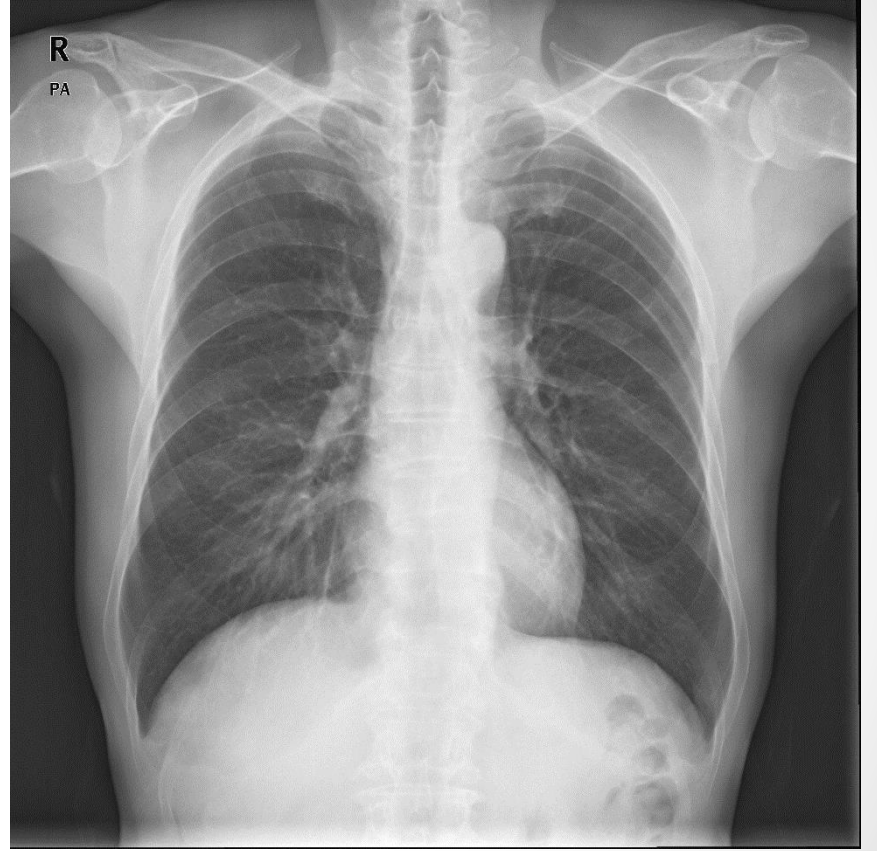
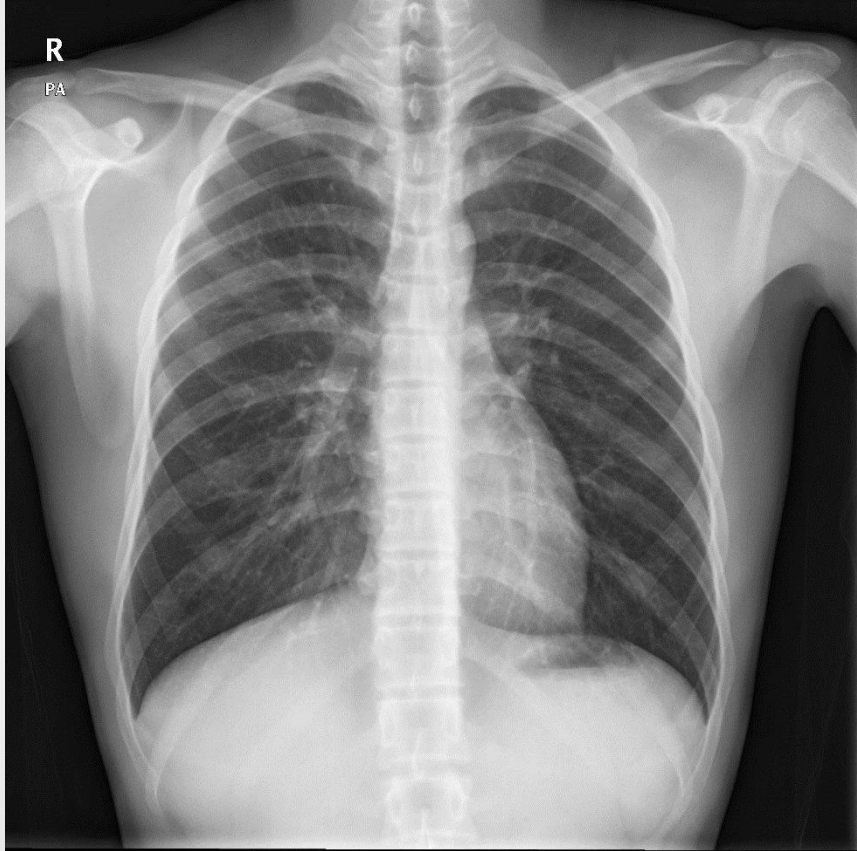Emphysema





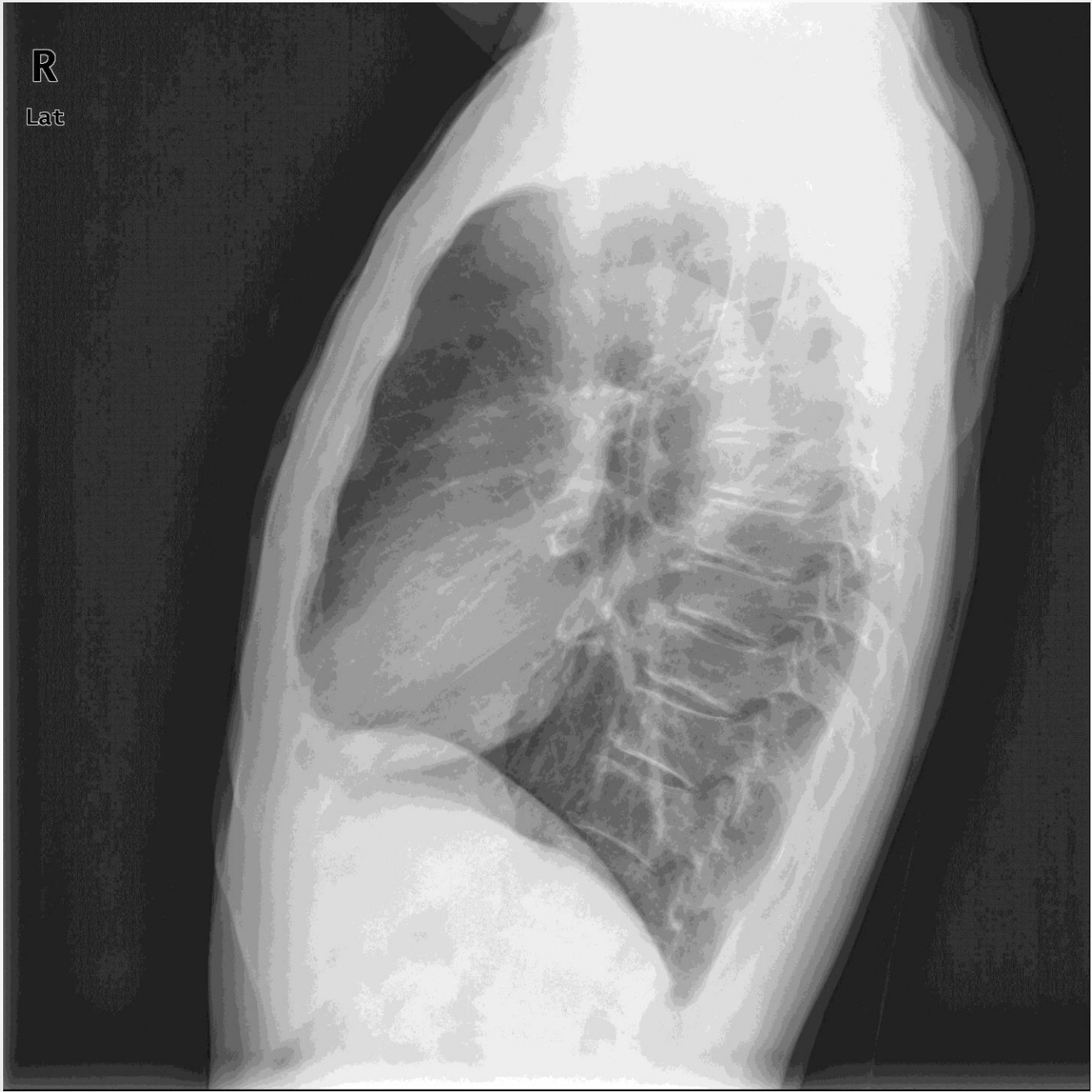chapter 4 Mediastinum

- Anterior mediastinal mass
- Pneumomediastinum
- Pericardial effusion

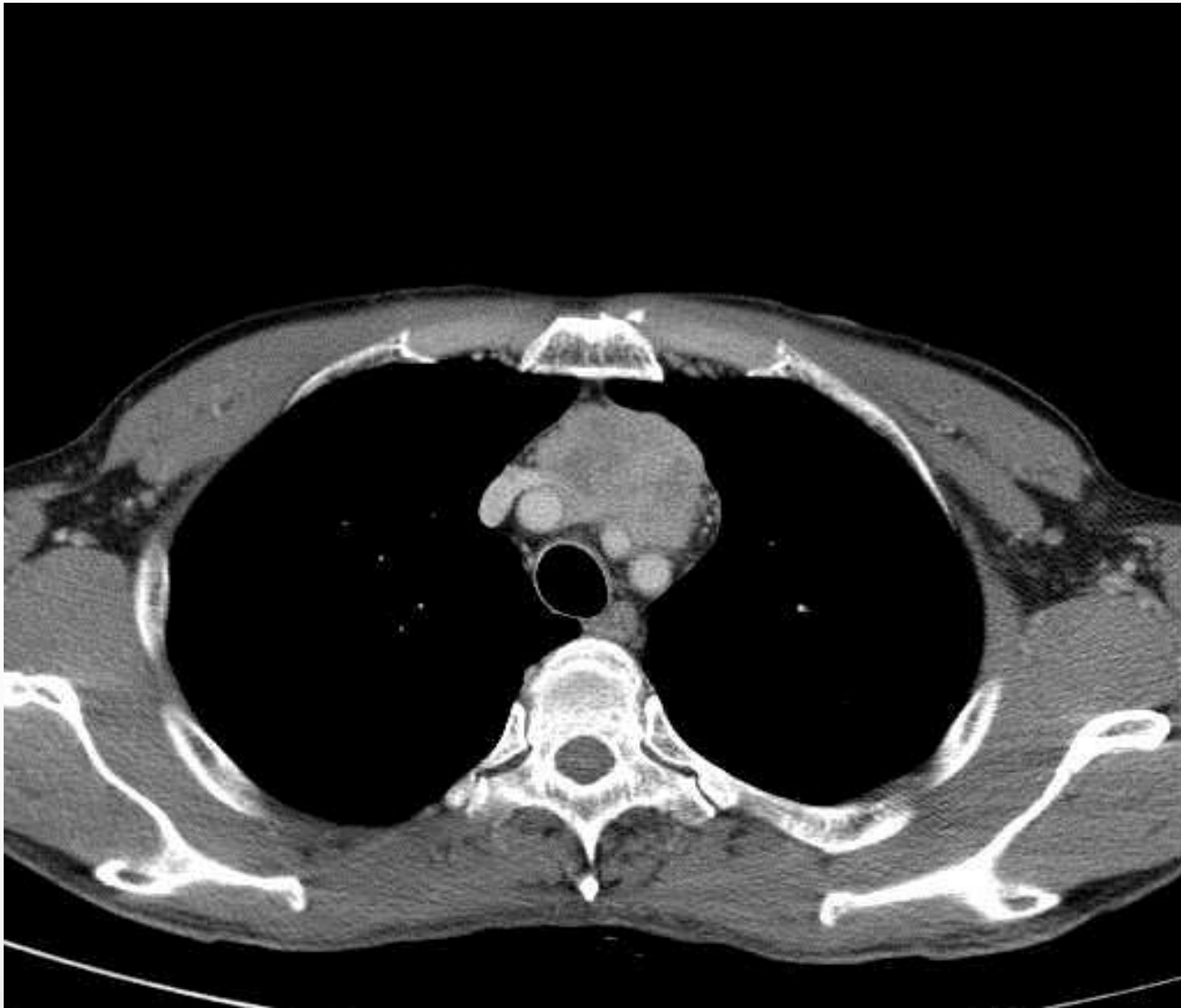


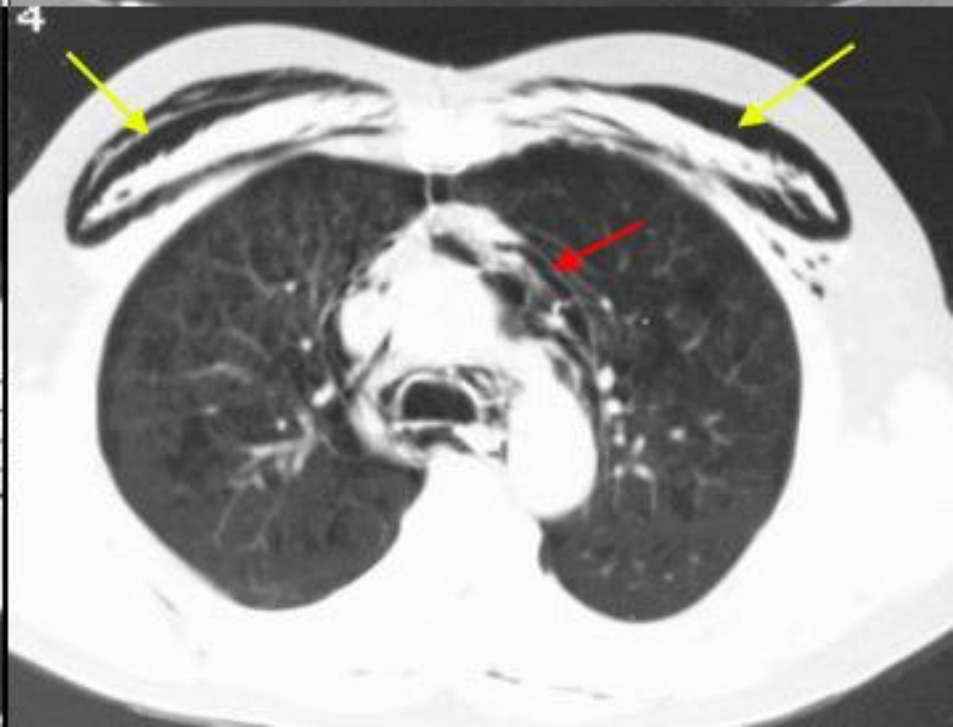
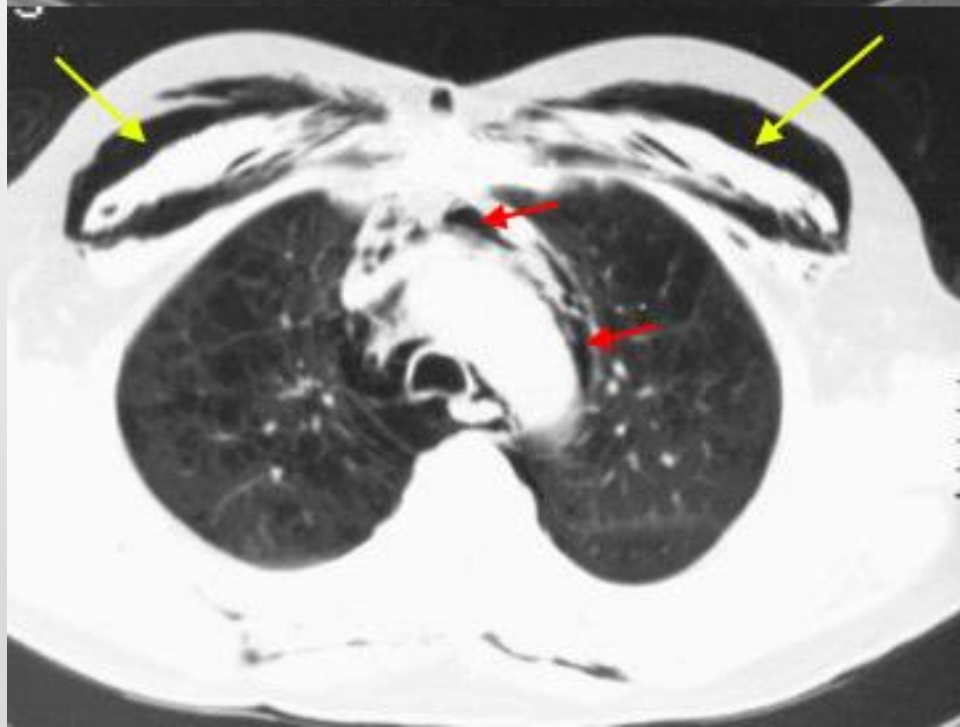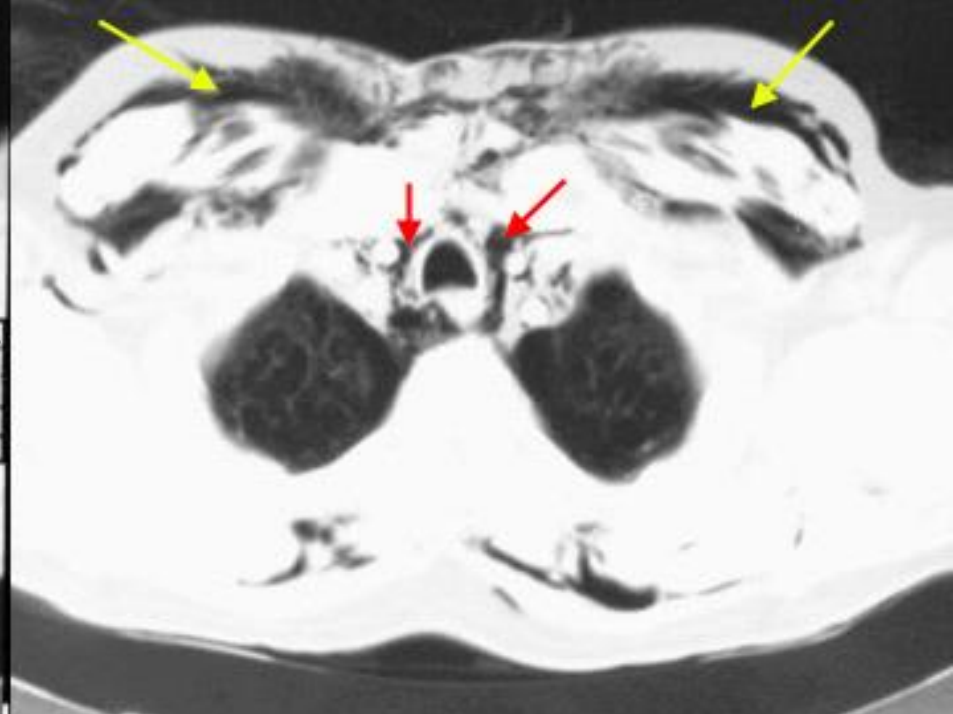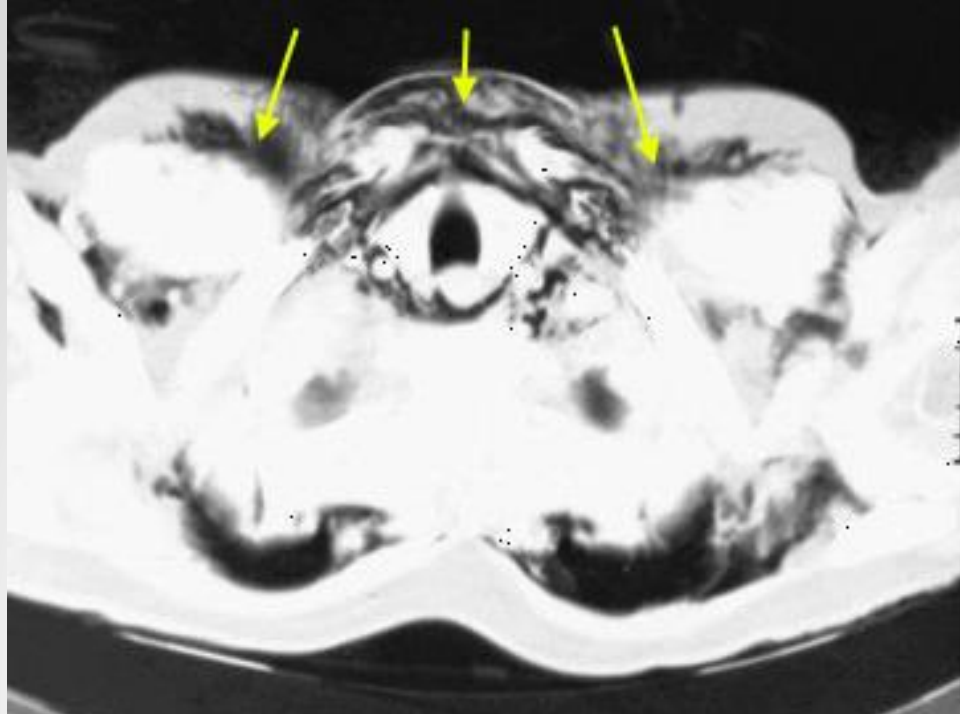
R

Lat

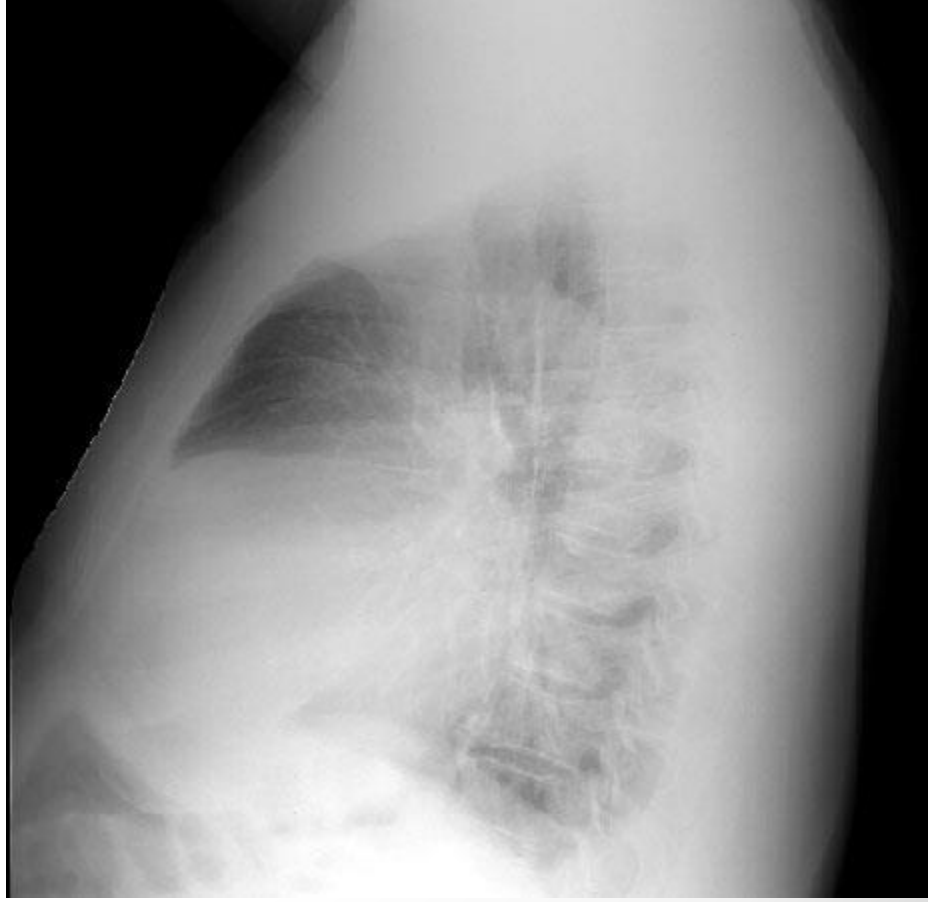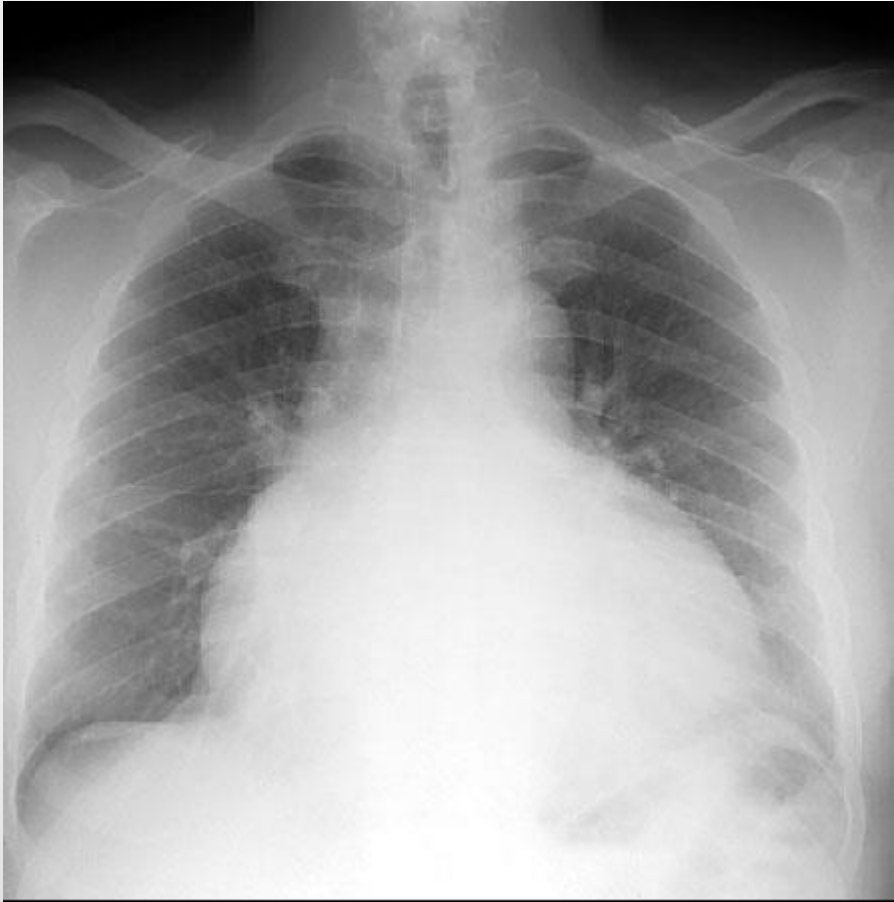


Anterior mediastinal mass

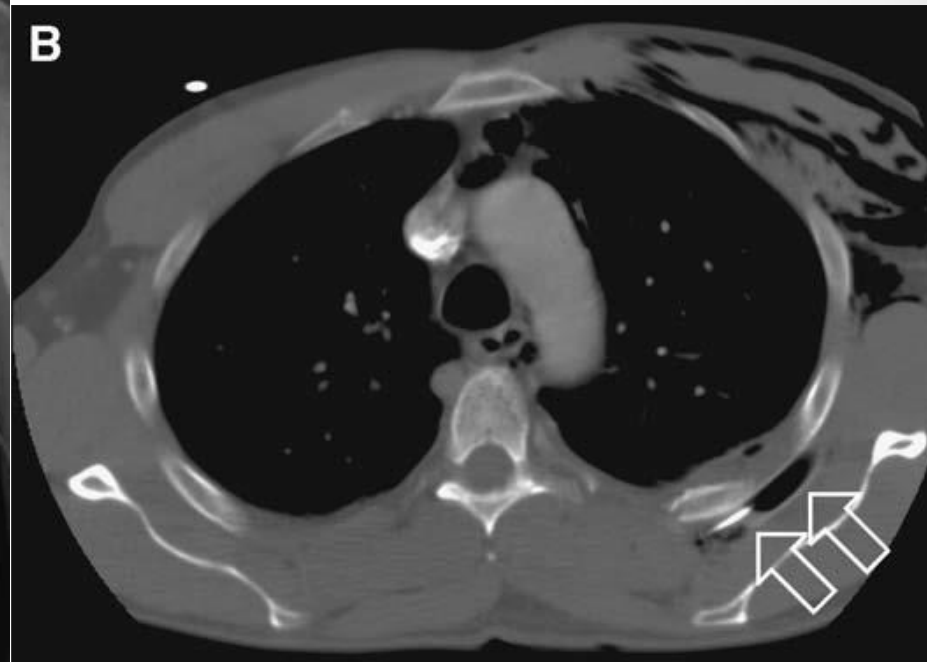
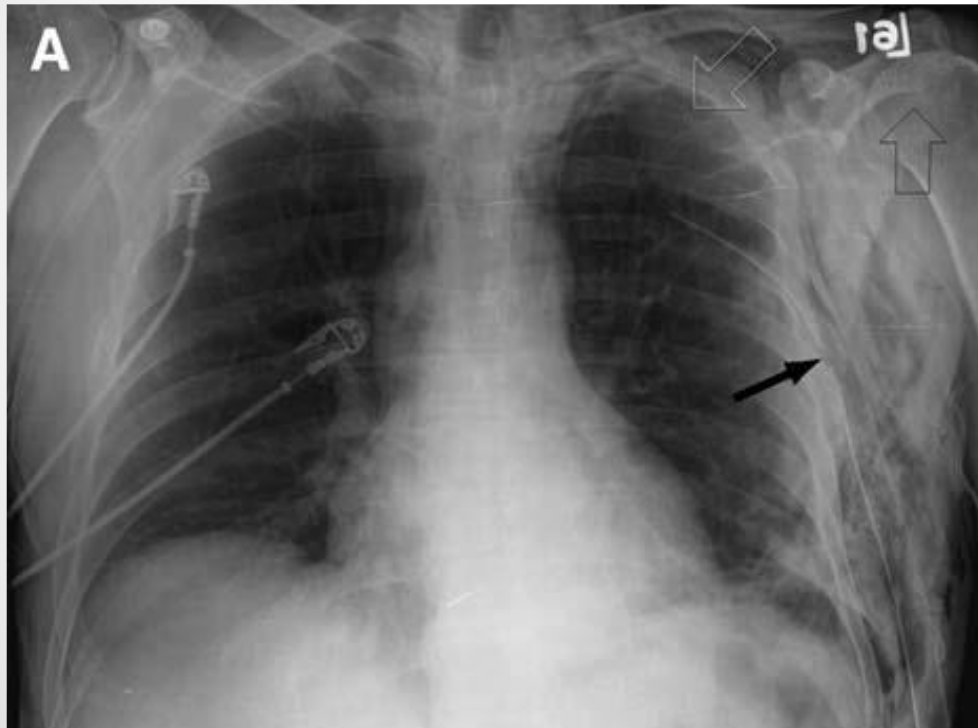




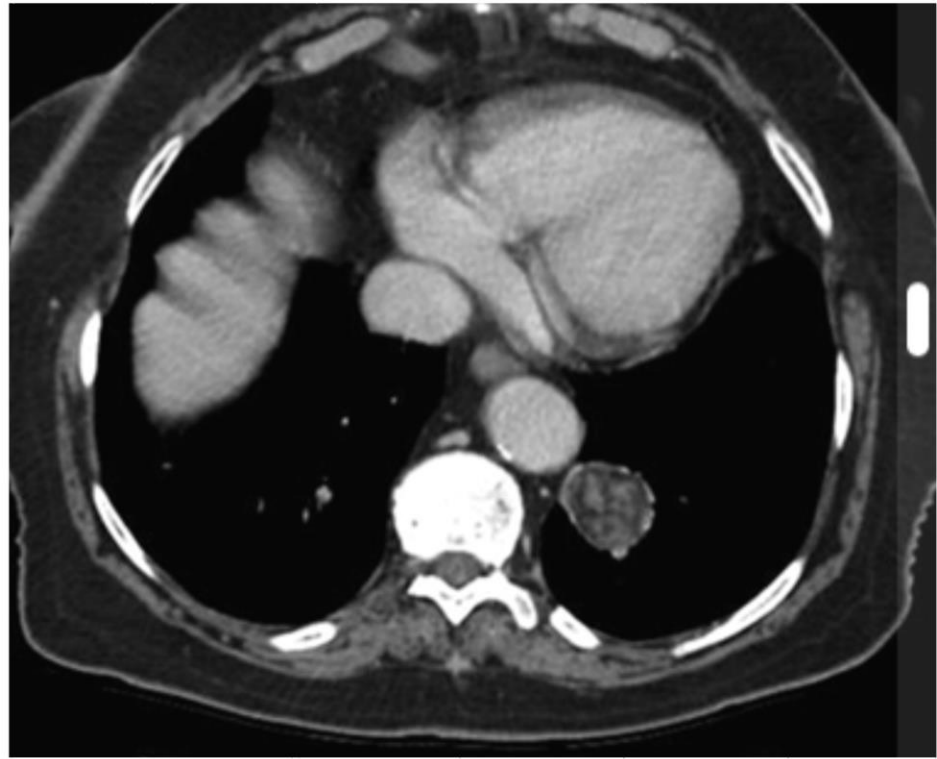
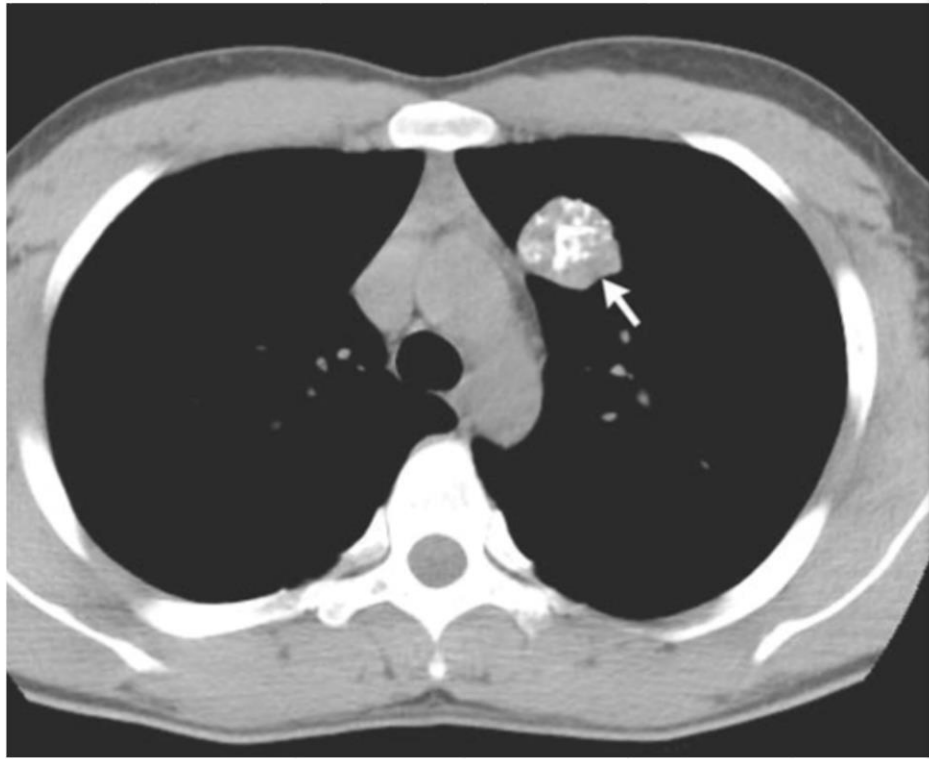
Pericardial effusion



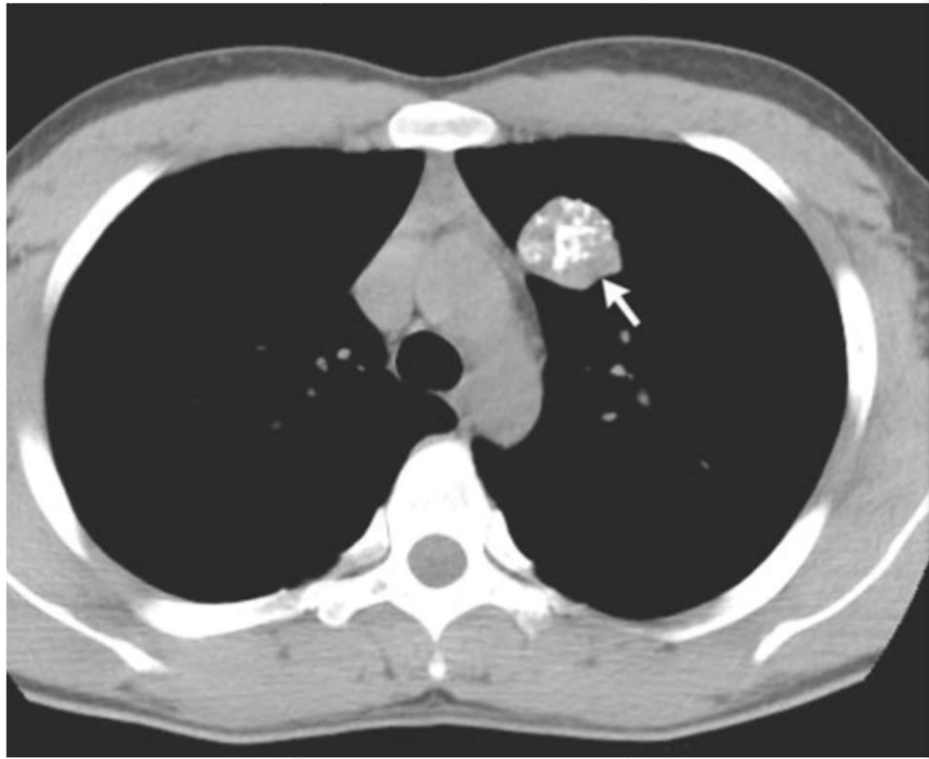
Malpositioned chest tube



“양성 혹”을 시사하는 소견들



“양성 혹”을 시사하는 소견들



석회화




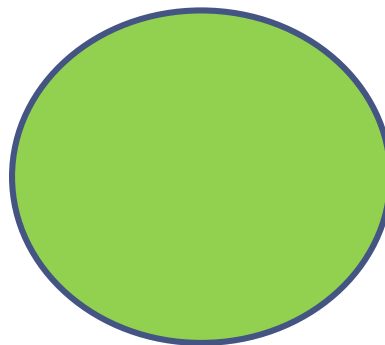

지방

“악성 흑”을 시사하는 소견 1 - 크 기

< 5 mm

5-10 mm

> 10mm





0.1-1%

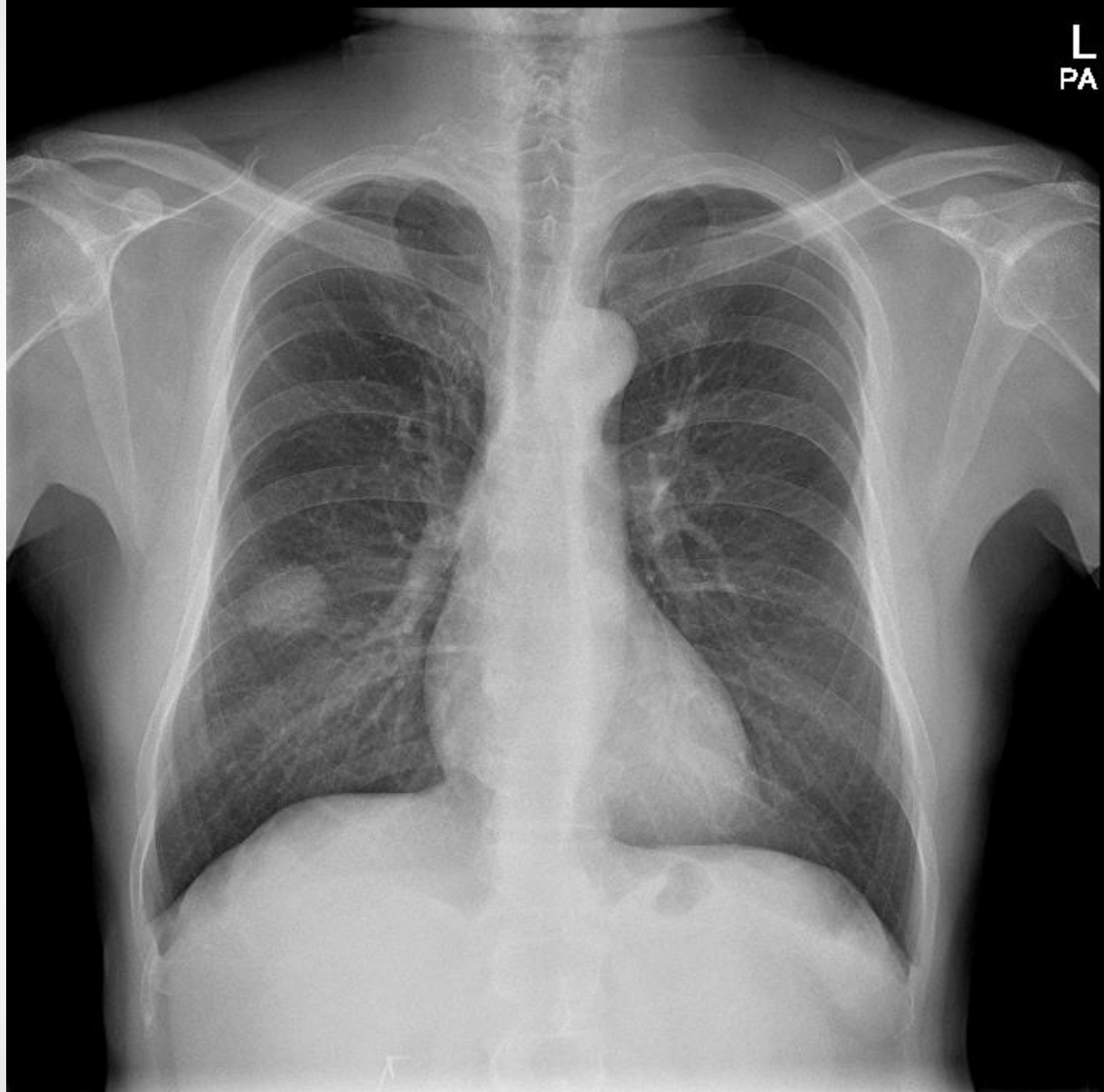
1-30%

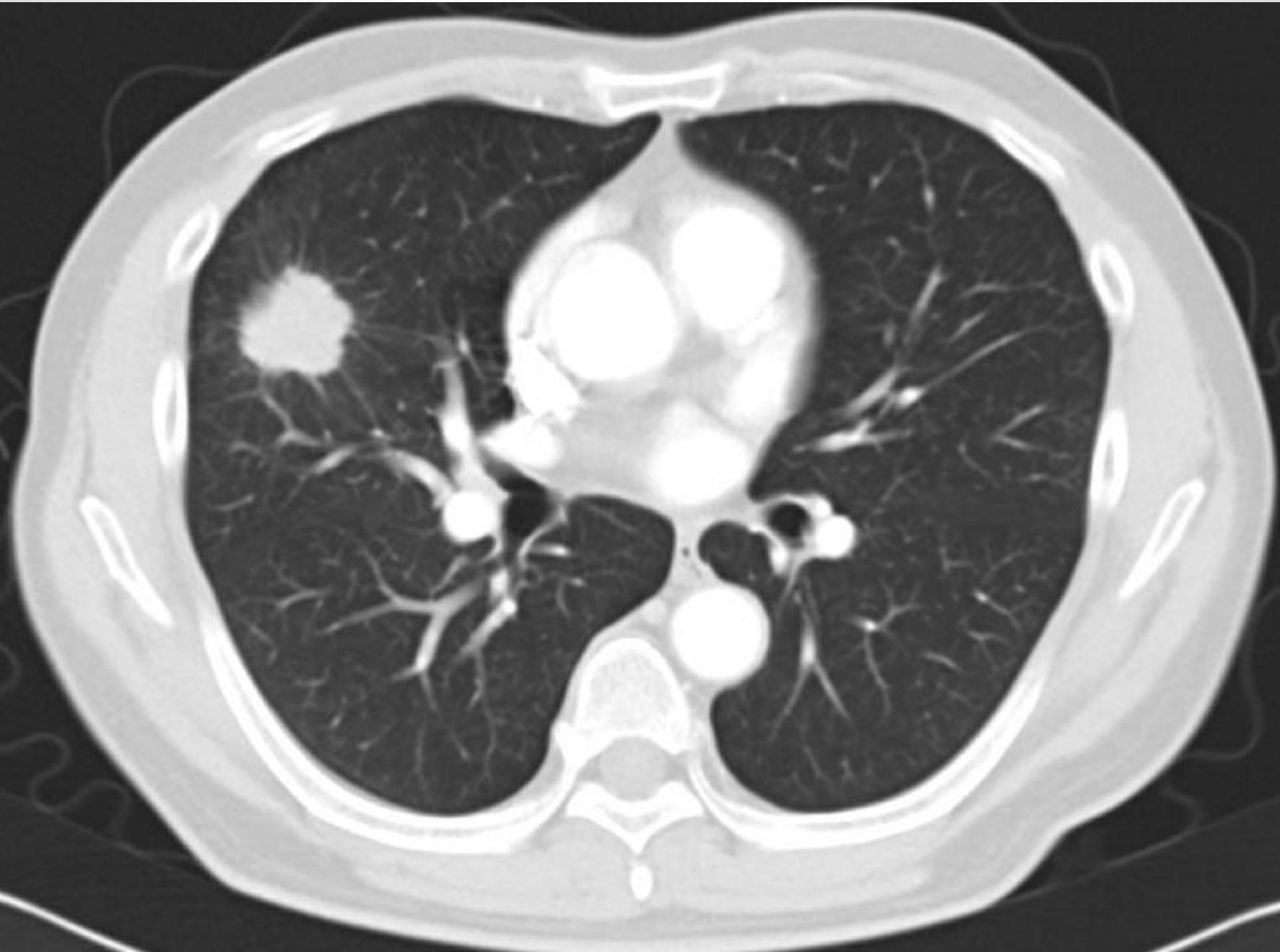30-80%

“악성 흑”을 시사하는 소견 2 - 모 양

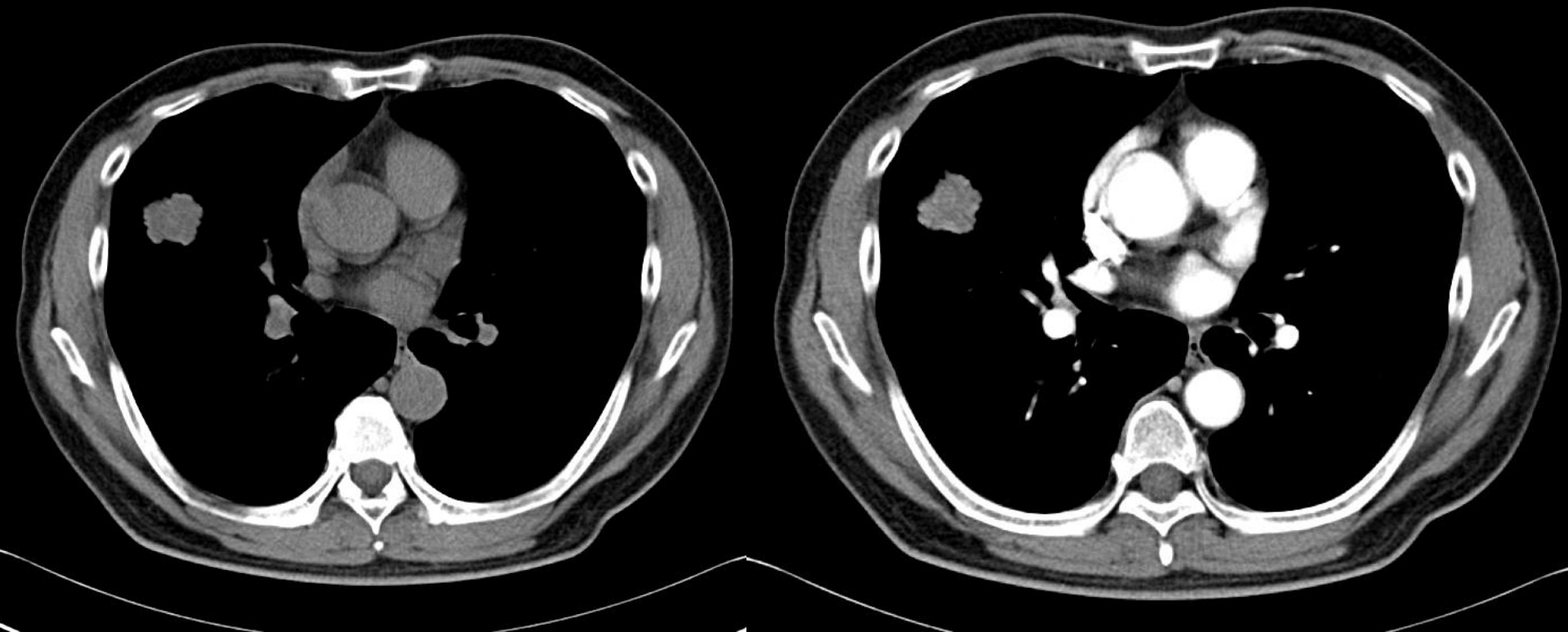


L
PA

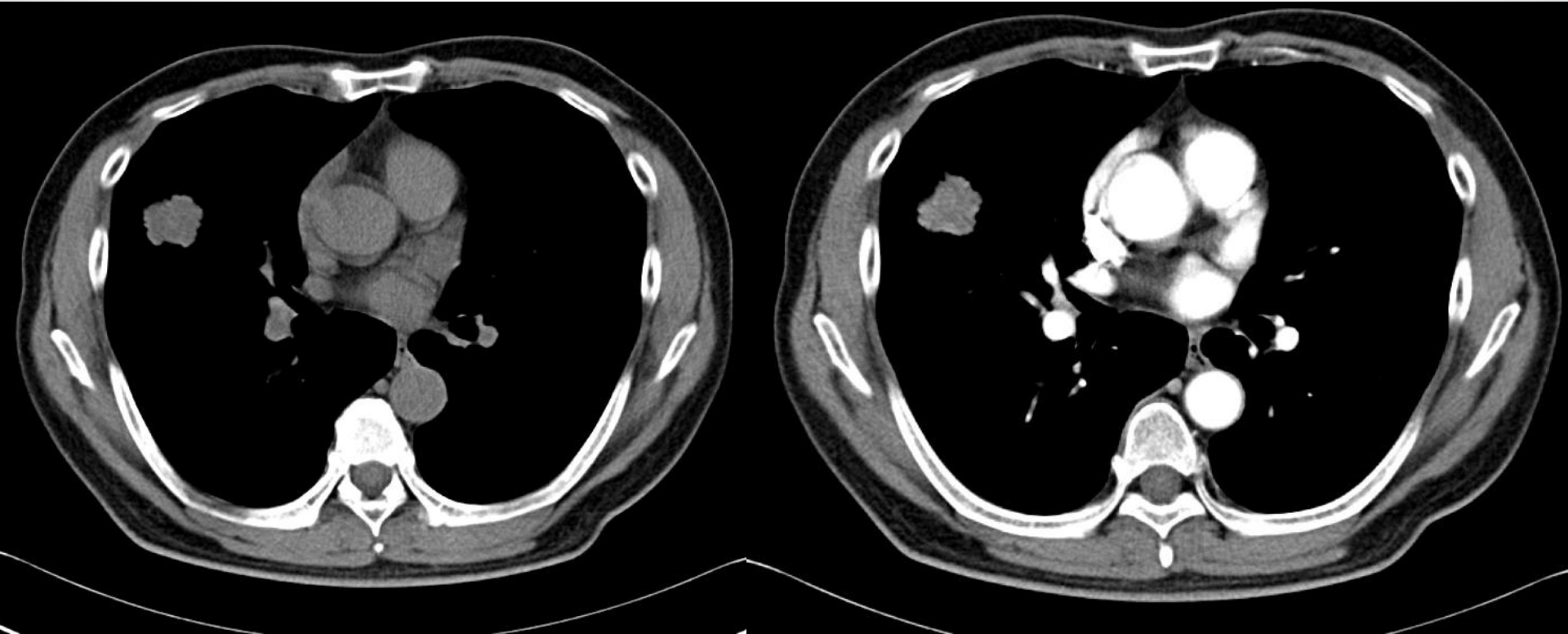




차이를 찾아보세요

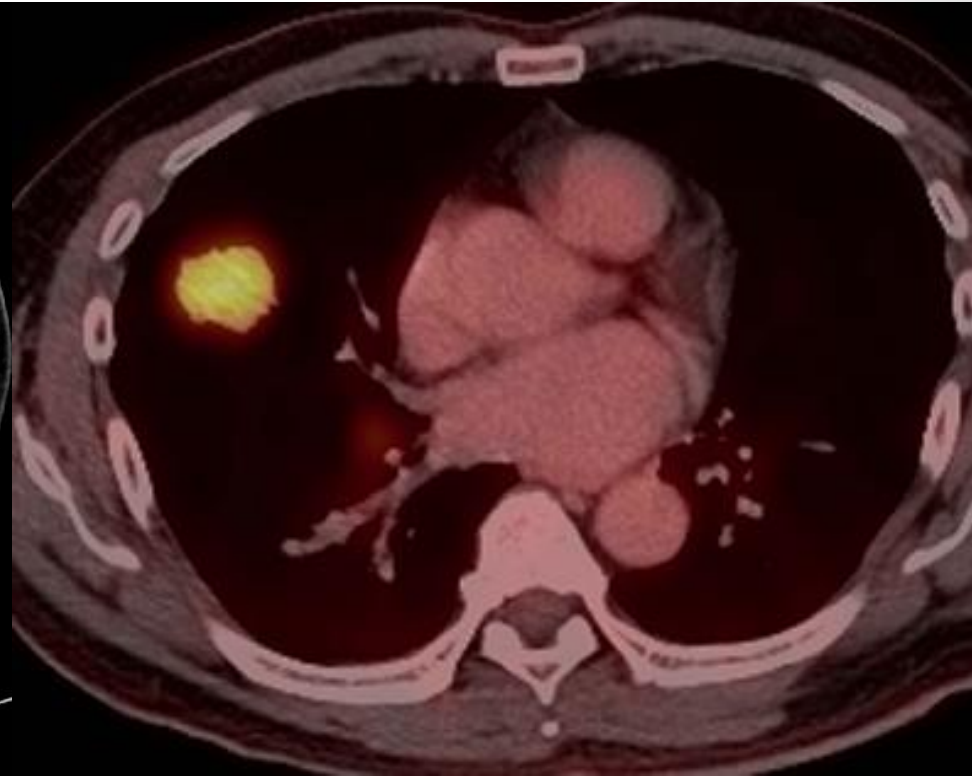
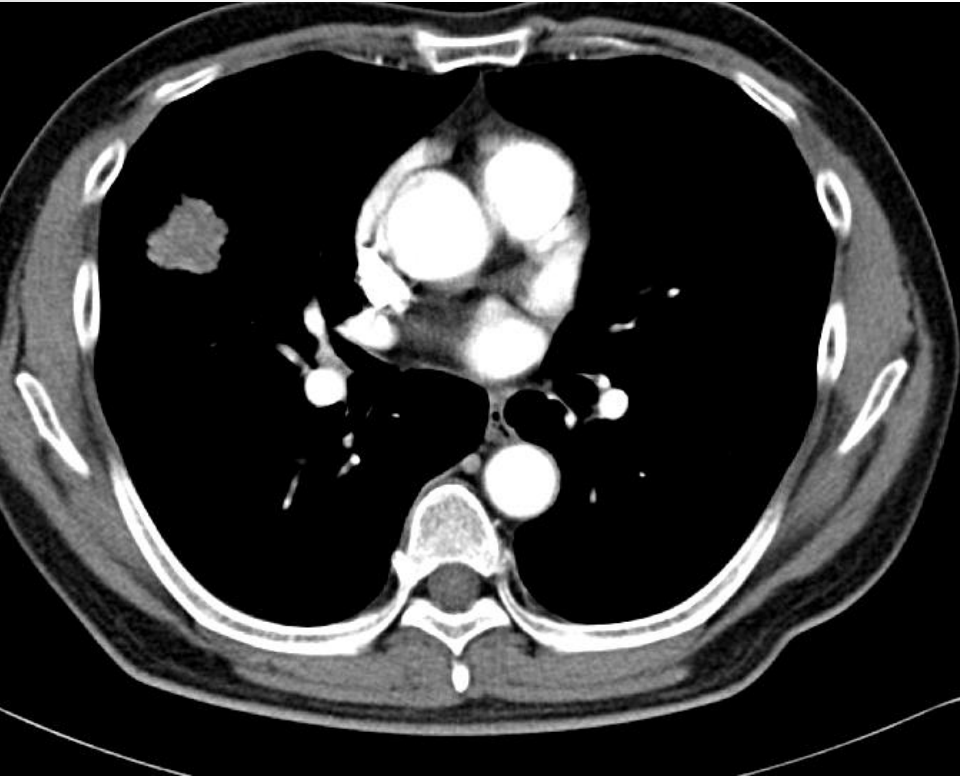


차이를 찾아보세요

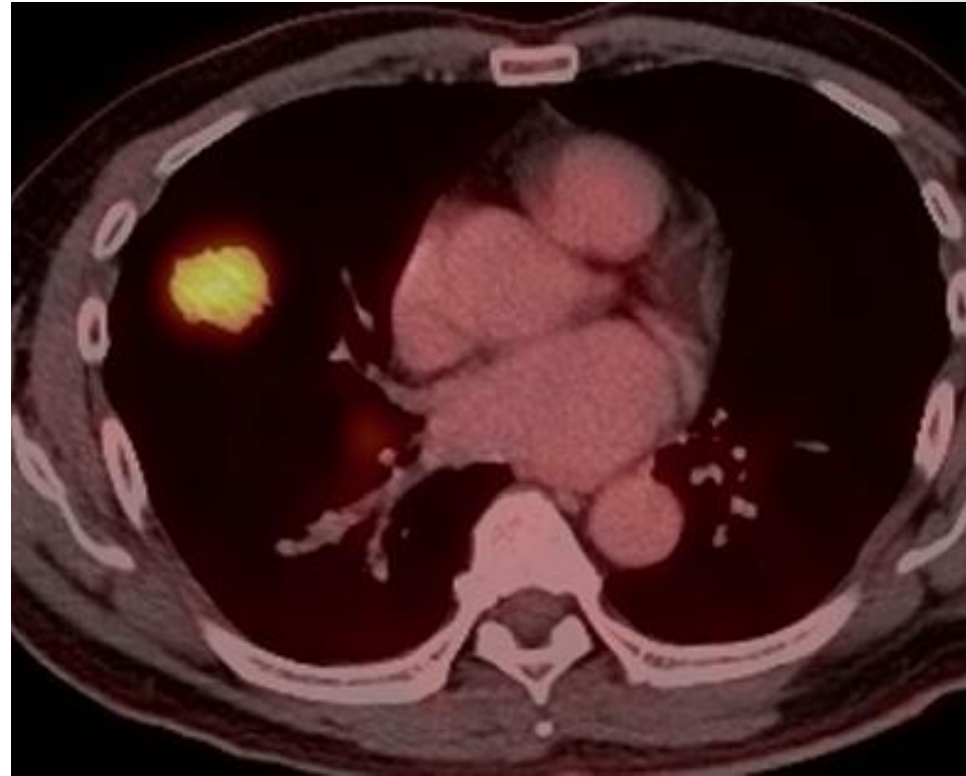
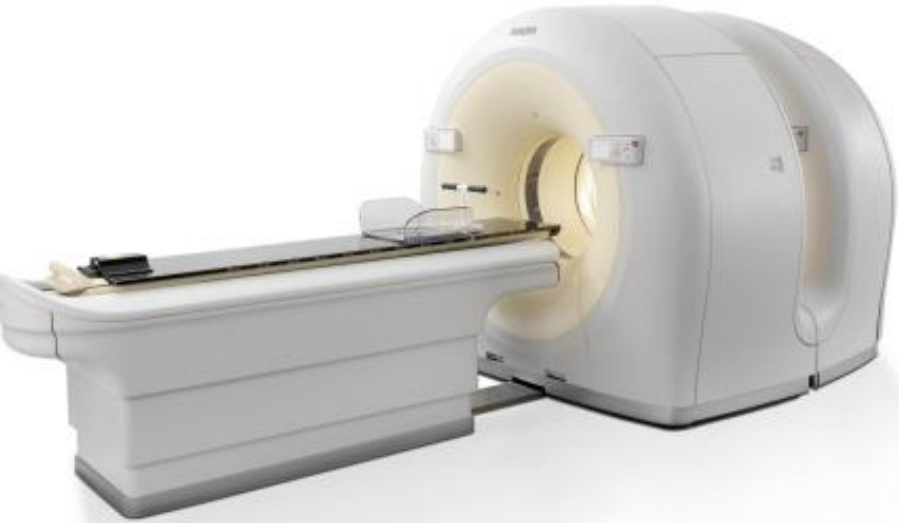


조영증강

차이를 찾아보세요

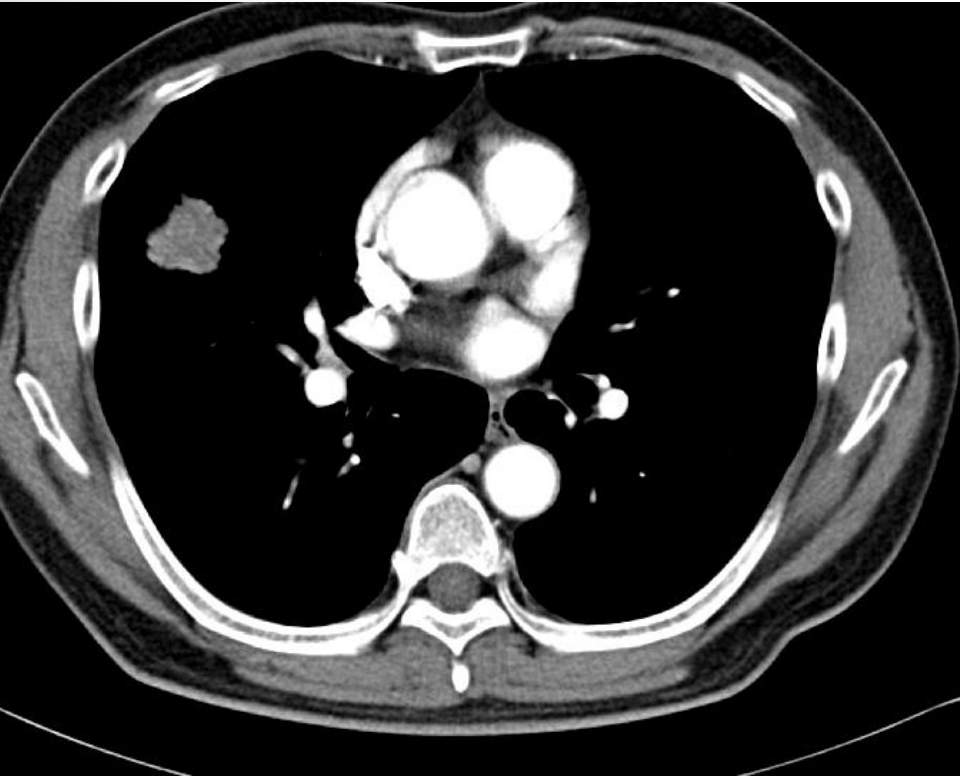


차이를 찾아보세요

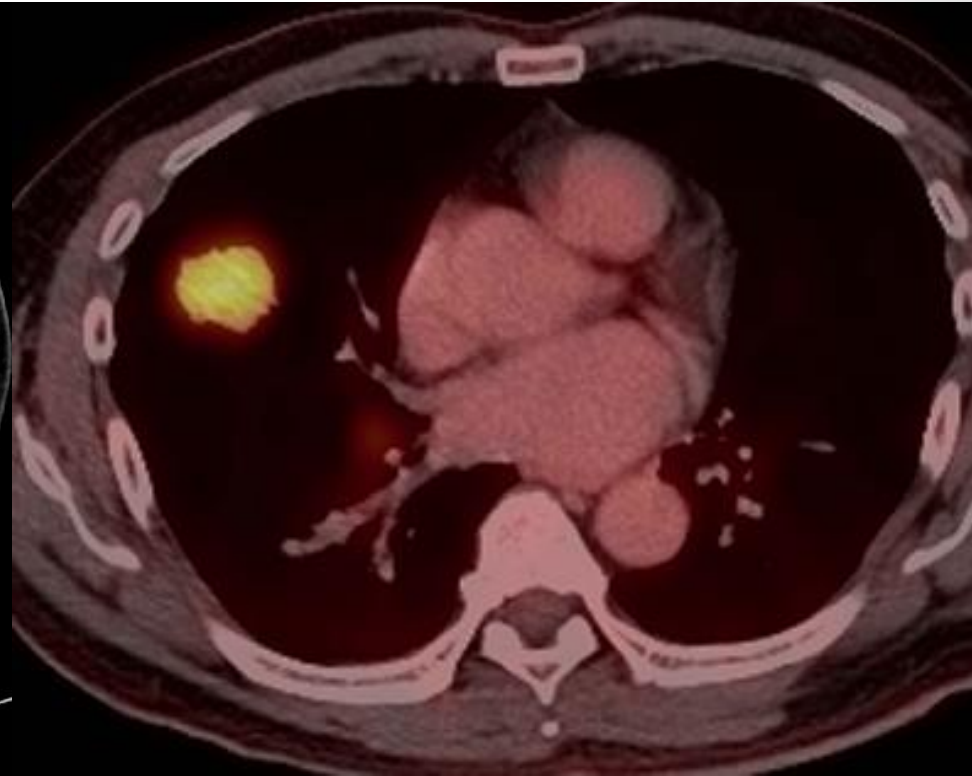


당대사

“악성 흑”을 시사하는 소견 3,4



조영증강

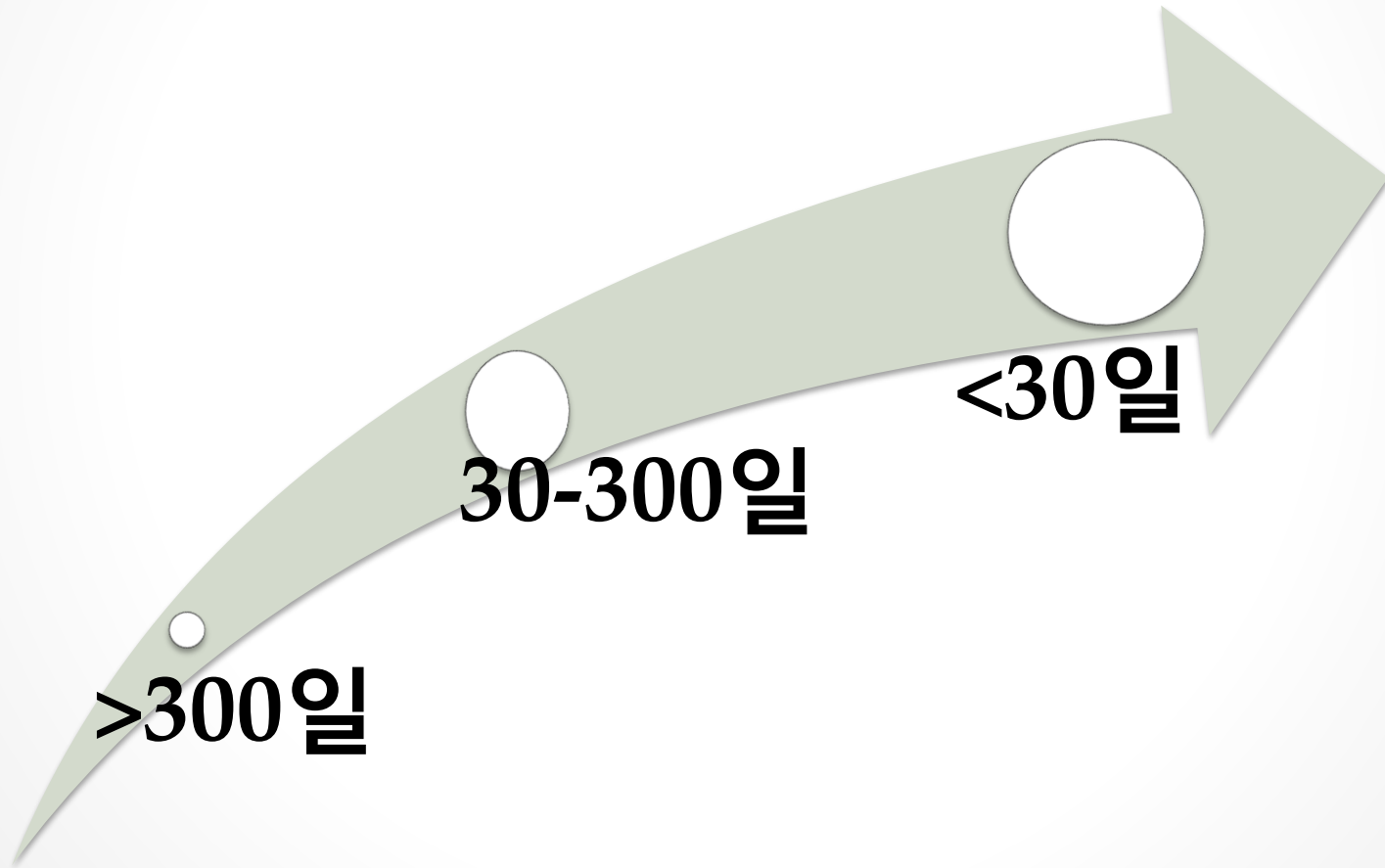


당대사



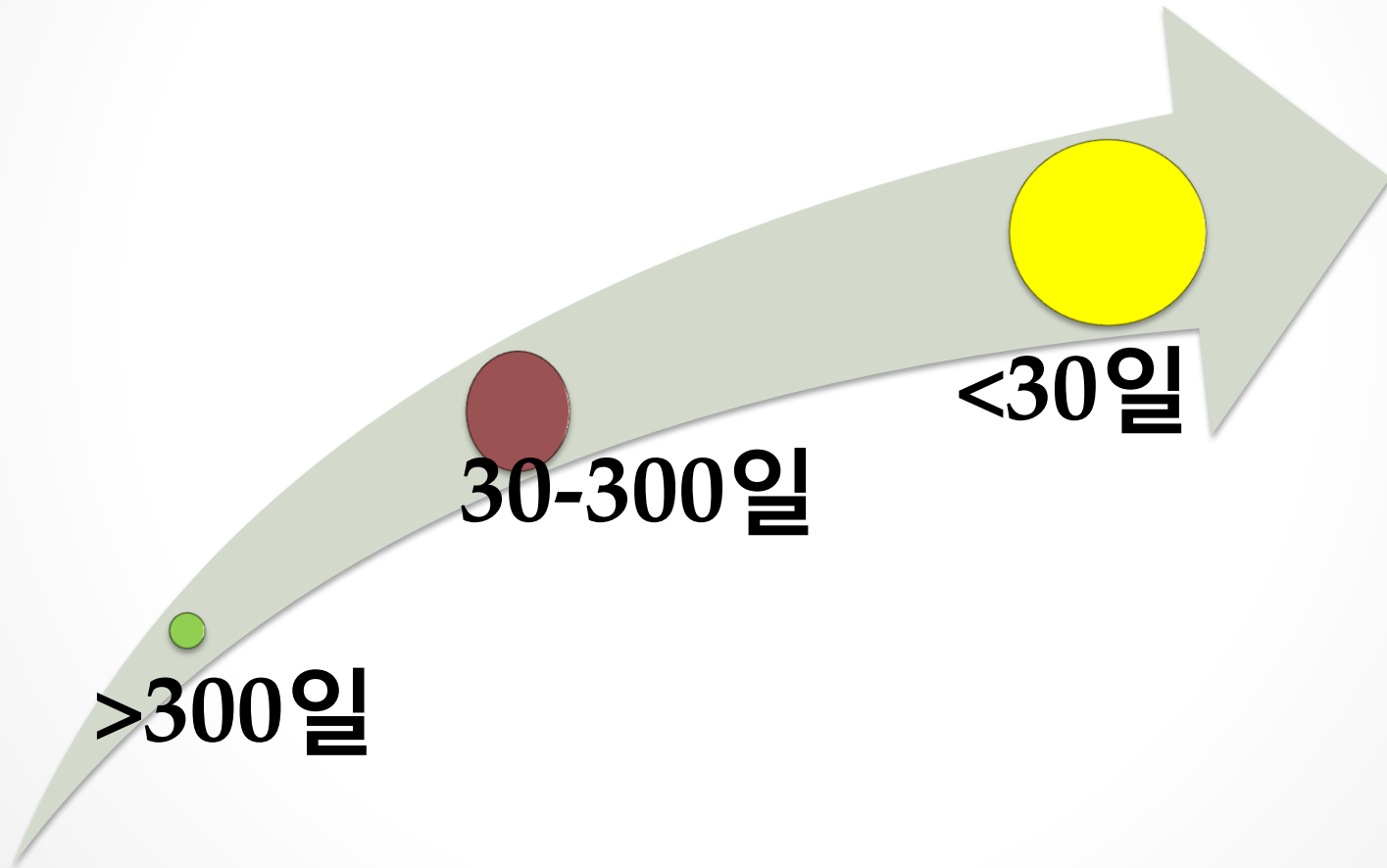
“악성 흑”을 시사하는 소견5 성장속도

- 성장속도 : 두 배 커지는 시간


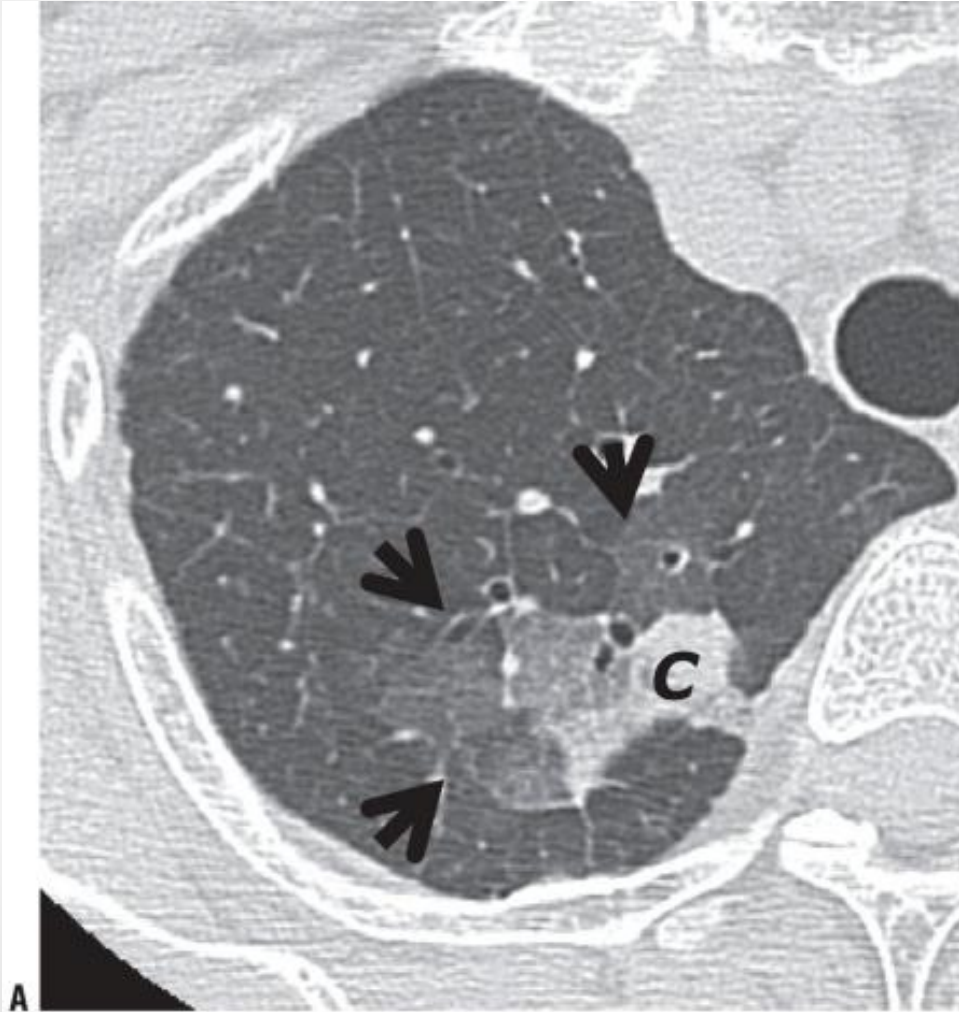


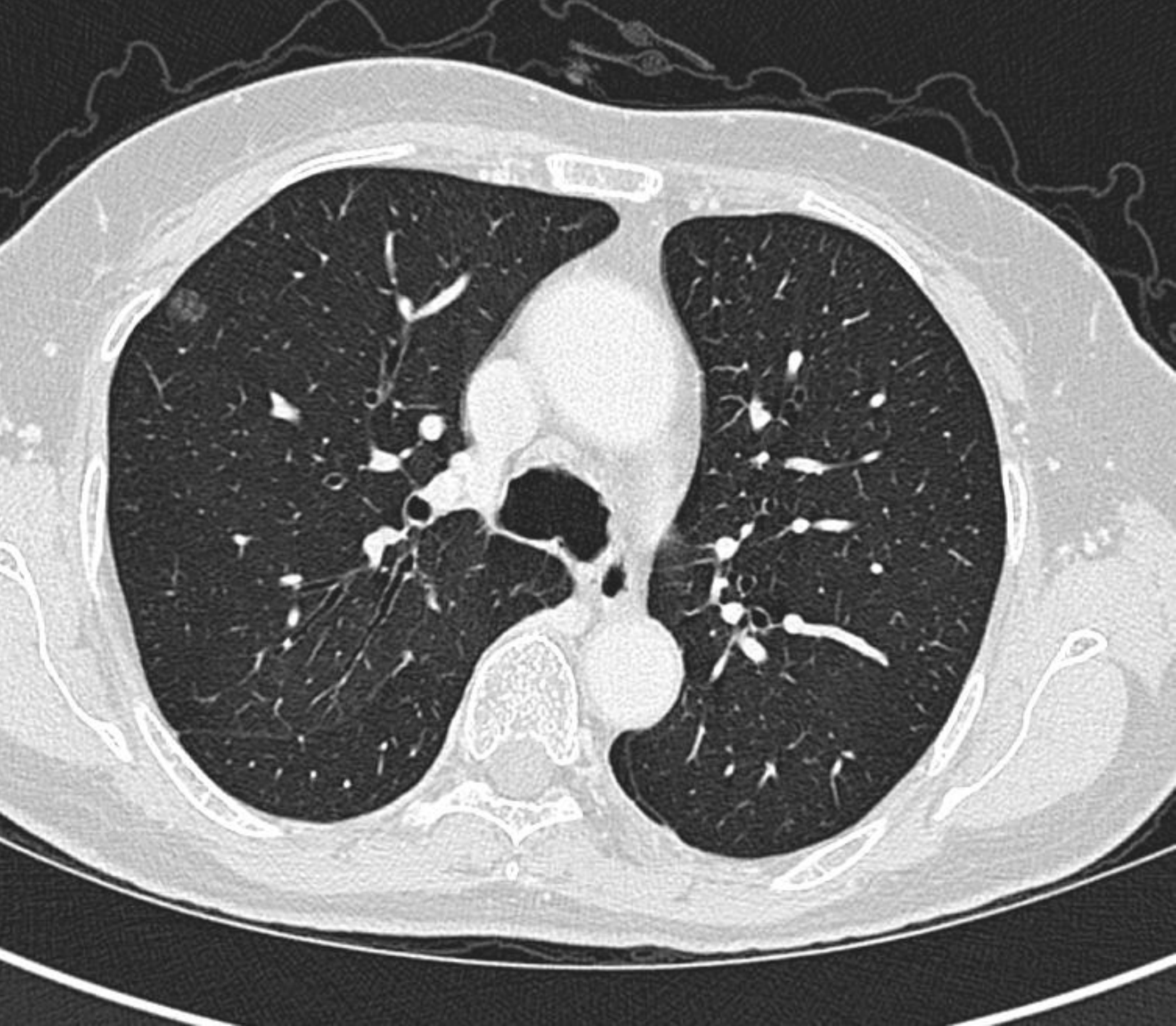
“악성 흑”을 시사하는 소견5 성장속도

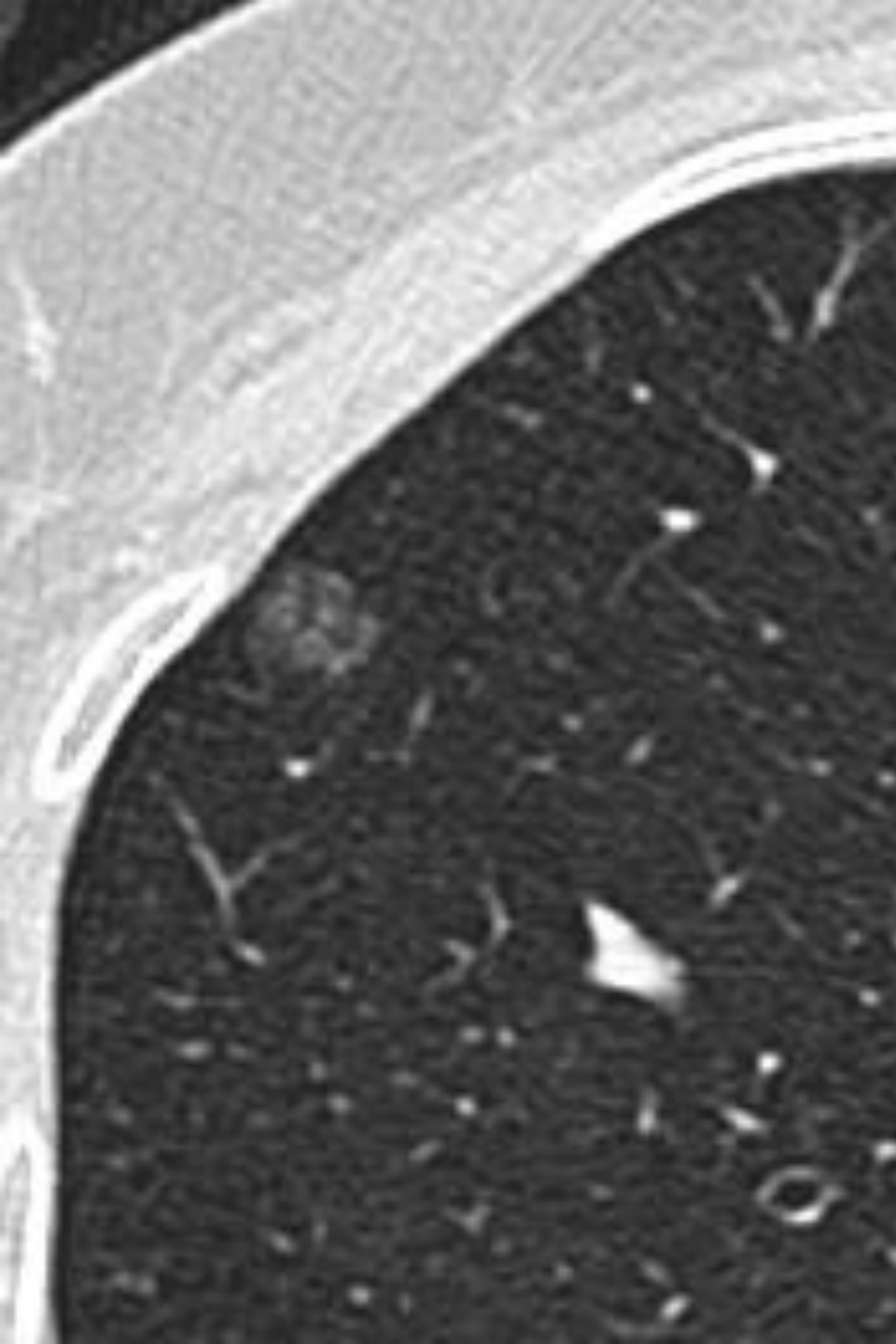
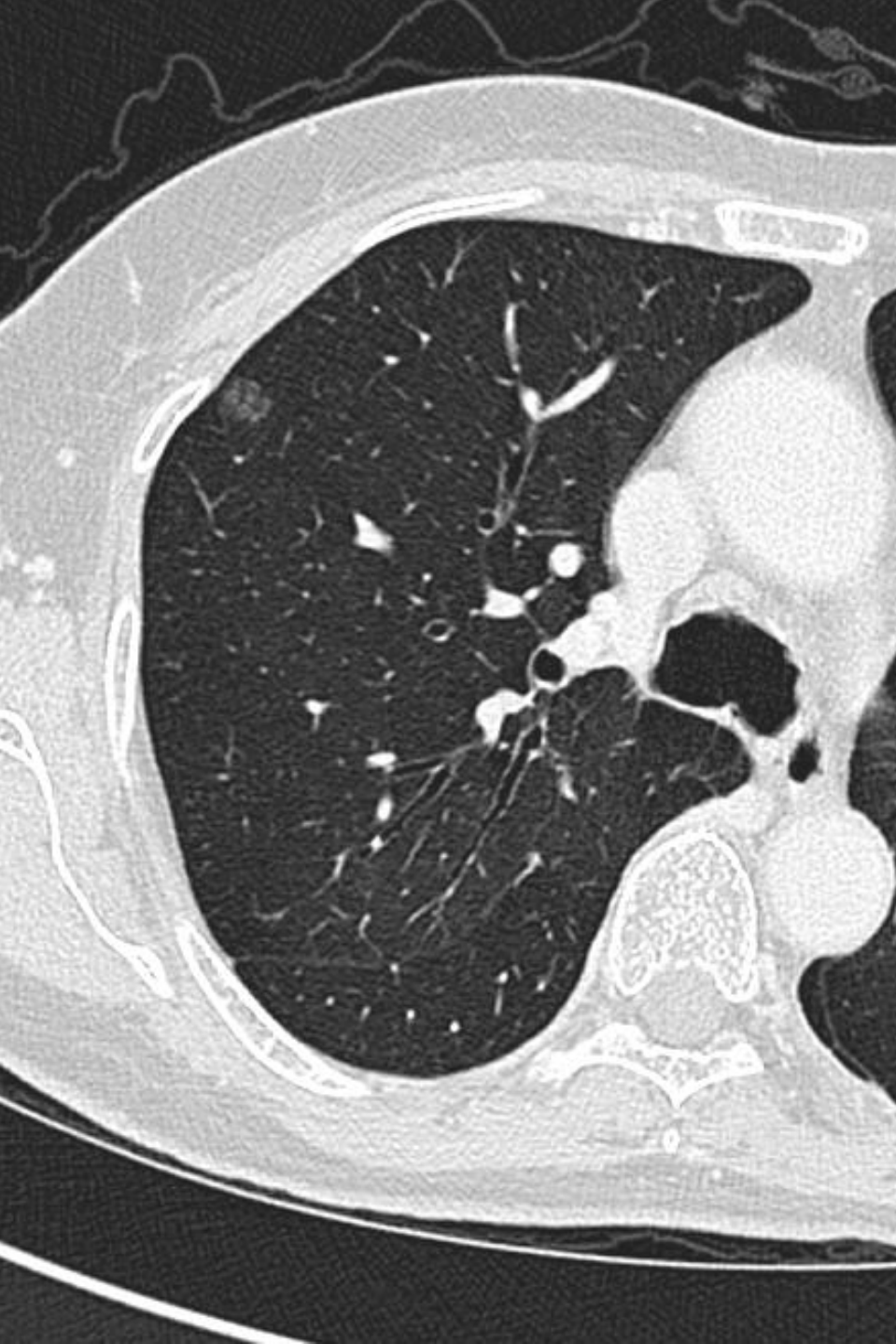- 성장속도 : 두 배 커지는 시간



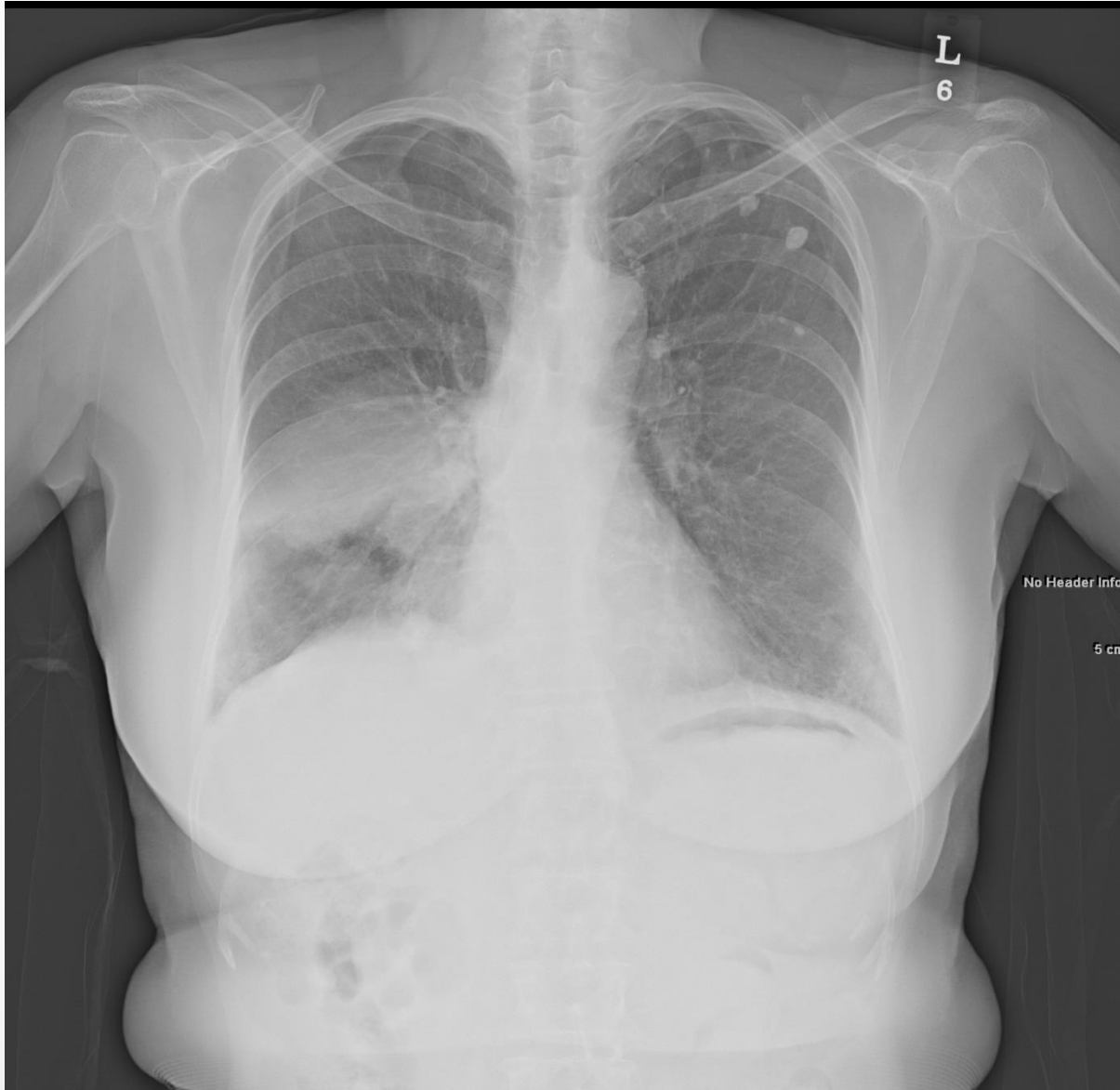간유리 음영



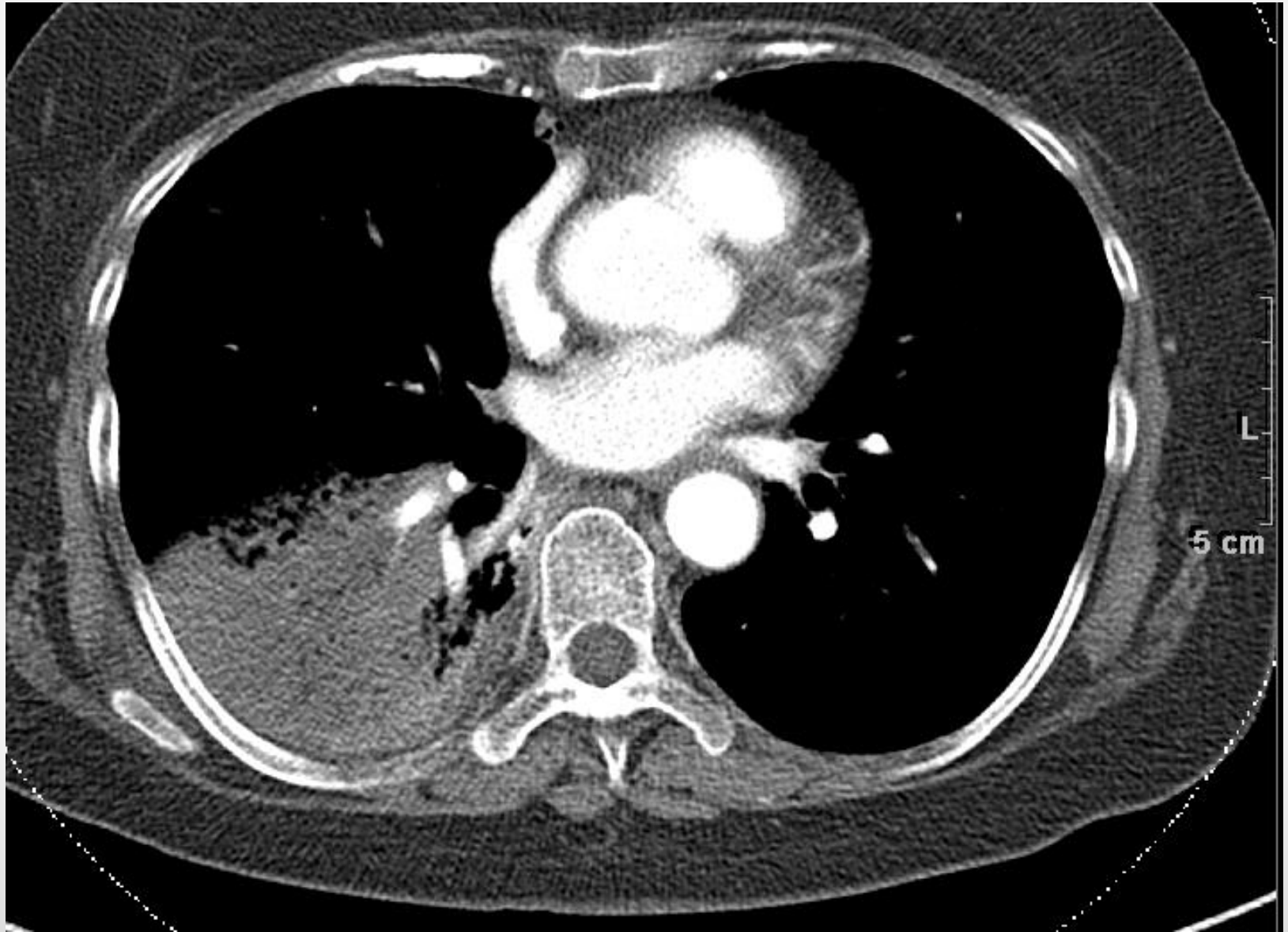




혹일까요?



흑인가요?



@ ER

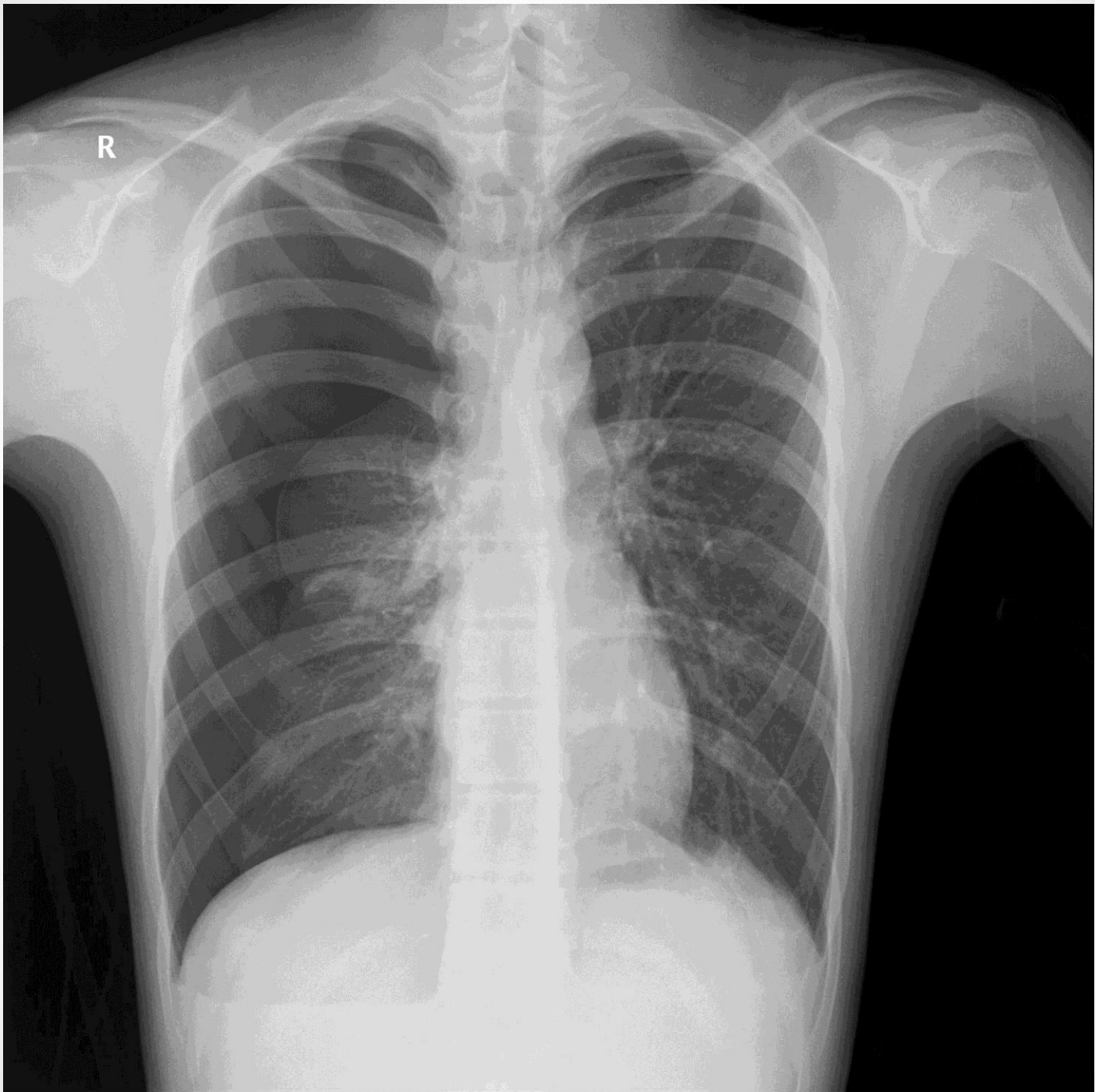- **To have knowledge of diseases**
 - Pneumothorax
 - Rib fracture
 - Hemothorax
 - Esophageal rupture
 - Tracheal injury

@ ICU & General Ward

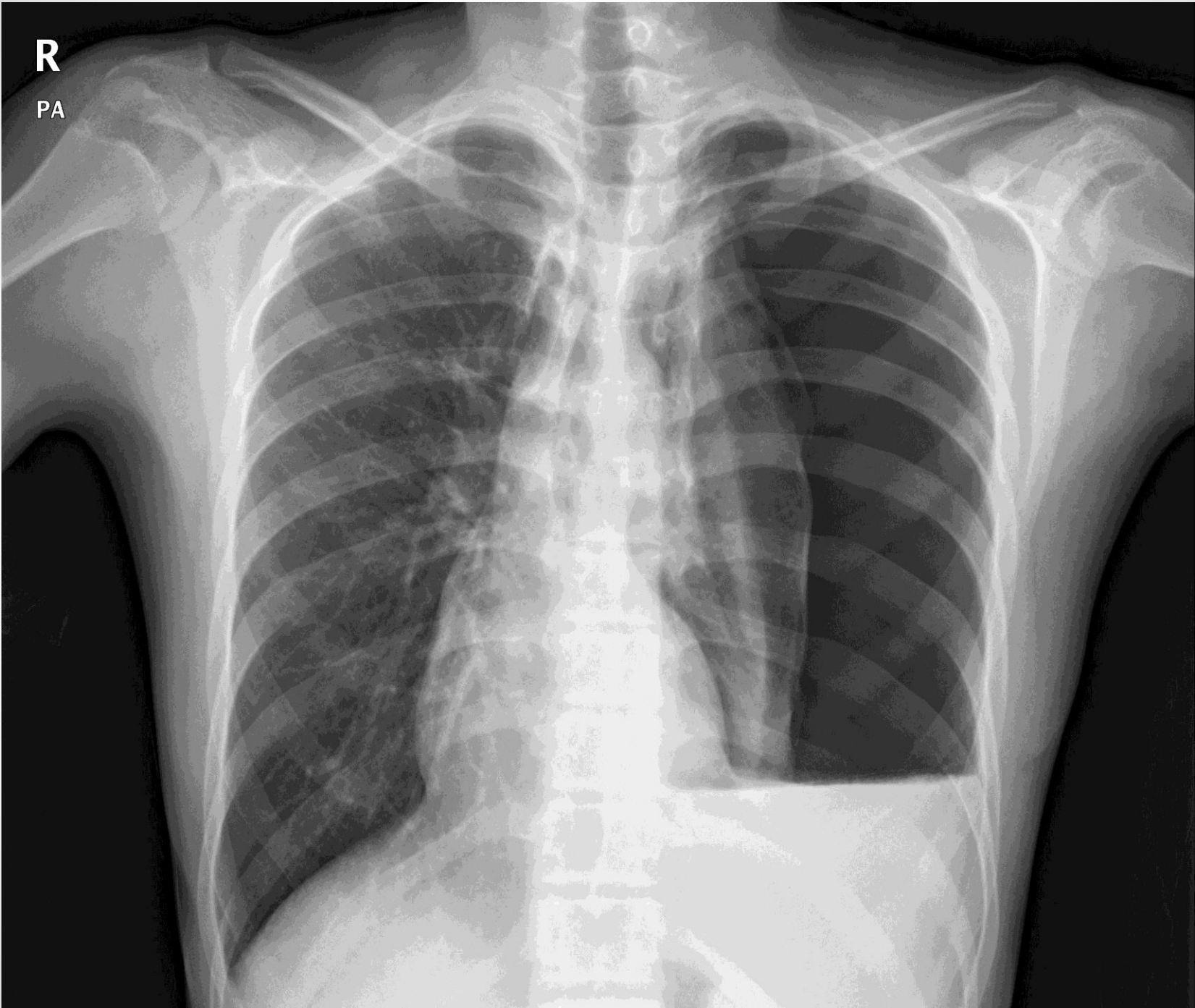
- To know possible complications
 - How to approach
 - Extent of operation
 - Events
 - Underlying disease

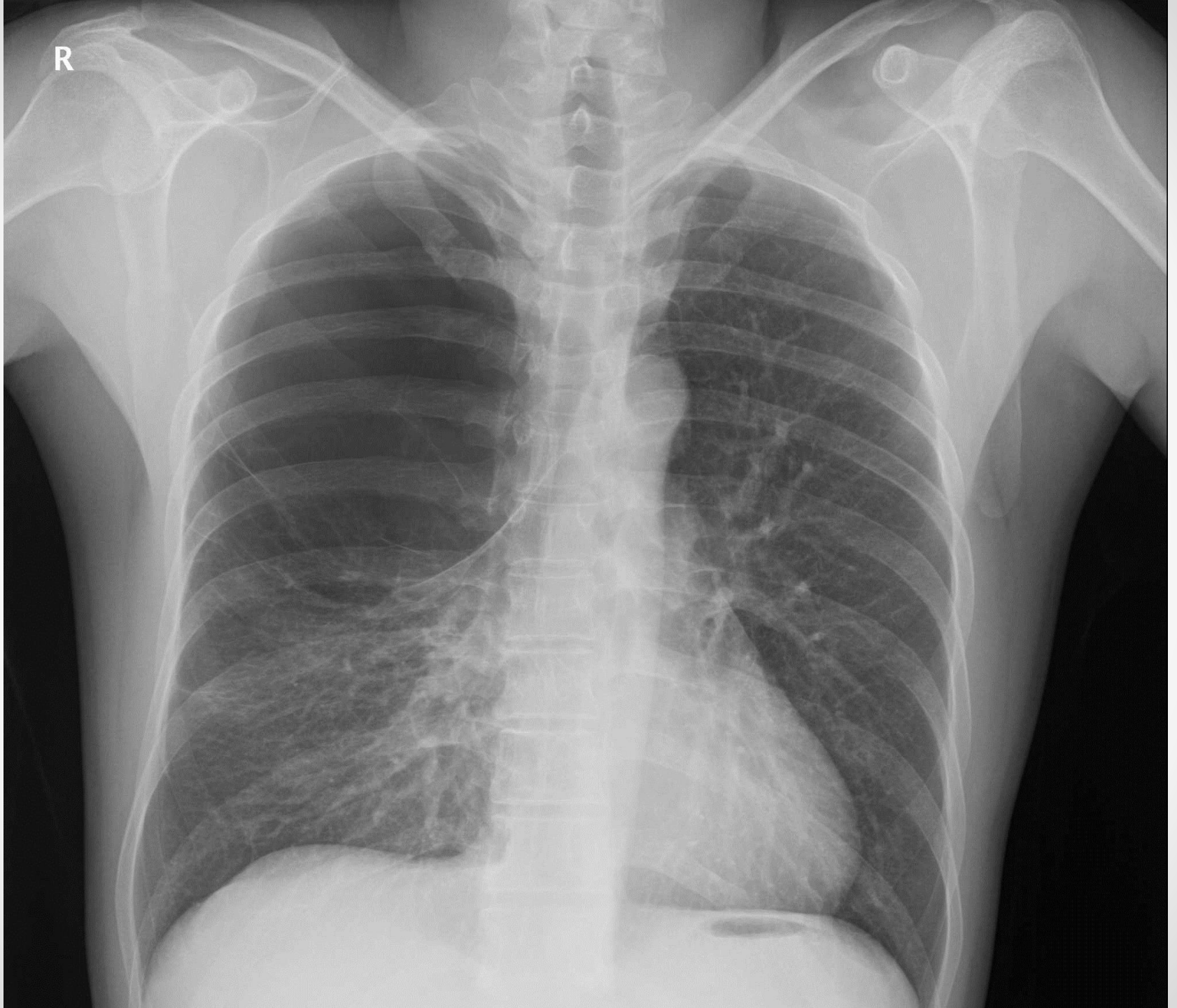
@ ER

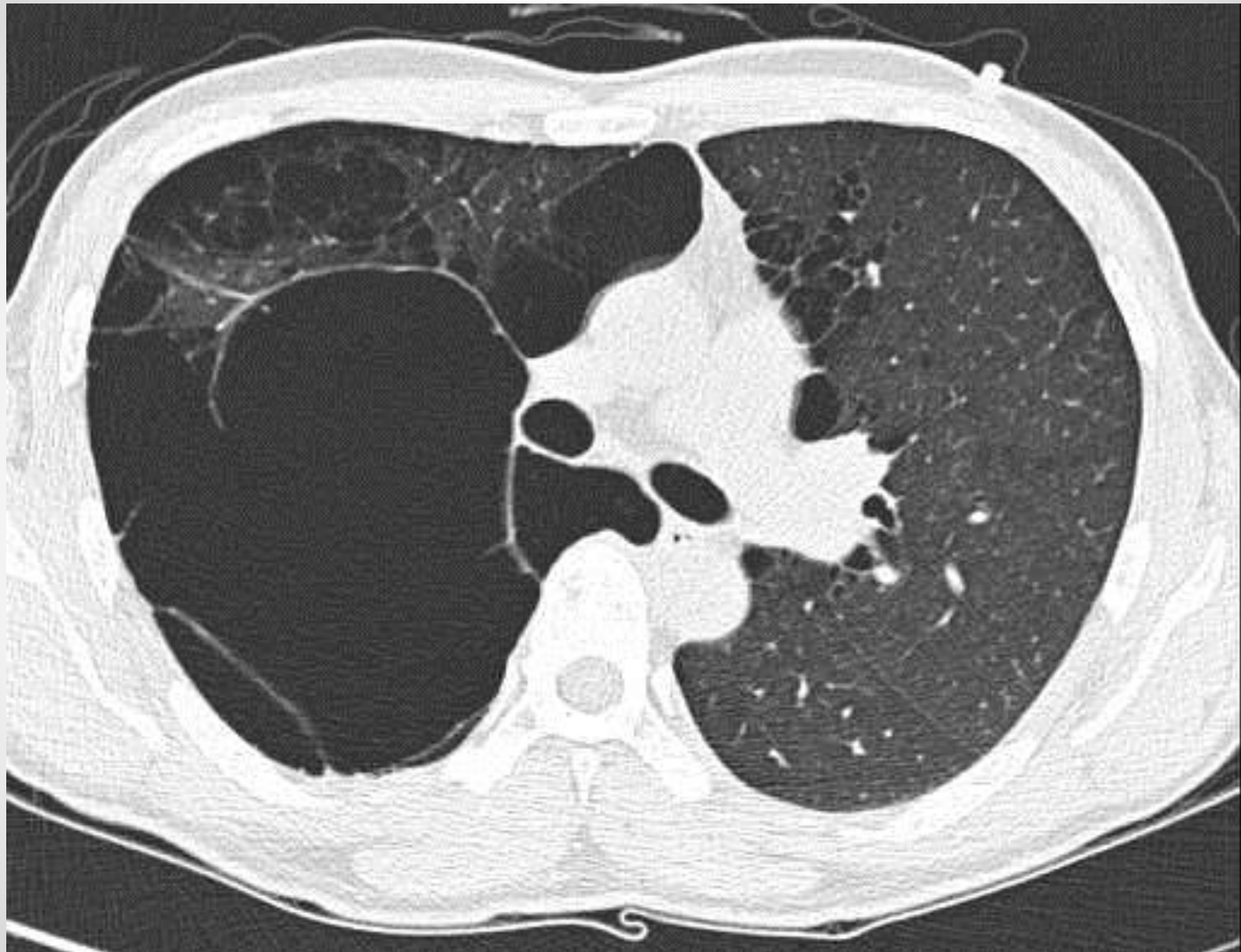- M/16
- Chest pain, Rt. (1DA)
- Cough, dyspnea
- Non-smoker



R
PA

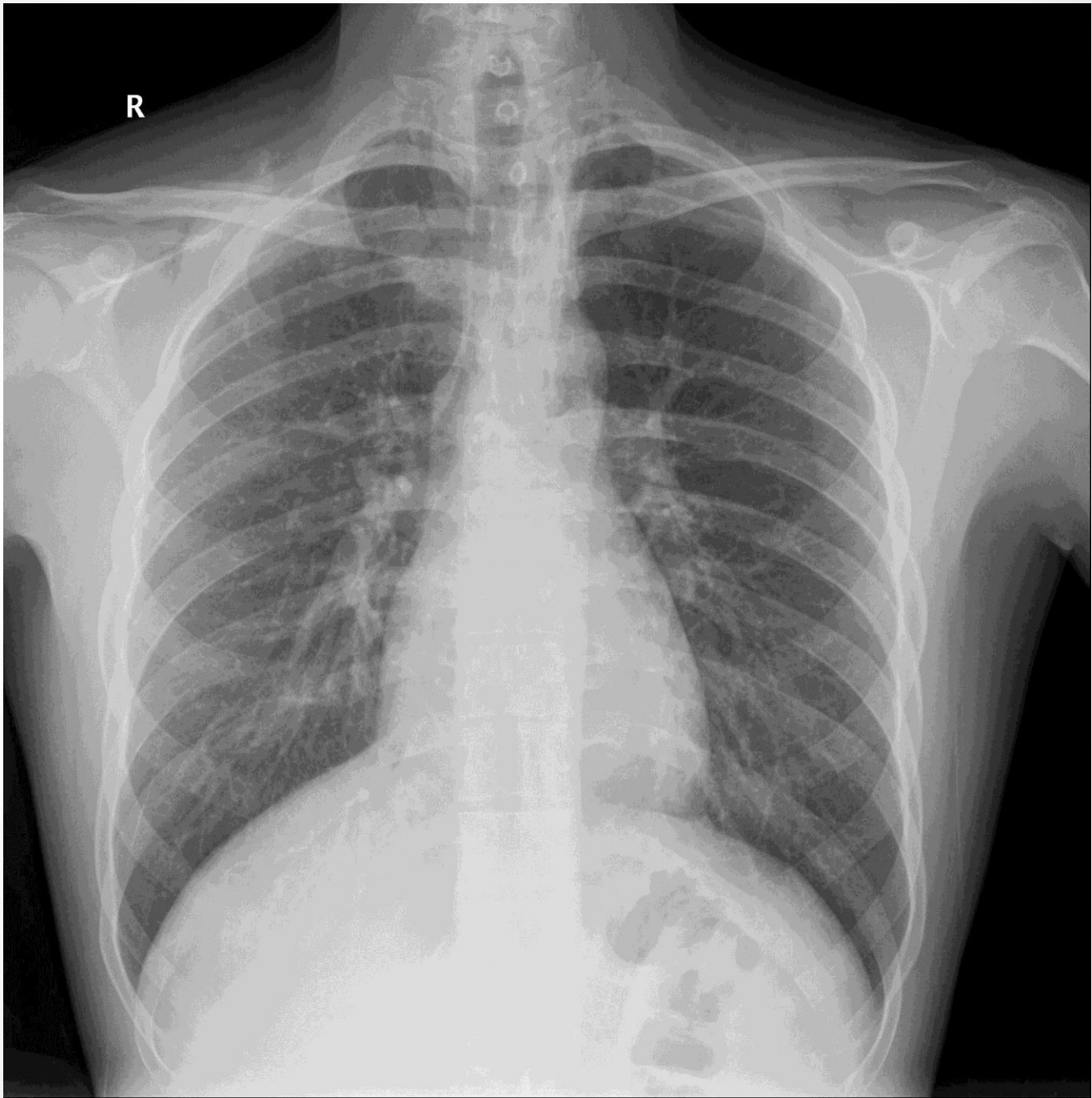


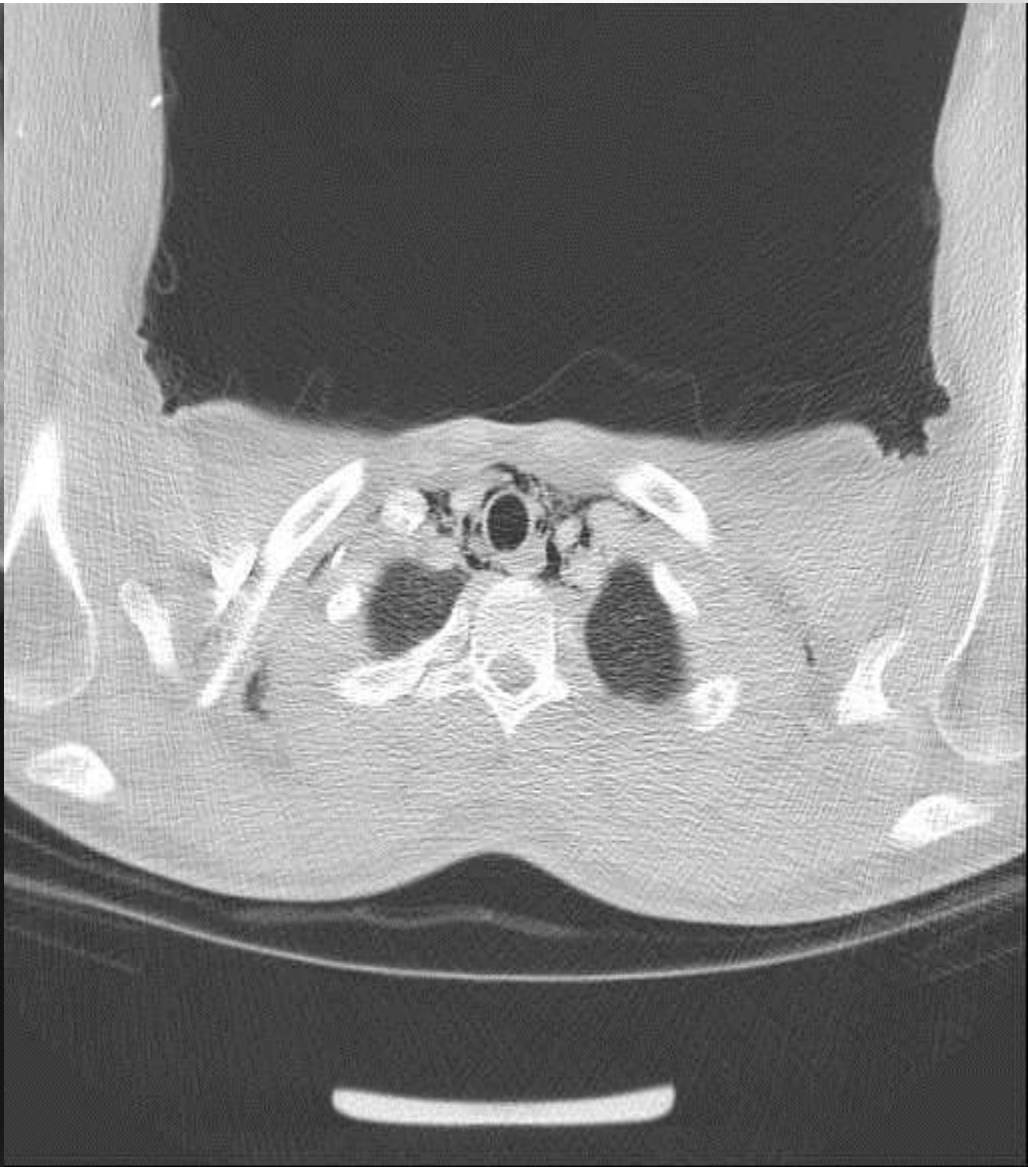
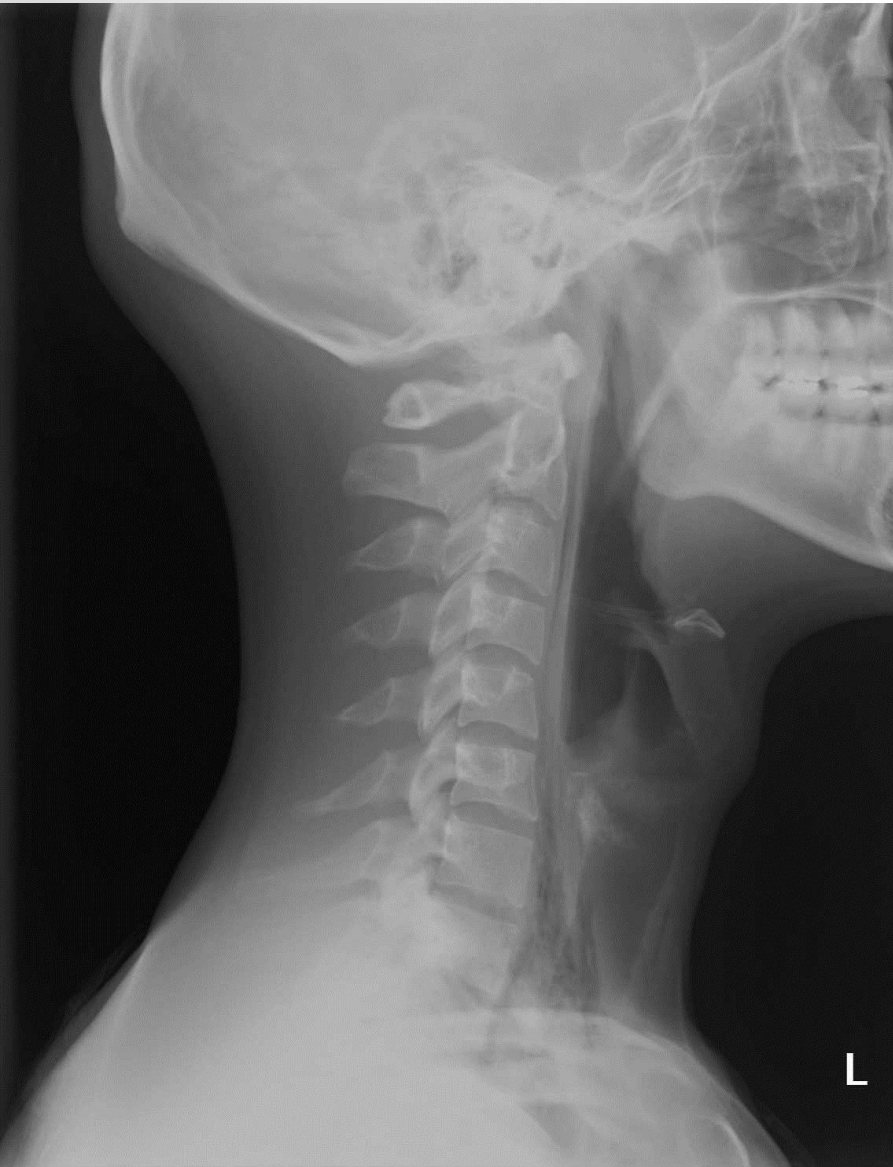



@ ER

- M/21
- Persistent cough (3DA)
- Neck pain
- Throat pain on swallowing

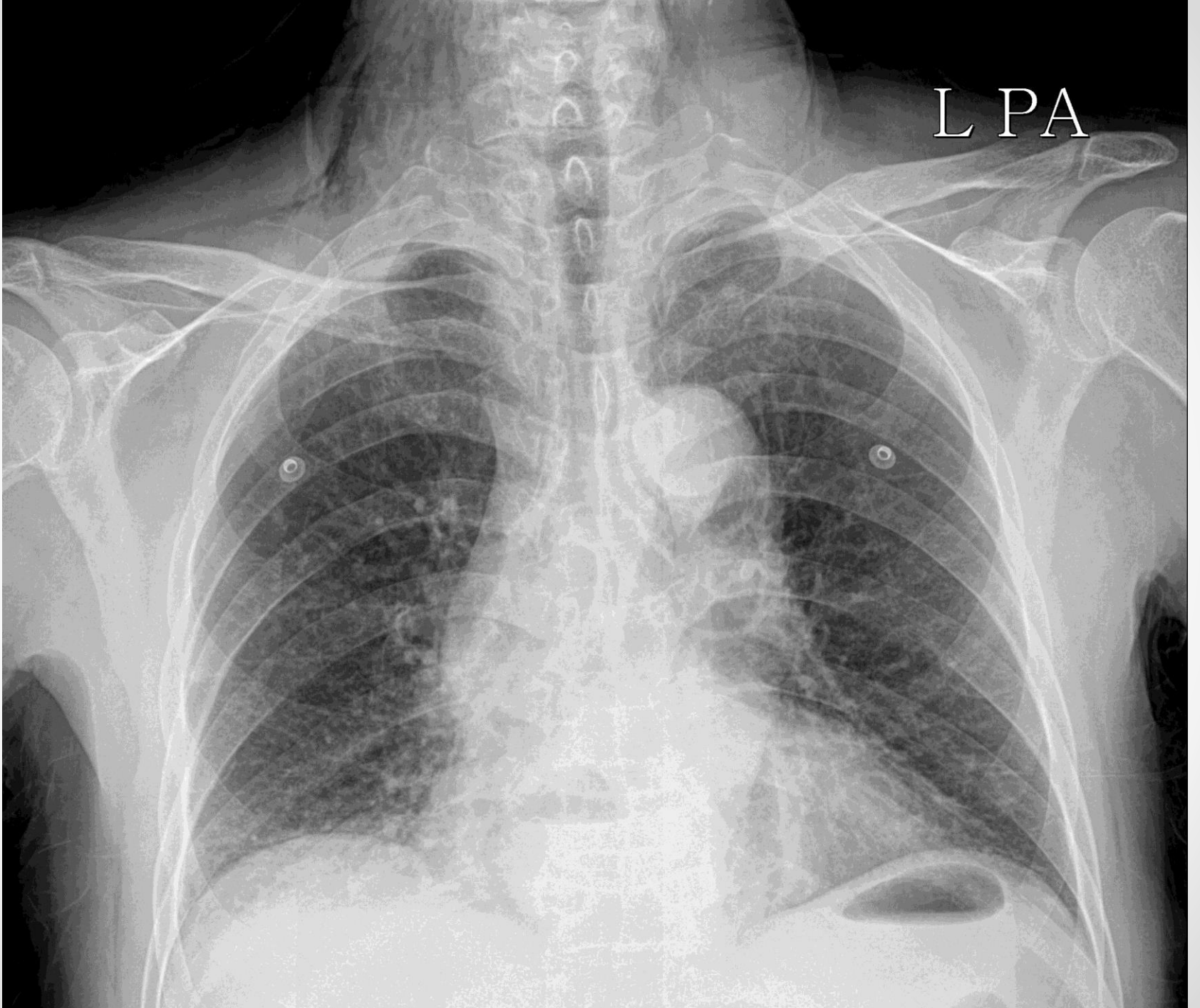


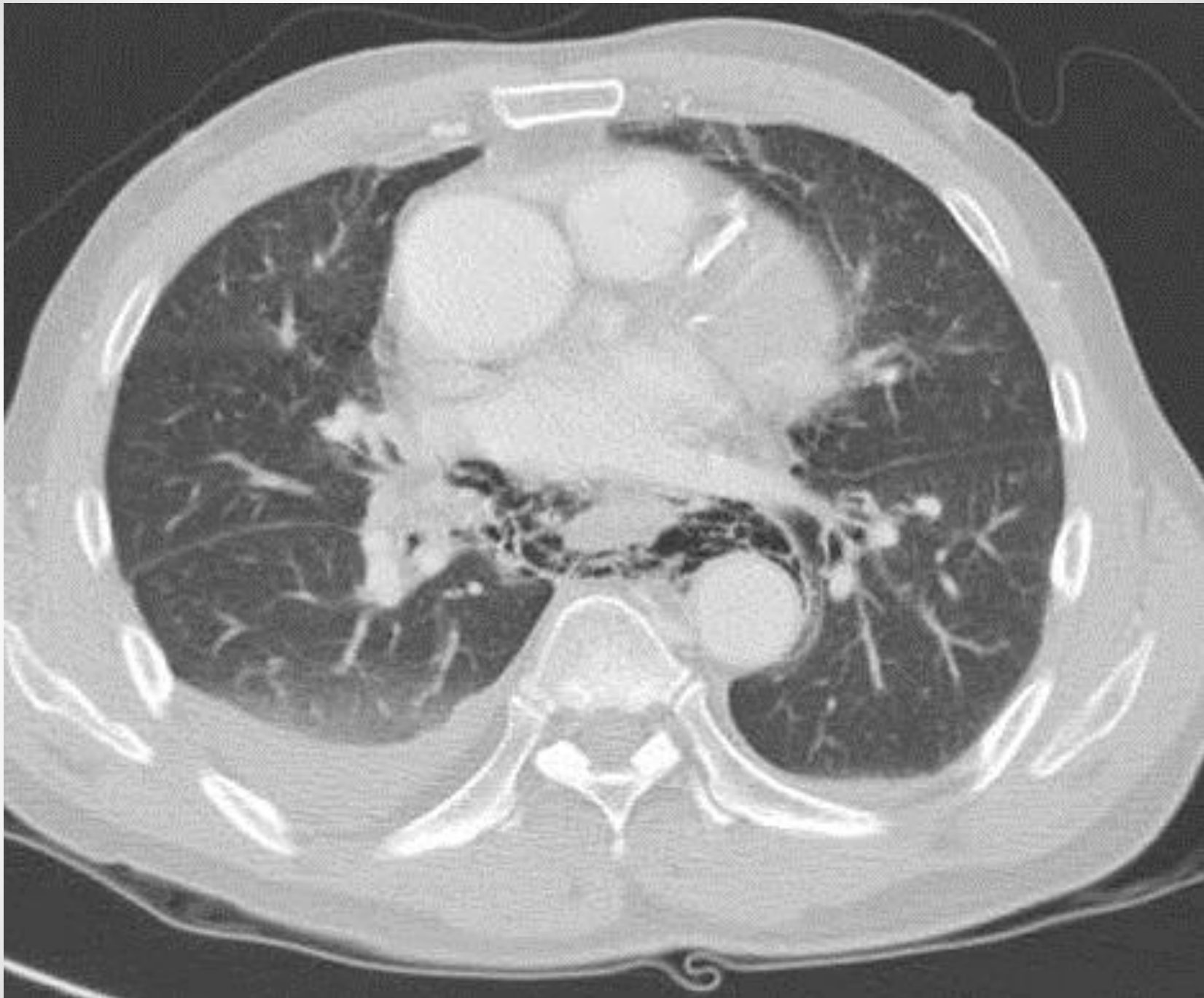


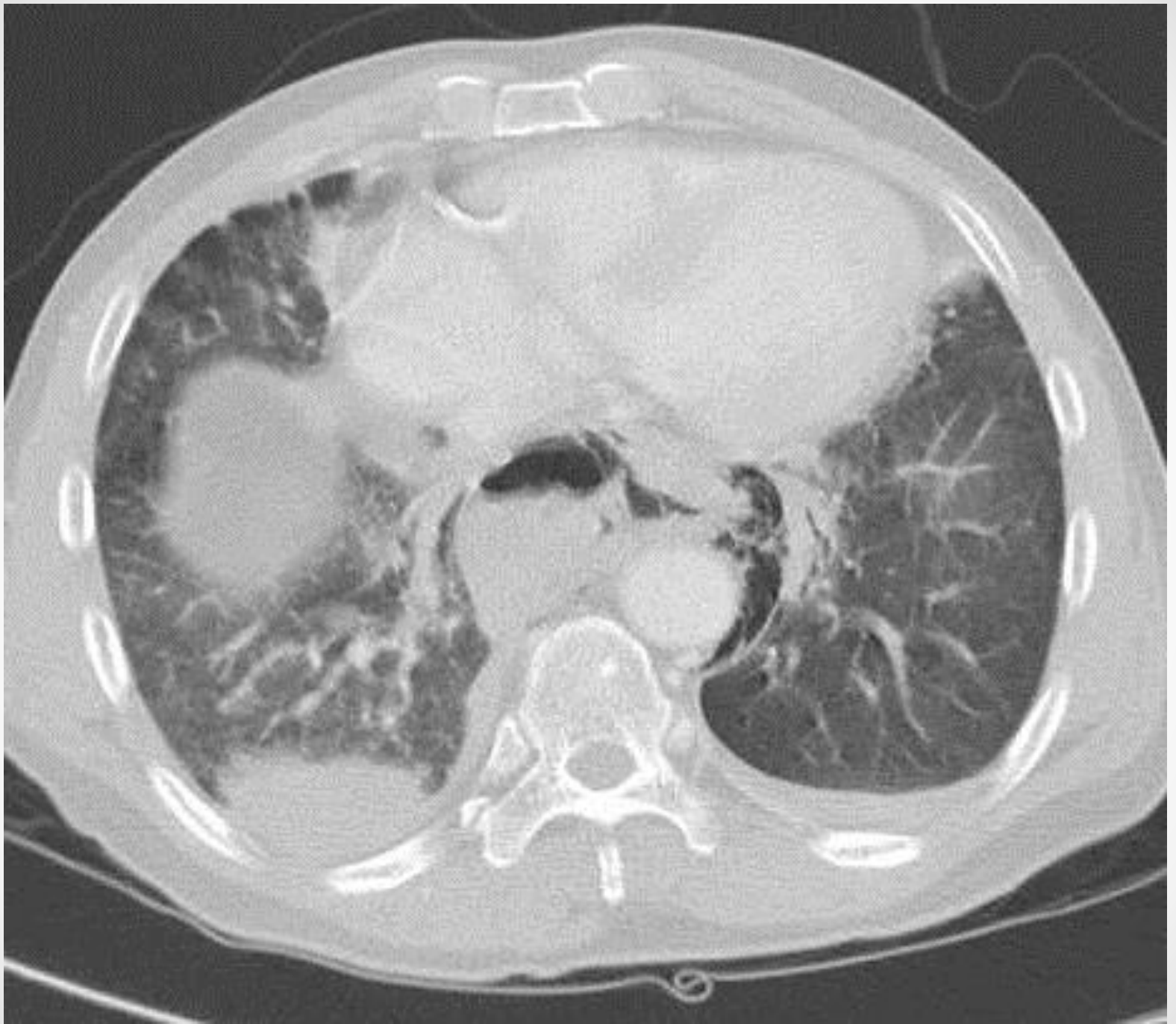
@ ER

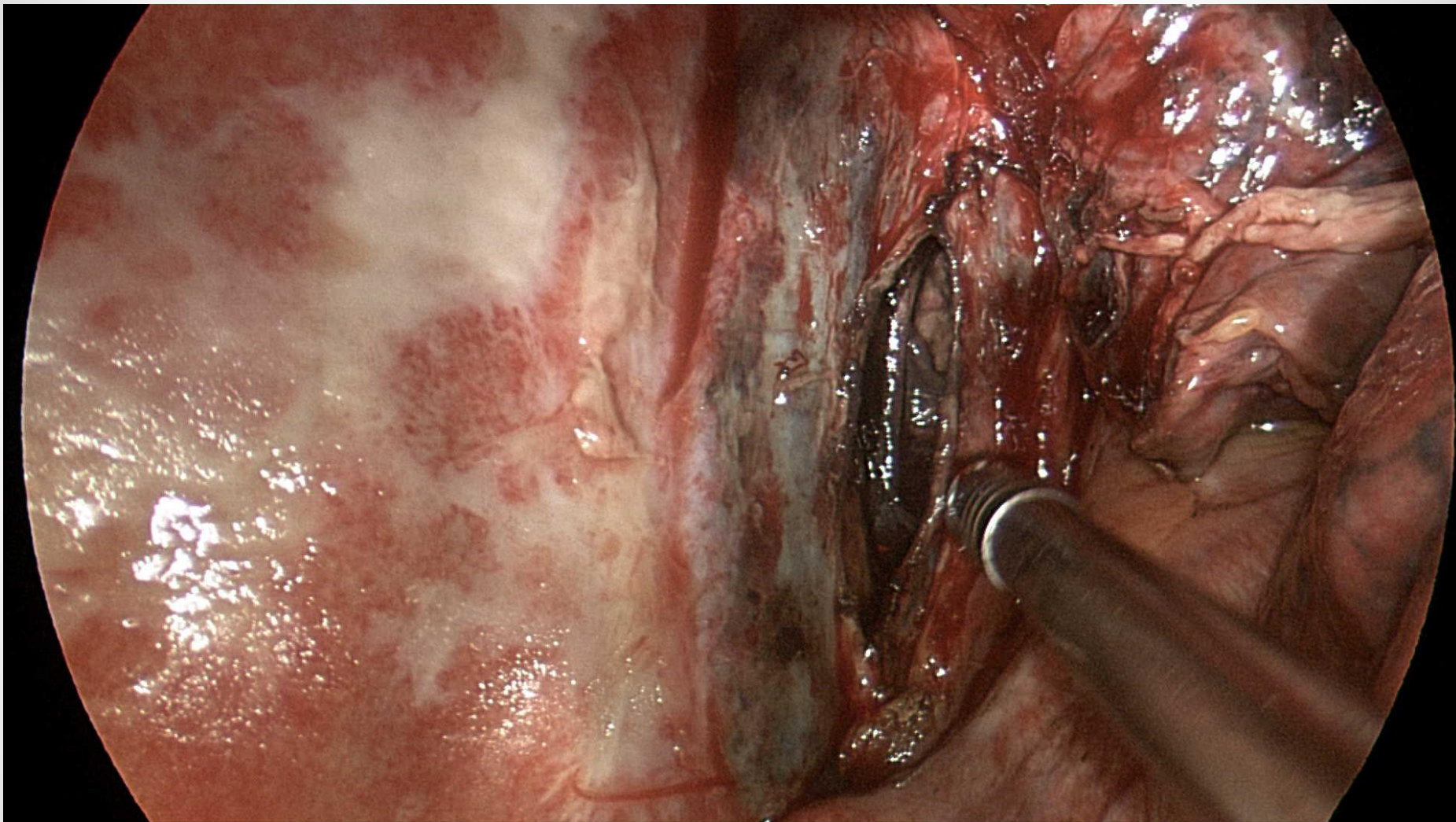
- M/56
- Abdominal pain (1DA)
- Fever/ chilling
- Heavy alcoholics
- Vomiting

L PA



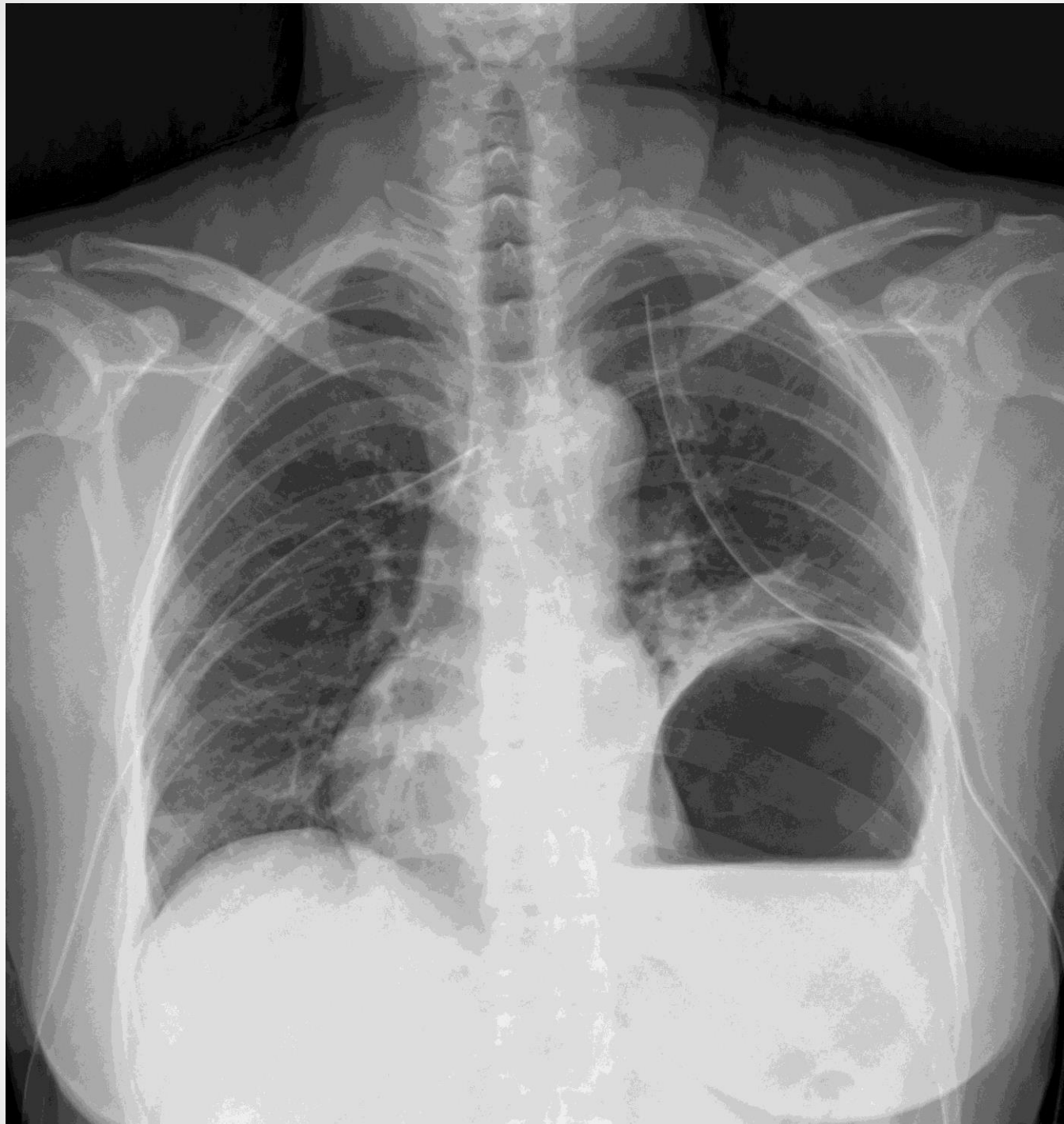


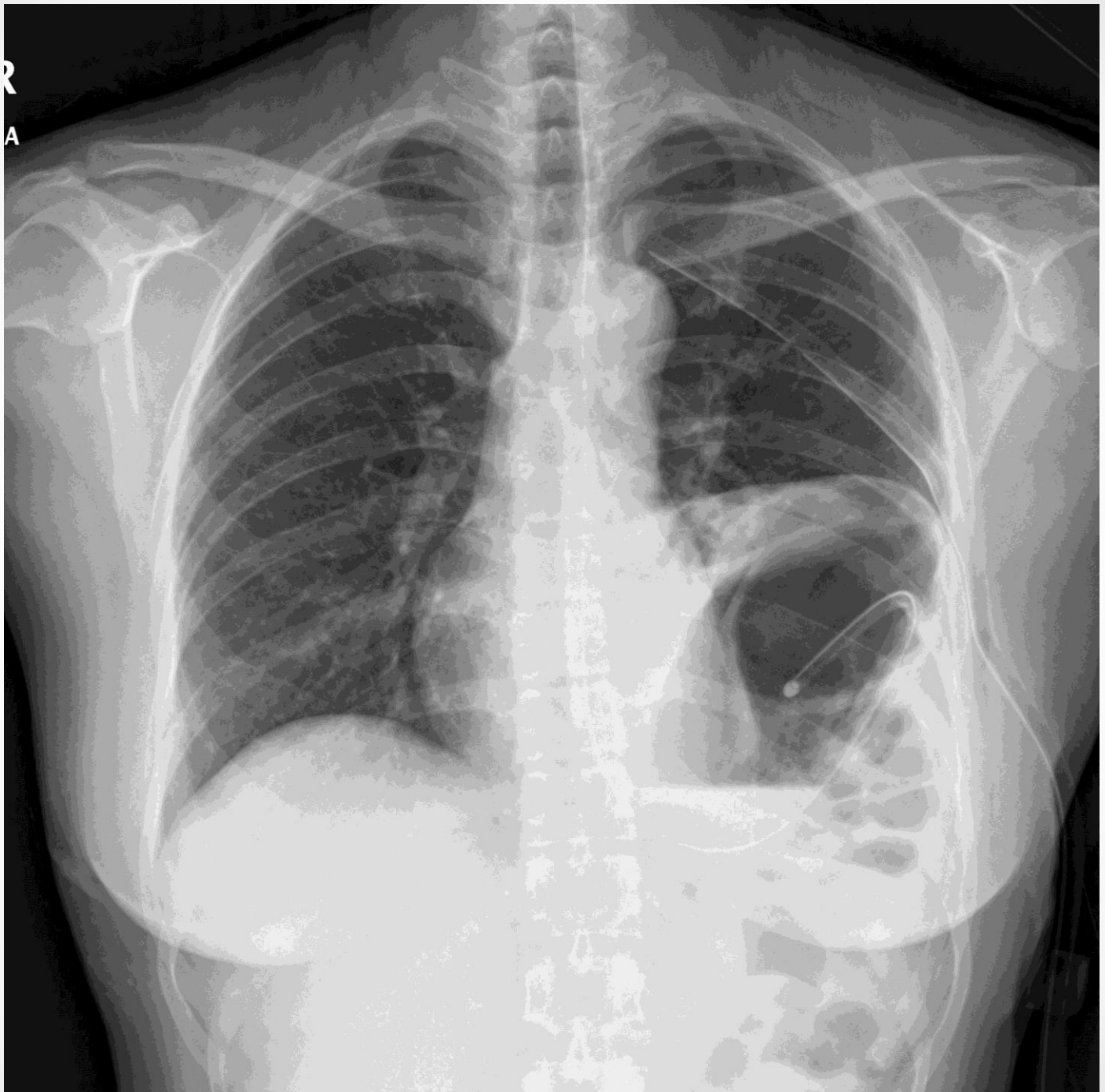




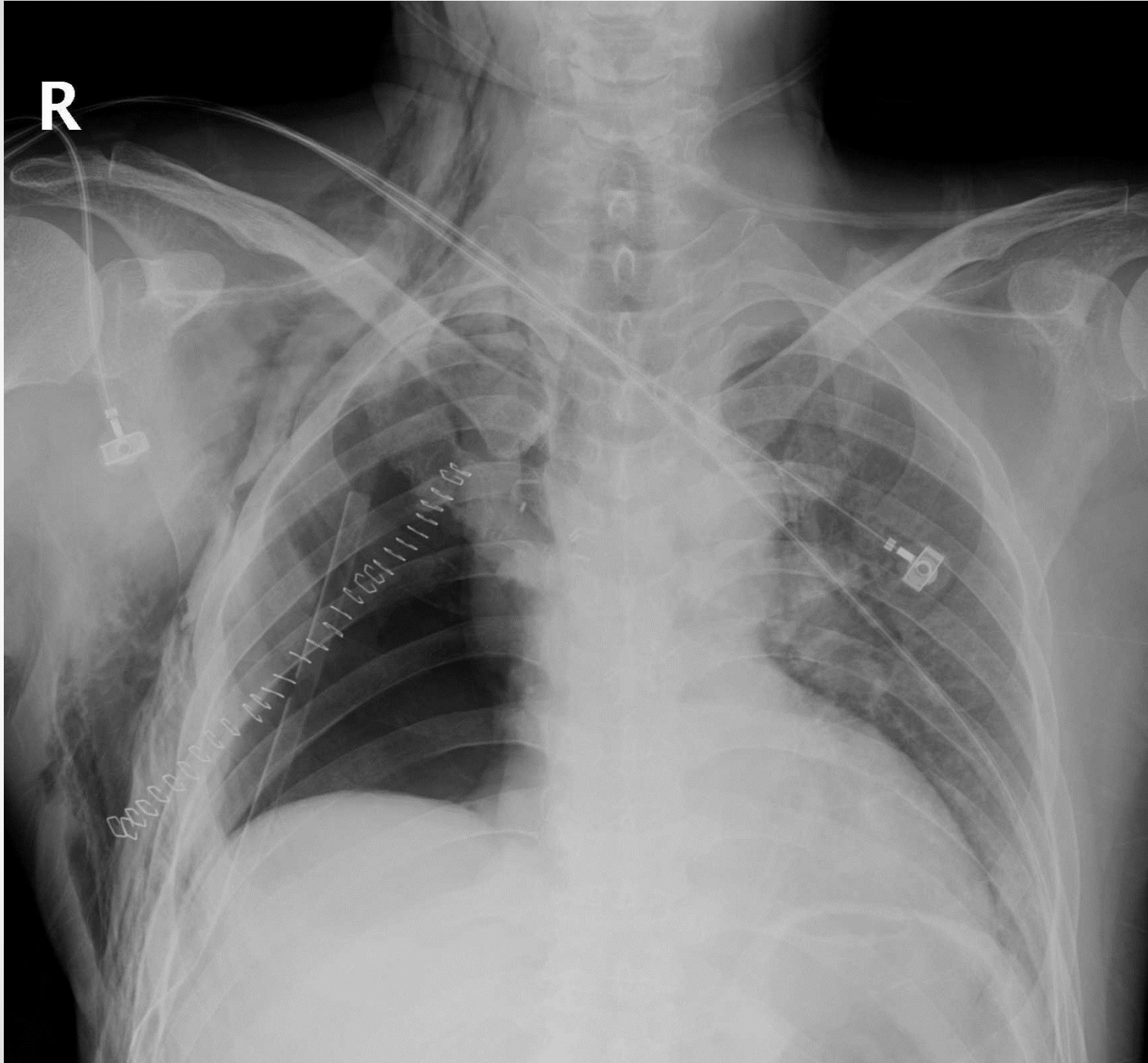
@ ER

- M/52
- Blunt Trauma to chest
- Dyspnea
- Chest pain



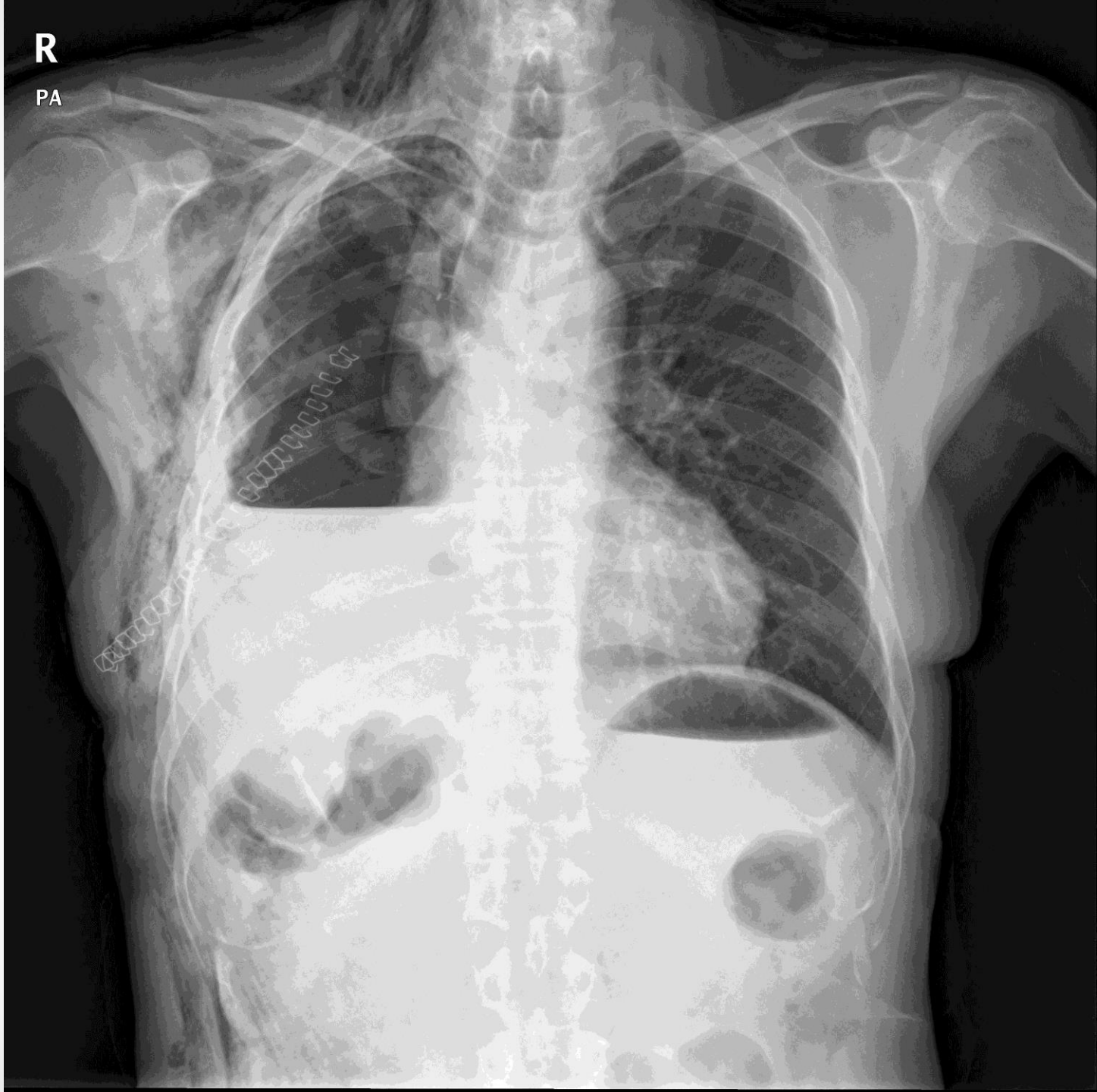


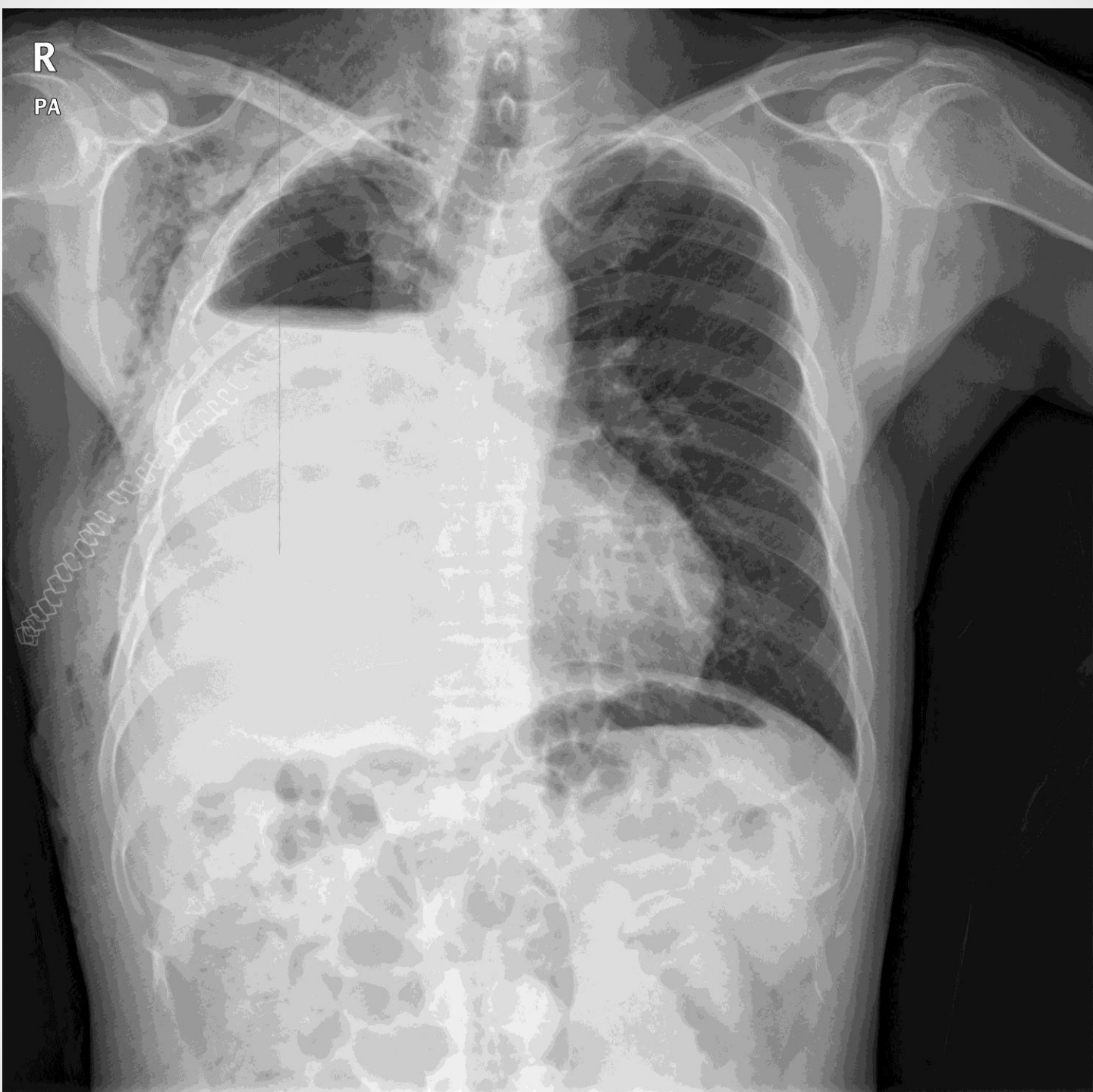
R



R

PA





R

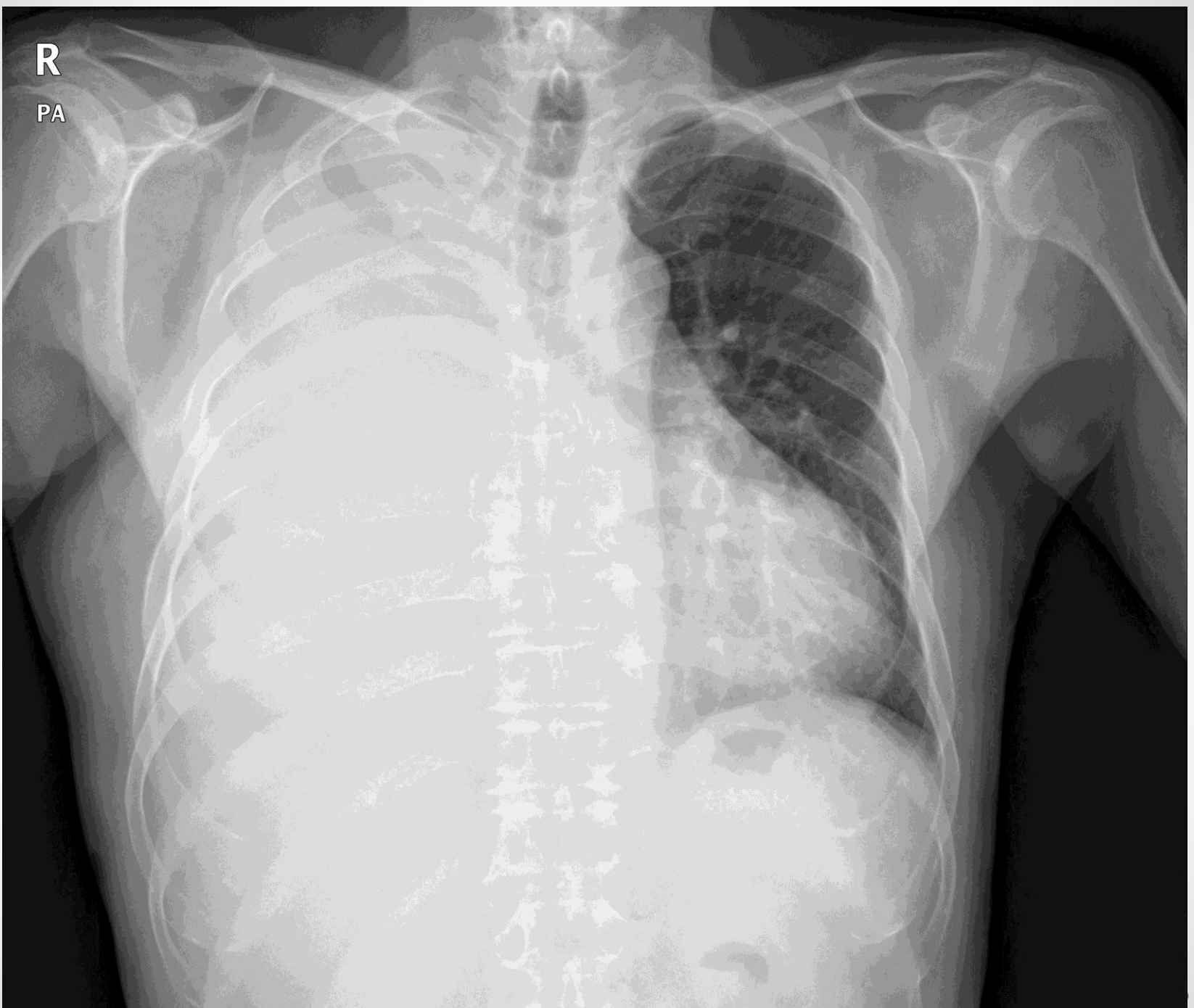PA

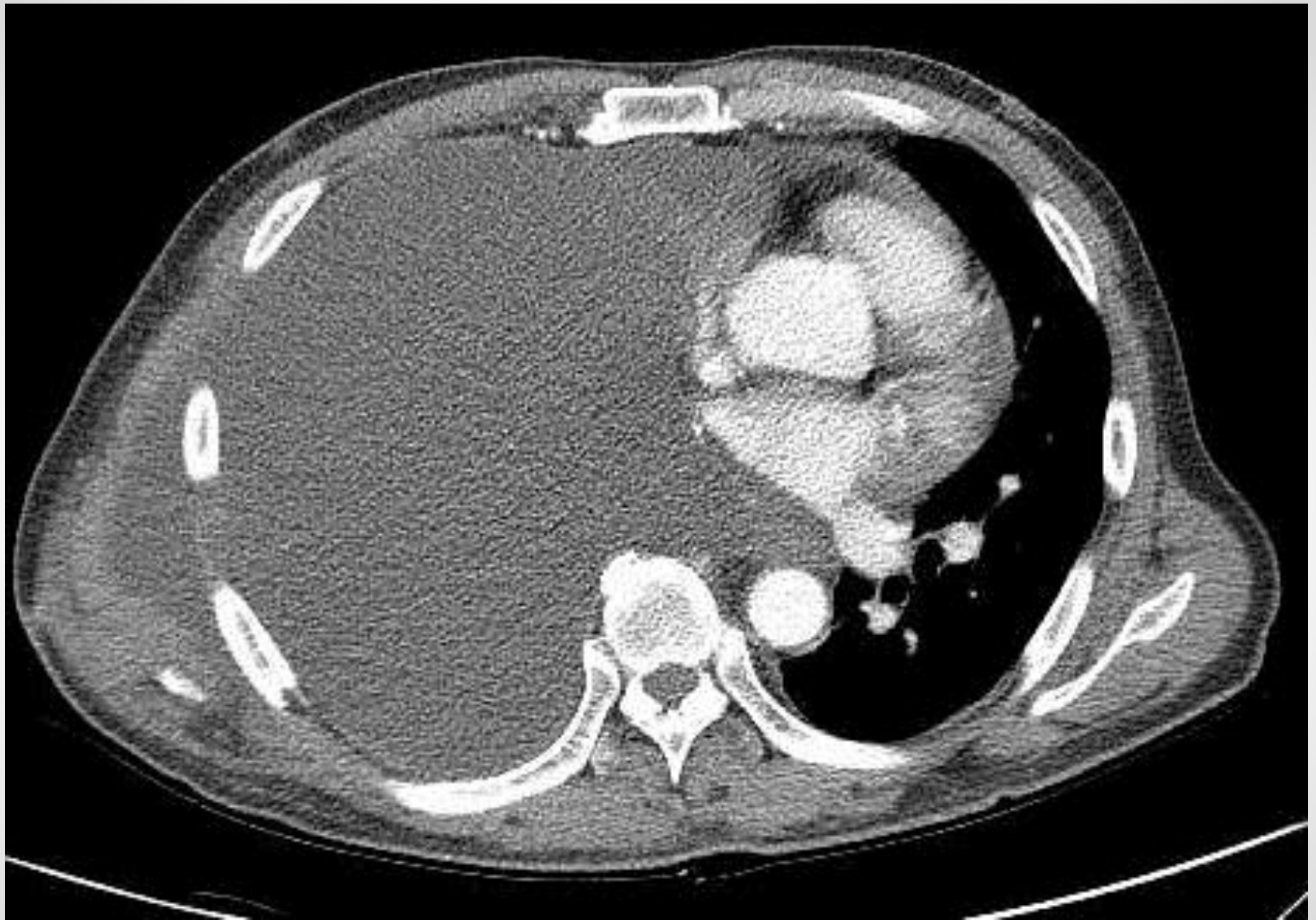@ OPD

- M/62
- s/p Rt. Pneumonectomy (2WA)
- Dyspnea, aggravation

R

PA

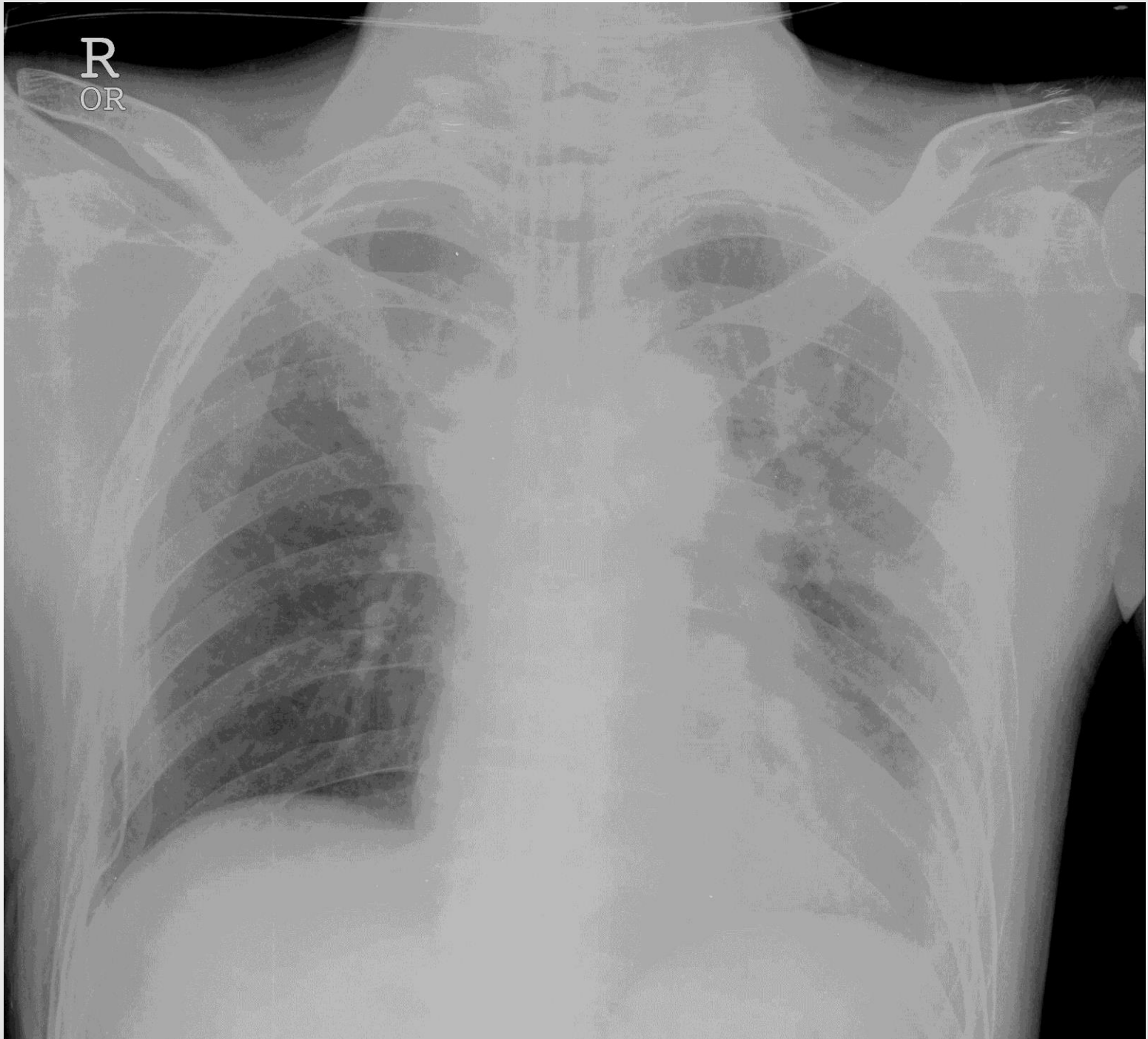




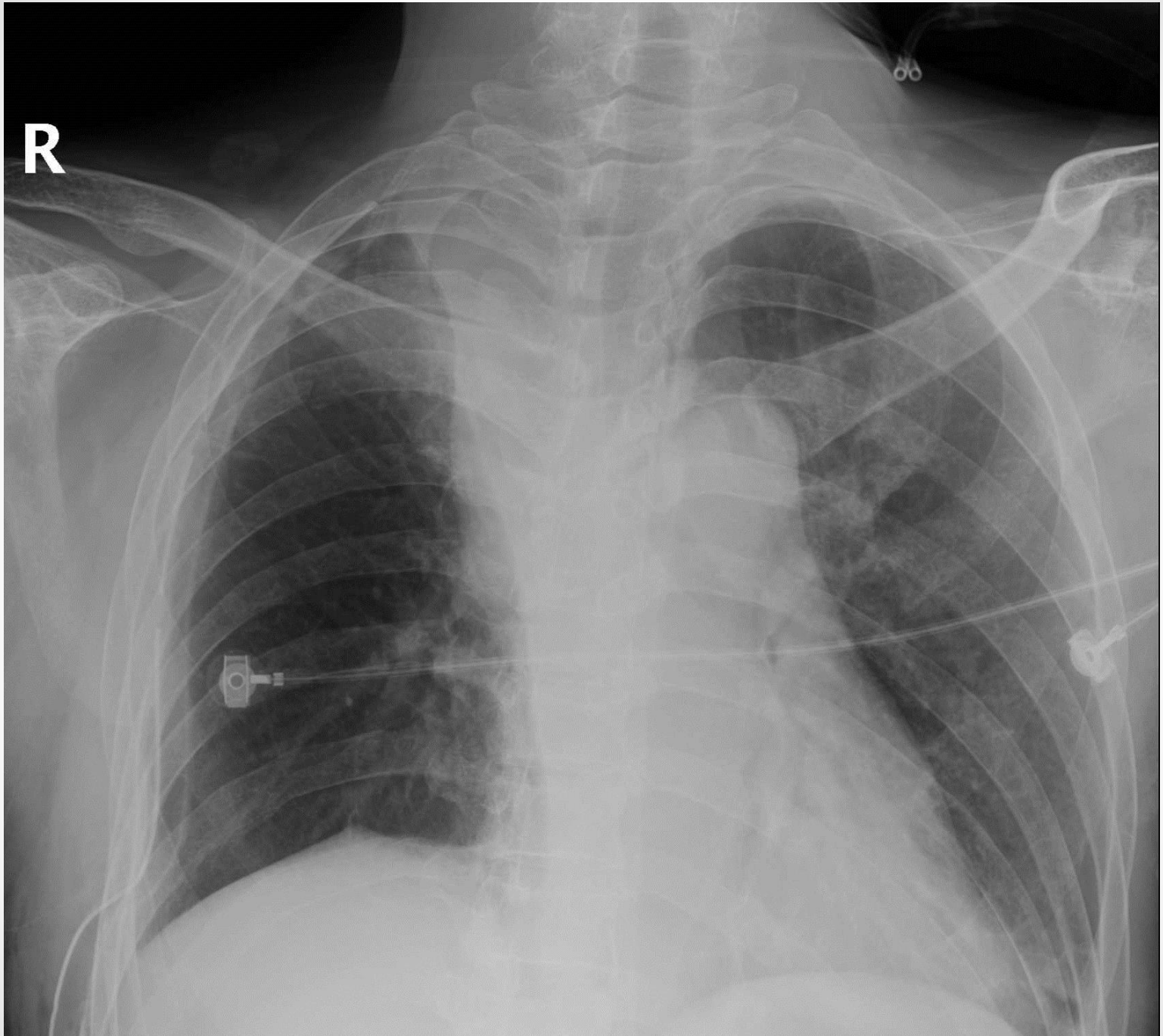

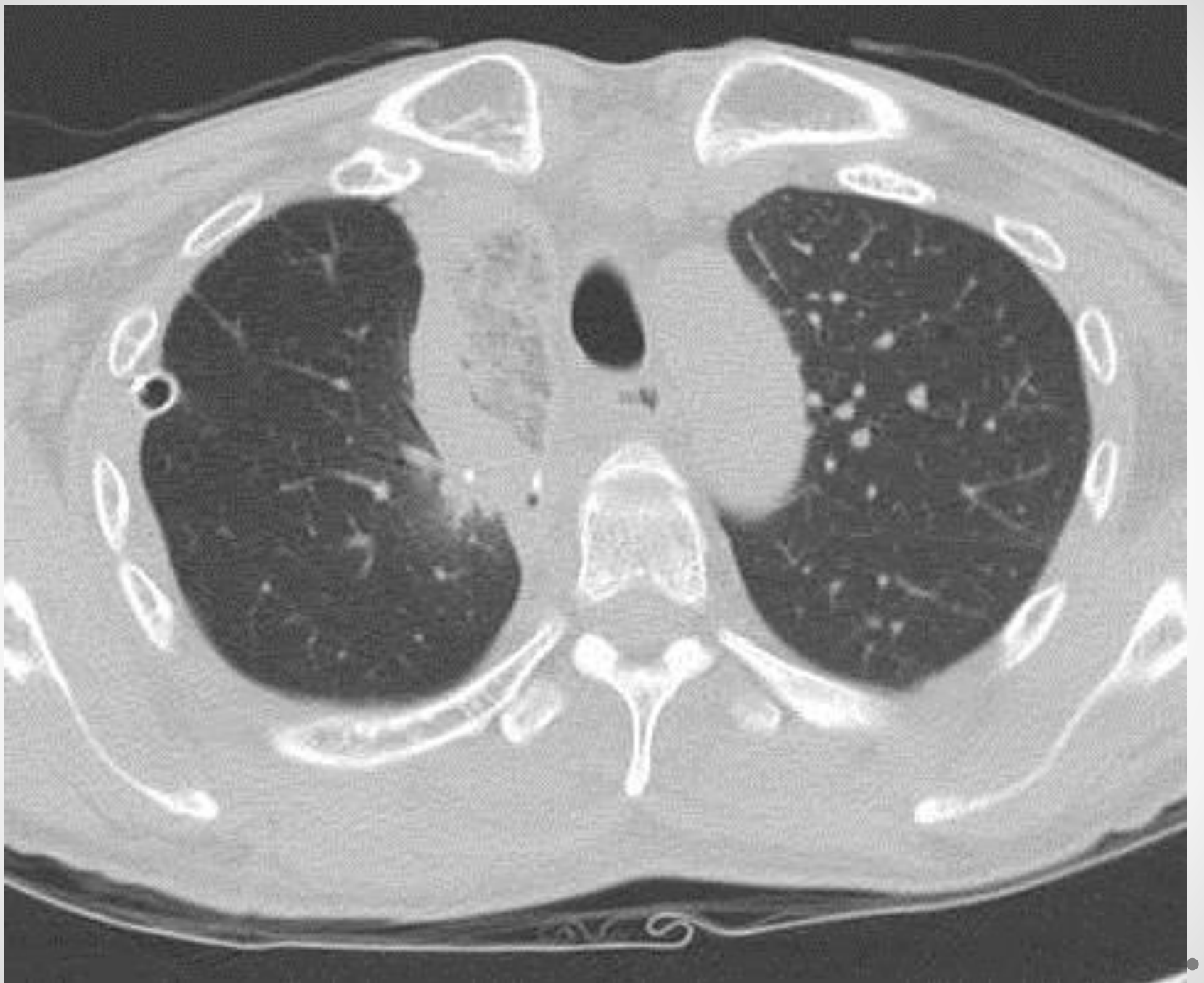- M/58
- s/p RULobectomy, 3DA
- Dyspnea
- Tachycardia
- Fever/ leucocytosis

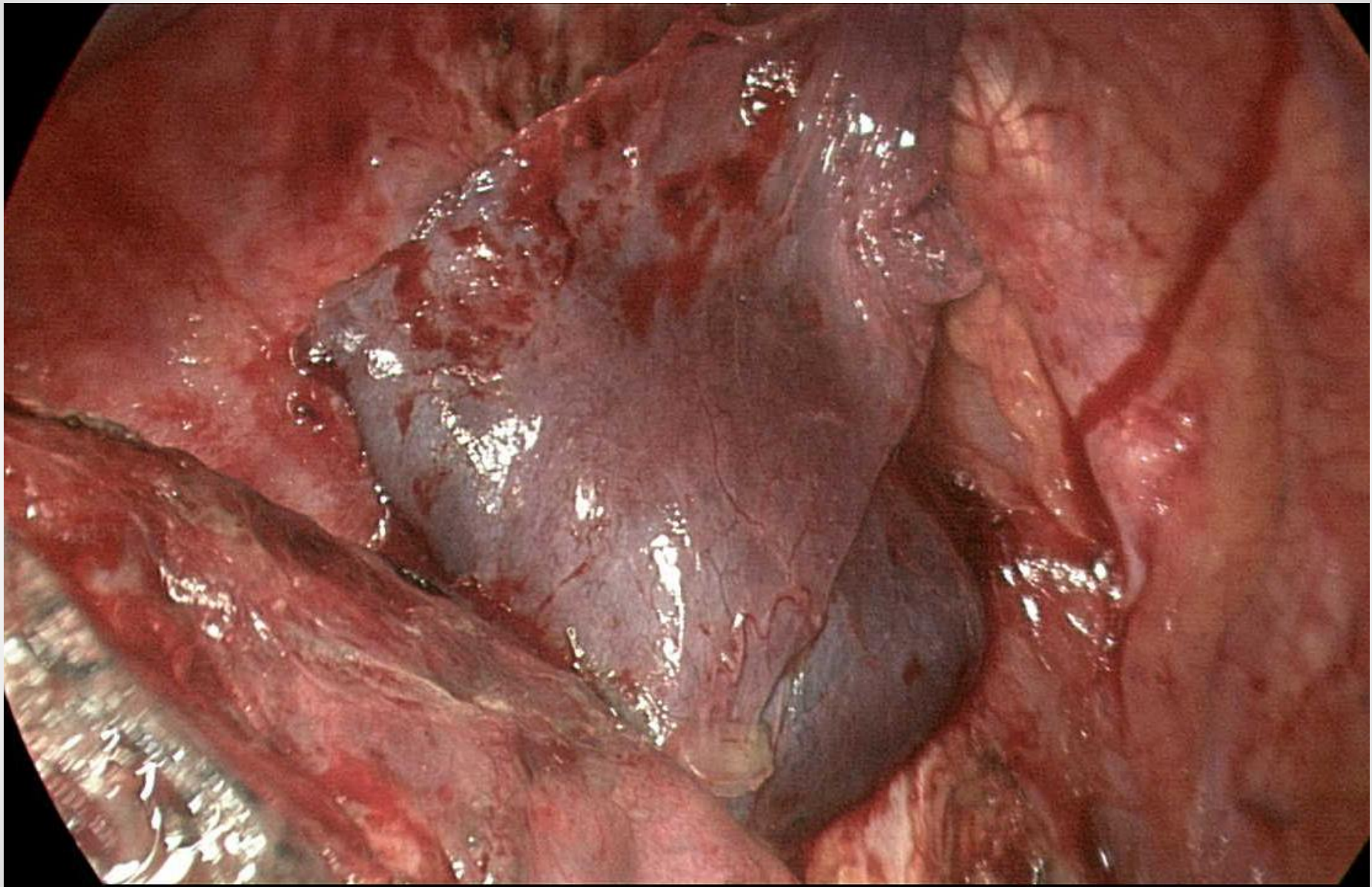
R
OR



R







Post-lobectomy torsion

- vs. Collapse
- After RULobectomy
- Anchoring or not
- Rapid diagnosis
- Emergent operation

How to improve your ability

- To know events during operation
 - Review operation records
 - Review operation video
 - Ask operator/ senior assistants
- To listen carefully to your patients
 - Consistent symptoms
 - Severe symptoms
 - Frequent symptoms



감사합니다