




흉부외과 1년차 기본술기

부산대학교병원
조정수





Contents

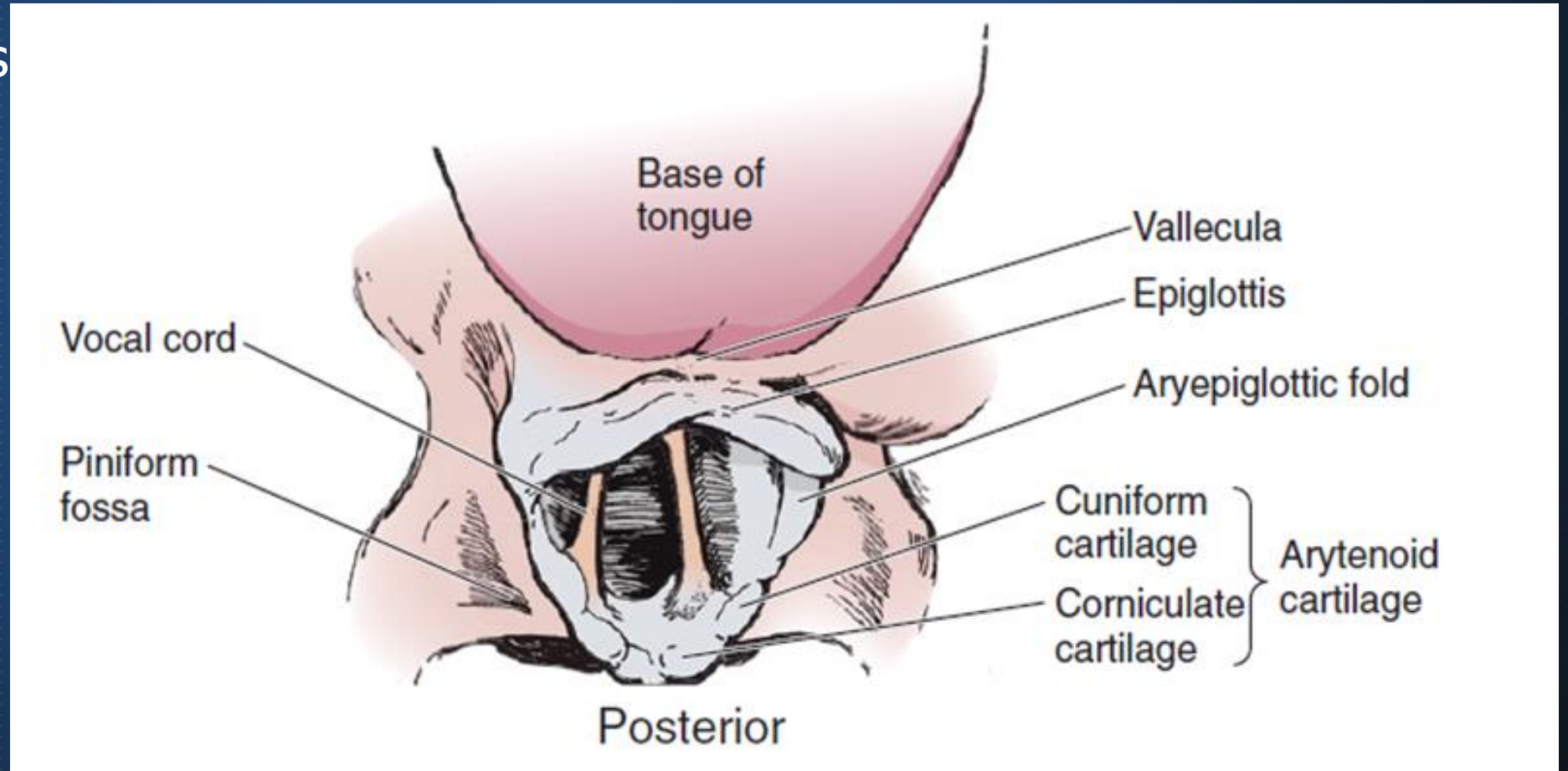
1. Endotracheal and Laryngeal airway Intubation
2. Central line insertion
3. A-line
4. Closed thoracostomy
5. Thoracentesis



Endotracheal and Laryngeal airway Intubation

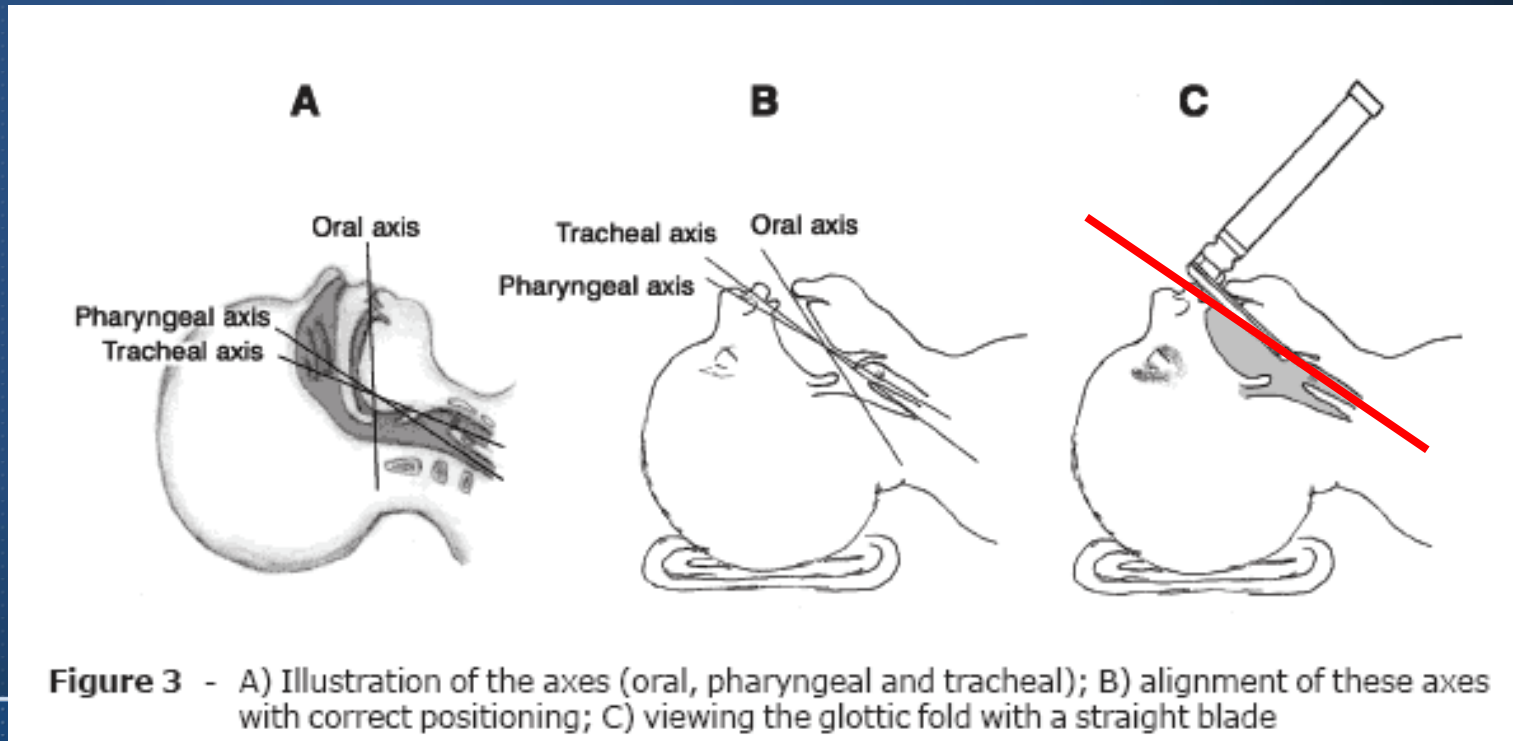
Anatomy

- Oral cavity, Pharynx, Larynx, Trachea
- Vallecula fossa

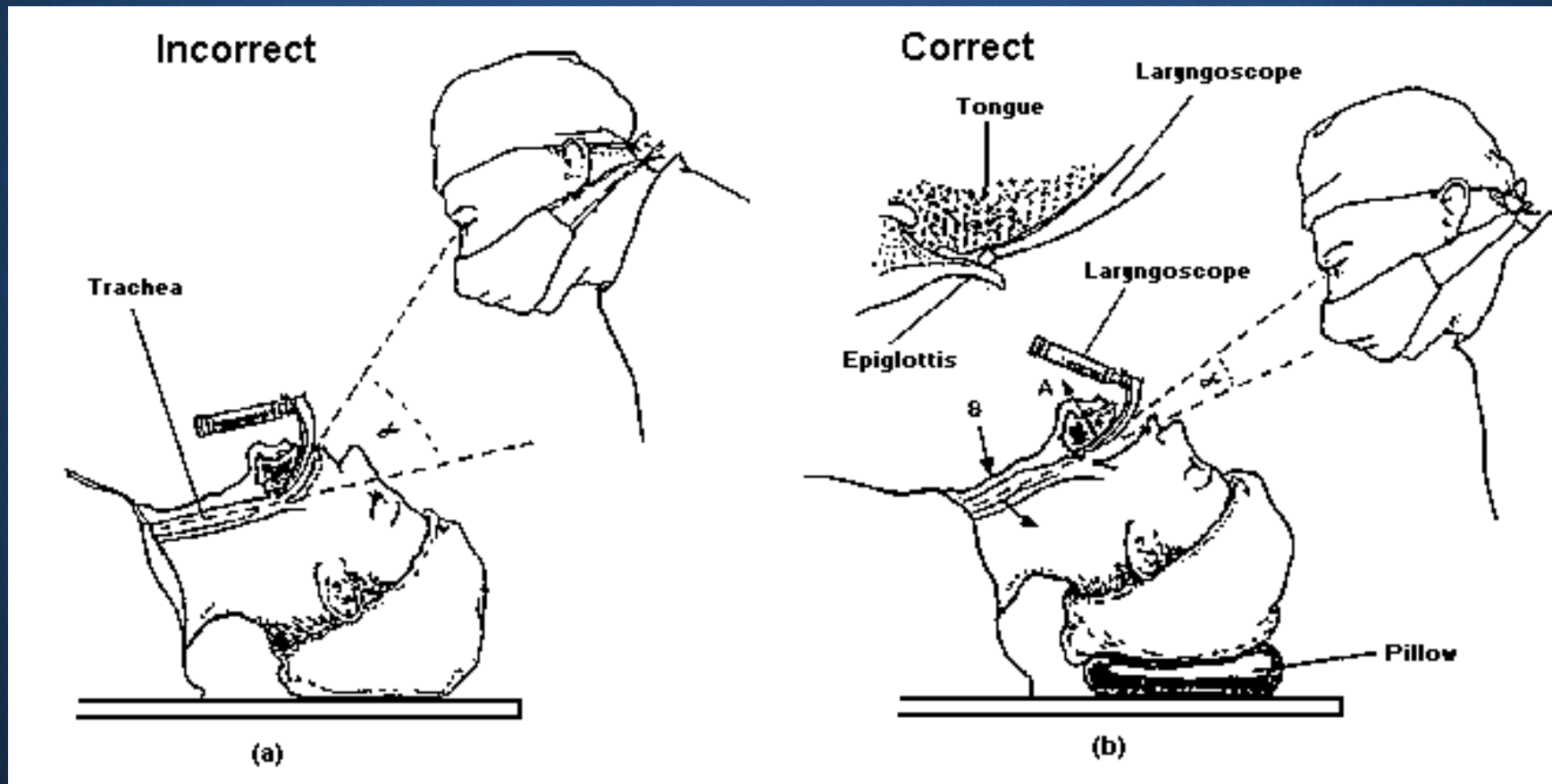


• Upper Airway -3 Axis

- Oral Axis, Pharyngeal Axis, Tracheal Axis
- Need pillow under subscapular lesion (children) or occipital bone(Adult)

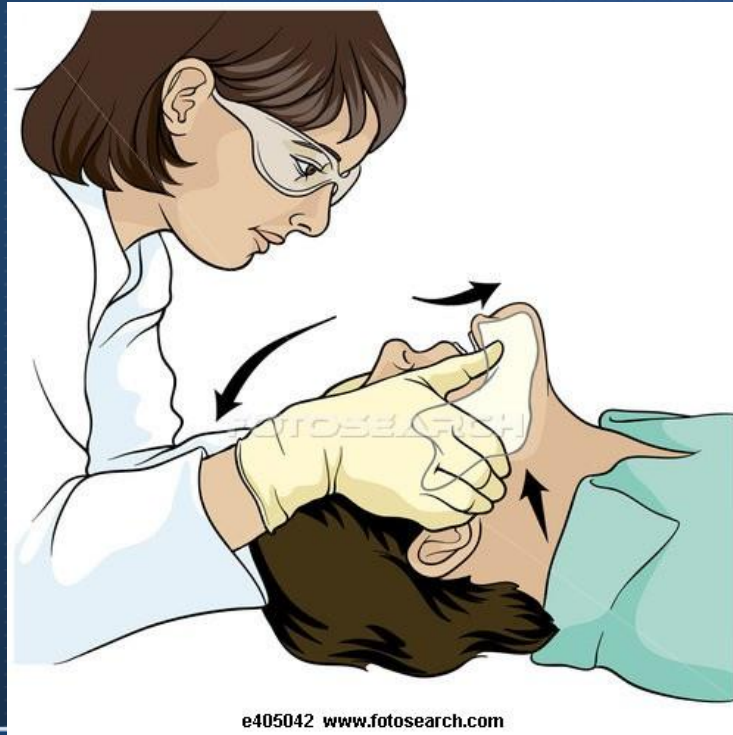

- “Sniffing Position”



Non Intubation Management

- **Triple Airway Maneuver, 삼중기도처치법**
 - Unconsciousness but (+) self respiration
 - Head tilting, jaw thrust, chin lift : supra-laryngeal airway patency



Endotracheal Intubation

- **Endotracheal tube, General**

- **Internal Diameter :**

8.0(=8mm), 7.5(=7.5mm), 7.0(=7mm Bronchoscopic limit)

Adult male = 7.0-8.0

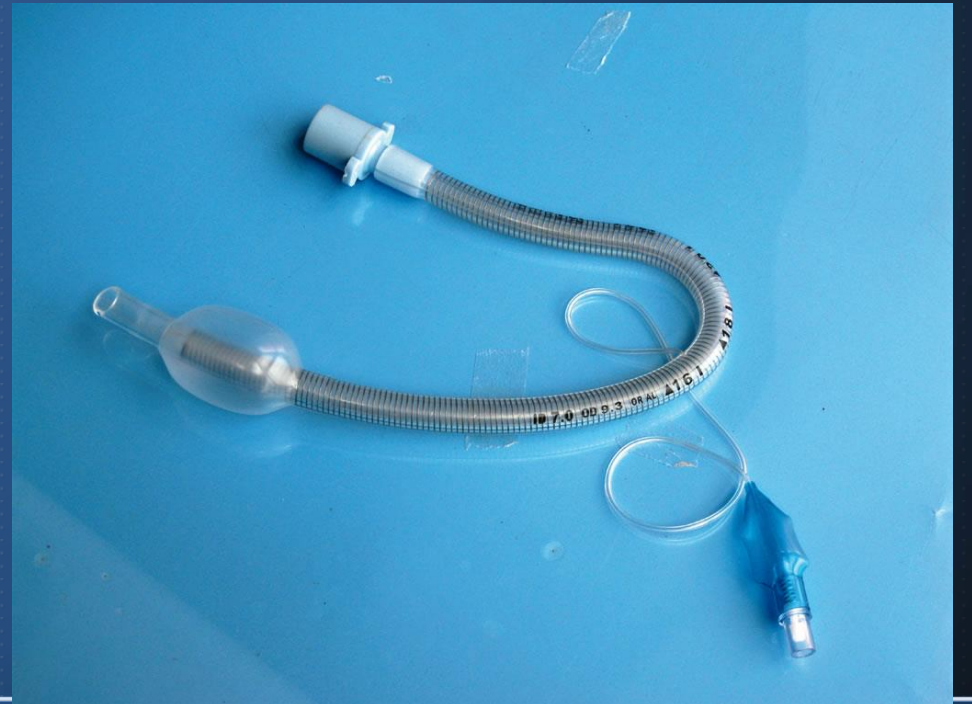Adult female = 6.5-7.5

Children, Size = $(\text{Yrs}+16)/4$

- **Depth :**

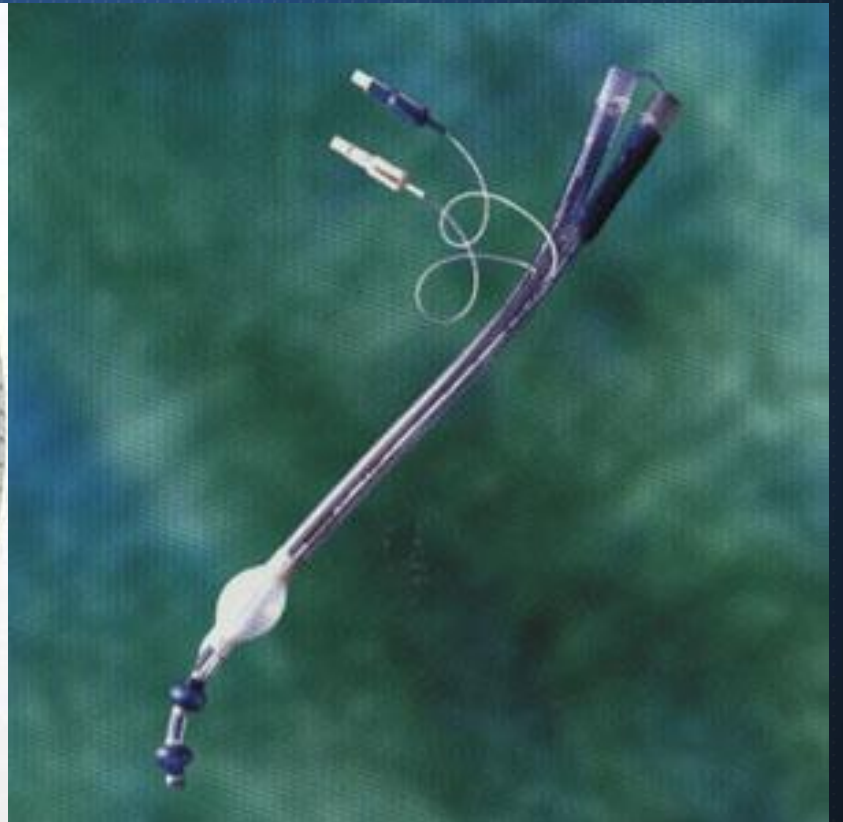
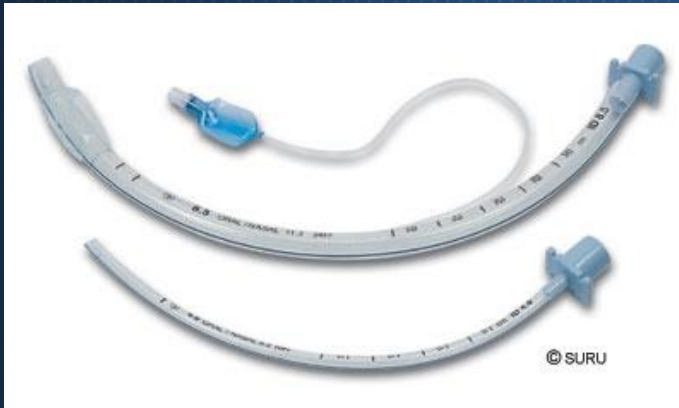
21Cm for women, 23Cm for men

In Children, Depth Cm= $10+\text{Yrs}/2$



Endotracheal Intubation

- **Types of endotracheal tube**



Endotracheal Intubation

- **Indications** : any situation to maintain a patent and safe airway
 - $\text{PaO}_2 \downarrow$, not corrected by conventional oxygen supplement by mask and nasal prongs
 - $\text{PaCO}_2 \uparrow$ or Failure to maintain airway patency
 - Swelling of upper airway : anaphylaxis, infection
 - Facial or neck trauma with OroPharynx bleeding
 - Decreased consciousness and loss of airway reflex
 - Bronchial Toiletting
 - Failure to protect airway aspiration
 - Failure to ventilate
 - General Anesthesia

Charles E et al. In Current Emergency Diagnosis and Treatment. 4th Edi. 1992. SAUNDERS.

Barash PG, Clinical Anesthesia. 1992. Lippincott.

Endotracheal Intubation

- **Contra-Indications :**

- Severe Airway Trauma or Obstruction, that does not permit safe passage of an endotracheal tube. → **Emergency Cricothyrotomy**
- Cervical spine injury need for complete immobilization. → **Fiberoptic intubation**
- Inability to open mouth (e.g. trismus, scleroderma) → **nasal intubation**

Charles E et al. In Current Emergency Diagnosis and Treatment. 4th Edi. 1992. SAUNDERS.

Barash PG, Clinical Anesthesia. 1992. Lippincott.

Endotracheal Intubation

- **Preparing the Precedure : Equipments**

1. Ambu bag & Oxygen line
2. Suction tip
3. Laryngoscope : curved and straight
4. E-tube : size, type
5. Oral airway
6. Stylets
7. Syringe : 10mml
8. Sedative and relaxative drug
9. Lubricant
- 10.gloves

Charles E et al. In Current Emergency Diagnosis and Treatment. 4th Edi. 1992. SAUNDERS.

Barash PG, Clinical Anesthesia. 1992. Lippincott.

Endotracheal Intubation

- **Preparing the Precedure : SALT**
 - **Suction** : remove the oral contents
 - **Airway** : lift the tongue off the post. Pharynx.
 - **Laryngoscope** : confirming the light
 - **Tube** : available size

Charles E et al. In Current Emergency Diagnosis and Treatment. 4th Edi. 1992. SAUNDERS.

Barash PG, Clinical Anesthesia. 1992. Lippincott.

Endotracheal Intubation

- **Induction(sedative) Agent**

- **Etomidate dose- 0.3 mg/kg**

- advantage*- Good for low blood pressure; okay in hypovolemia

- cautions*- Nausea and vomiting on emergence

- Ketamine dose- 1.5 mg/kg**

- advantage*- Good for low blood pressure, hypovolemia; good in asthma

- Caution* in elevated intracranial pressure or heart disease

- Propofol dose- 2-2.5 mg/kg**

- advantage*- Rapid onset and recovery

- Caution* if hypovolemic or risk of hypotension

- Thiopental dose- 3-5 mg/kg**

- advantage*- Multiple drug interactions

- caution* if hypovolemic or risk of hypotension

Charles E et al. In Current Emergency Diagnosis and Treatment. 4th Edi. 1992. SAUNDERS.
Barash PG, Clinical Anesthesia. 1992. Lippincott.

Endotracheal Intubation

- **Muscle relaxant**

- **Succinylcholine dose 1 - 1.5 mg/kg**

- characteristic*- Rapid onset, rapid recovery; fasciculation

- Contraindicated* in hyperkalemia, crush injury, renal failure, extensive burns, elevated intracranial or intraocular pressure

- **Rocuronium dose 0.6- 1.2 mg/kg**

- characteristic*- No fasciculation

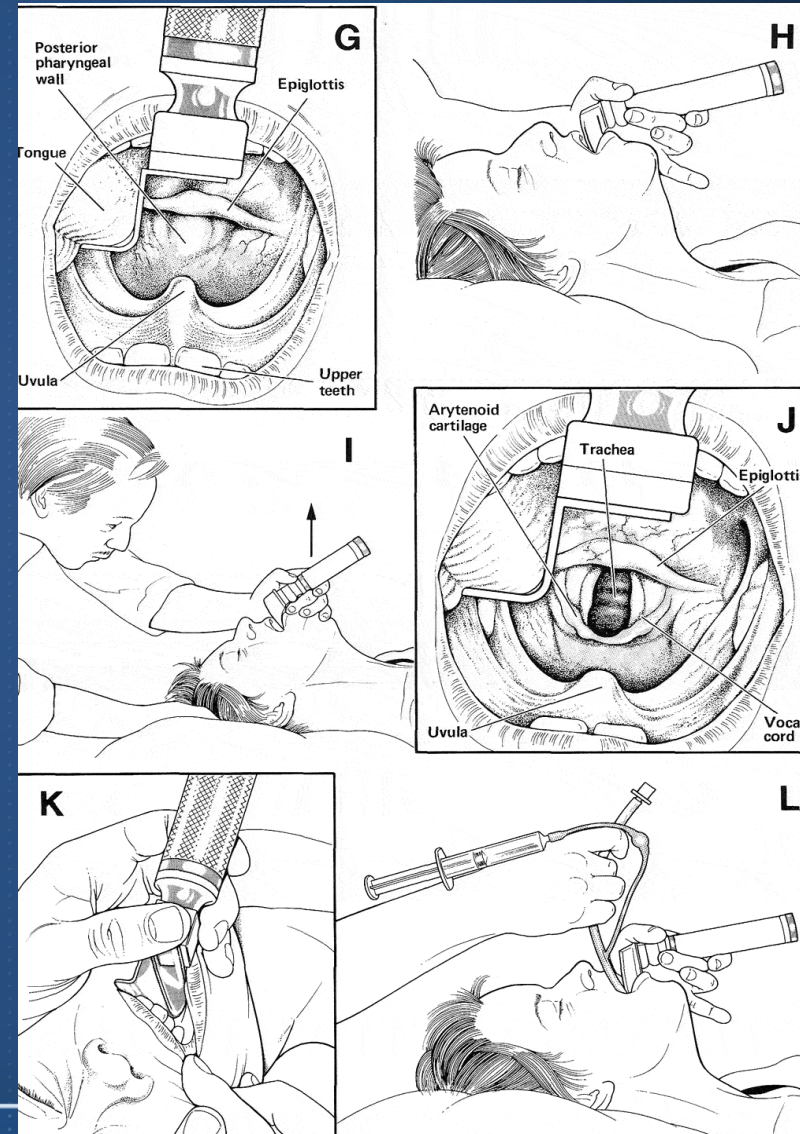
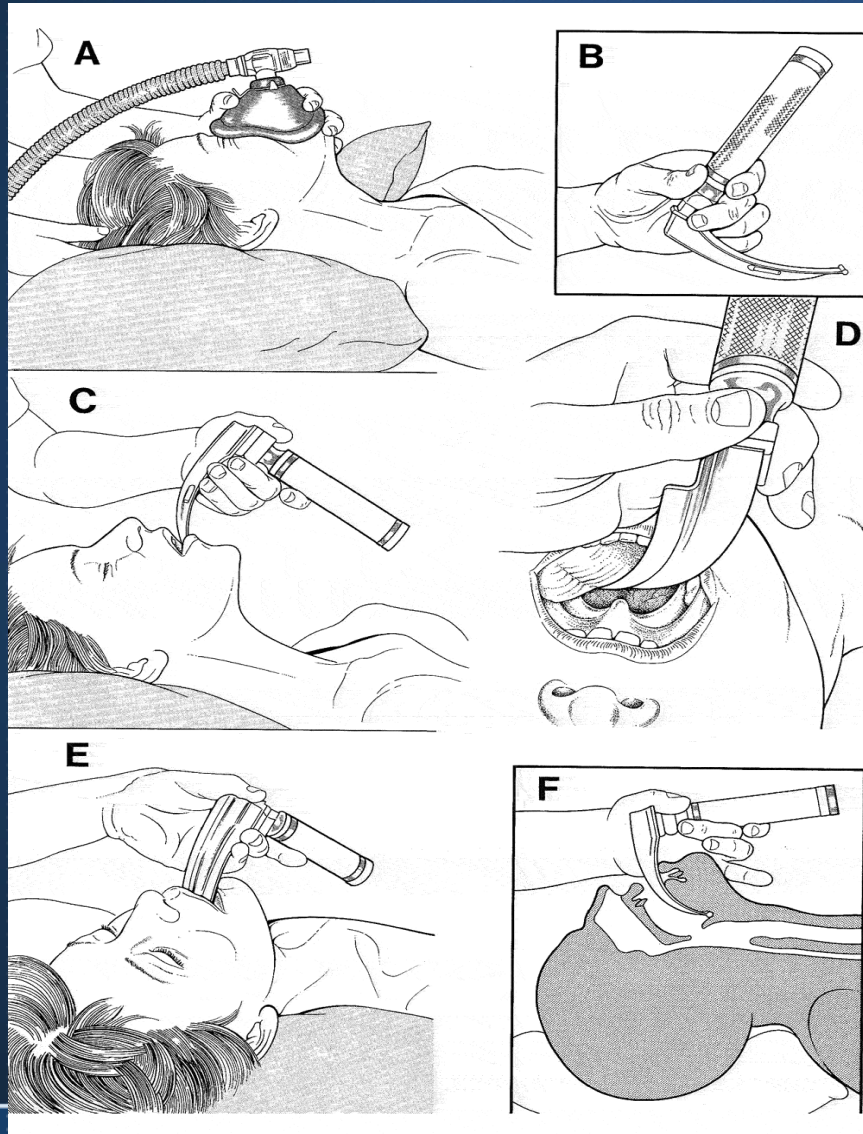
- cautions*- Longer acting-may be problematic if intubation attempt fails

- **Vecuronium dose 0.08 - 0.1 mg/kg,**

- **Atracurium dose 0.4 - 0.5 mg/kg**

Charles E et al. In Current Emergency Diagnosis and Treatment. 4th Edi. 1992. SAUNDERS.
Barash PG, Clinical Anesthesia. 1992. Lippincott.

Endotracheal Intubation



Endotracheal Intubation - complications

- **During intubation**

Laryngospasm

Laceration lips, tongue, pharynx

Dislodgement of teeth

Perforation trachea, esophagus

Cervical spine injury

Haemorrhage

Aspiration gastric content/ FB

Endobrachial or esophageal intubation

Arytenoid cartilages injury

Hypoxemia, hypercarbia.

Bradycardia, tachycardia

Hypertension

Increased ICP or IOP

Endotracheal Intubation - complications

- **Complication with tube in-situ**

Accidental extubation

Endobrachial intubation

Obstruction / kinking

Bronchospasm

Ignation of tube by laser device

Aspiration

Sinusitis

Excoriation of nose or mouth

Endotracheal Intubation - complications

- **Complication after extubation**

Laryngospasm

Aspiration

Glottic,subglottic, uvular edema

Dysphonia,aphonia

Paralysis of vocal cord

Sore throat

Noncardiogenic pulmonary edema

Laryngeal incompetance.

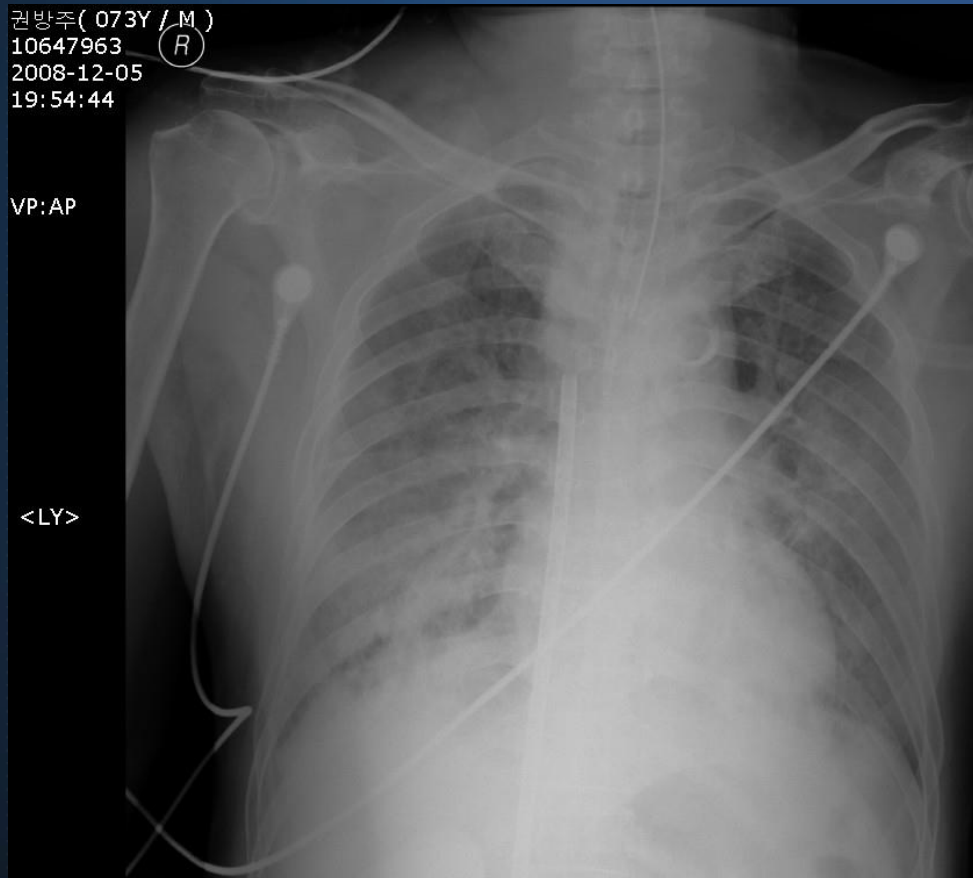
Tracheomalacia

Glottic,subglottic or tracheal stenosis

Vocal cord granulomata

Endotracheal Intubation

- **Verification Of Correct Tube Placement**



KNUH
CR950
Img:1

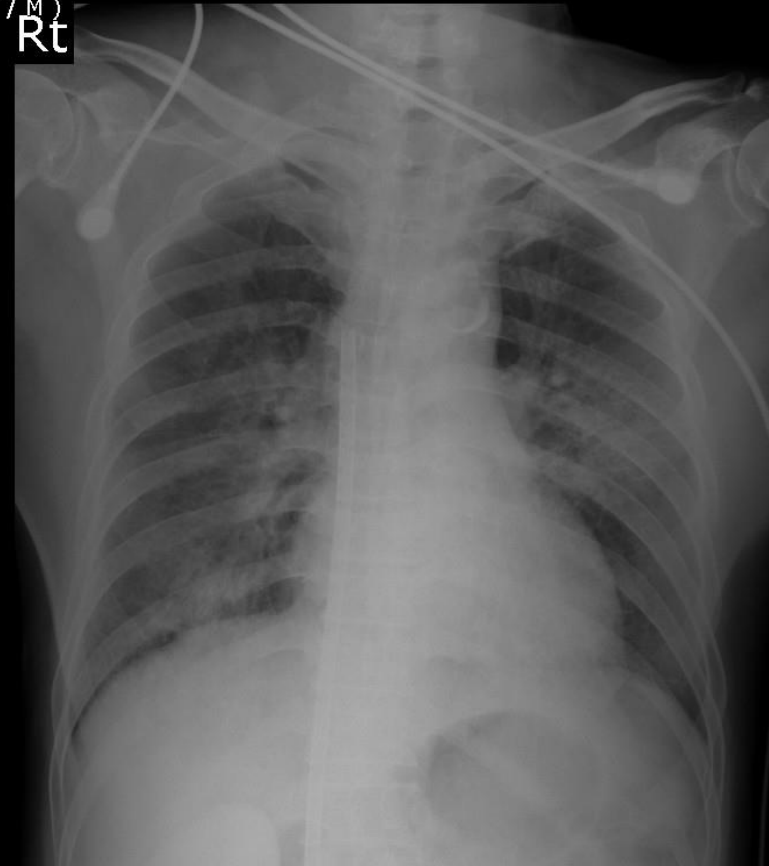권방주 (073Y / M)
10647963
2008-12-07
06:33:29

Rt

VP:AP

<LY>

18 Cm



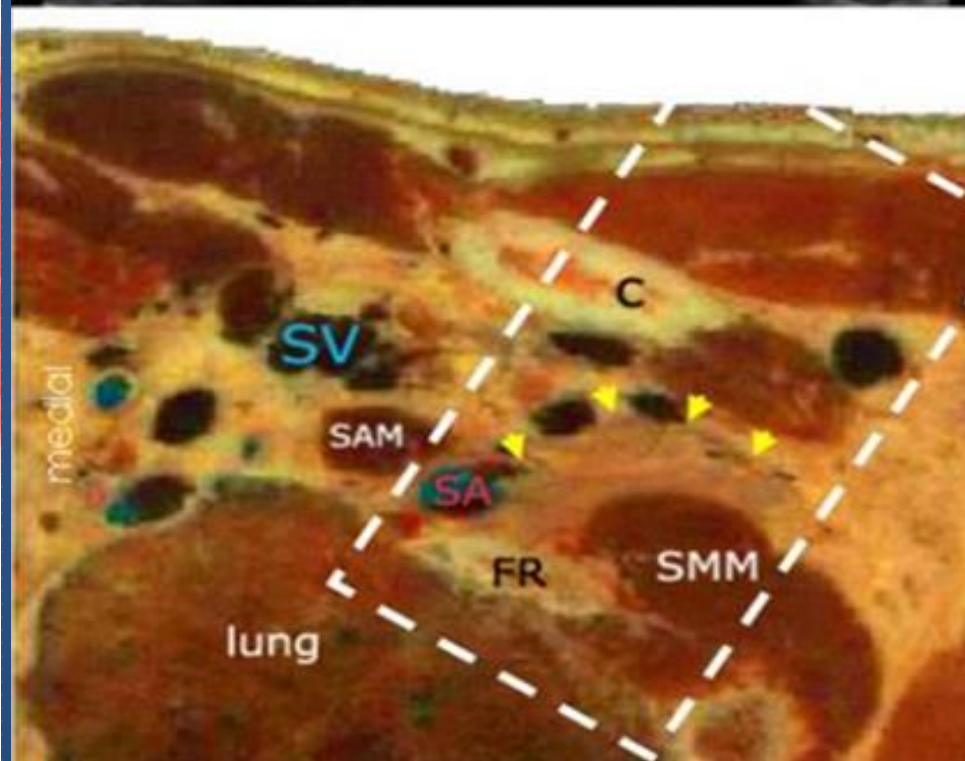
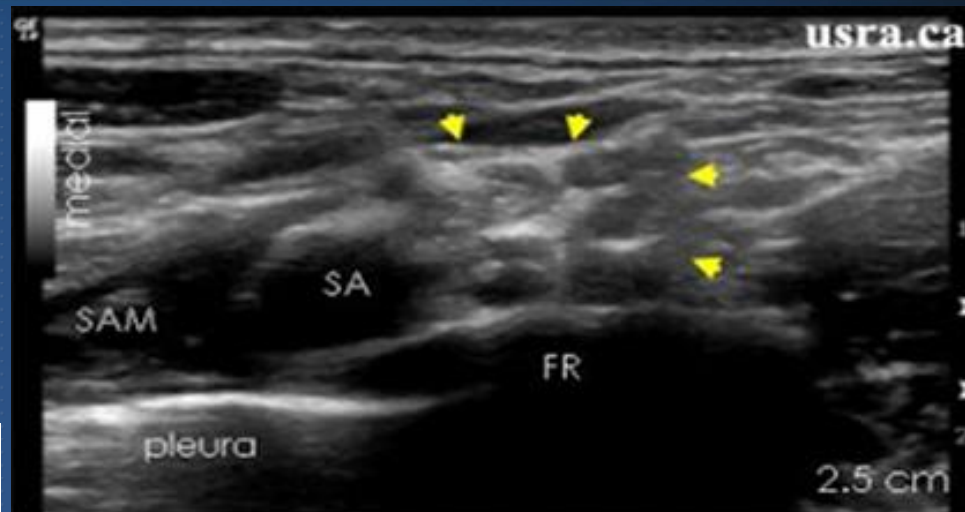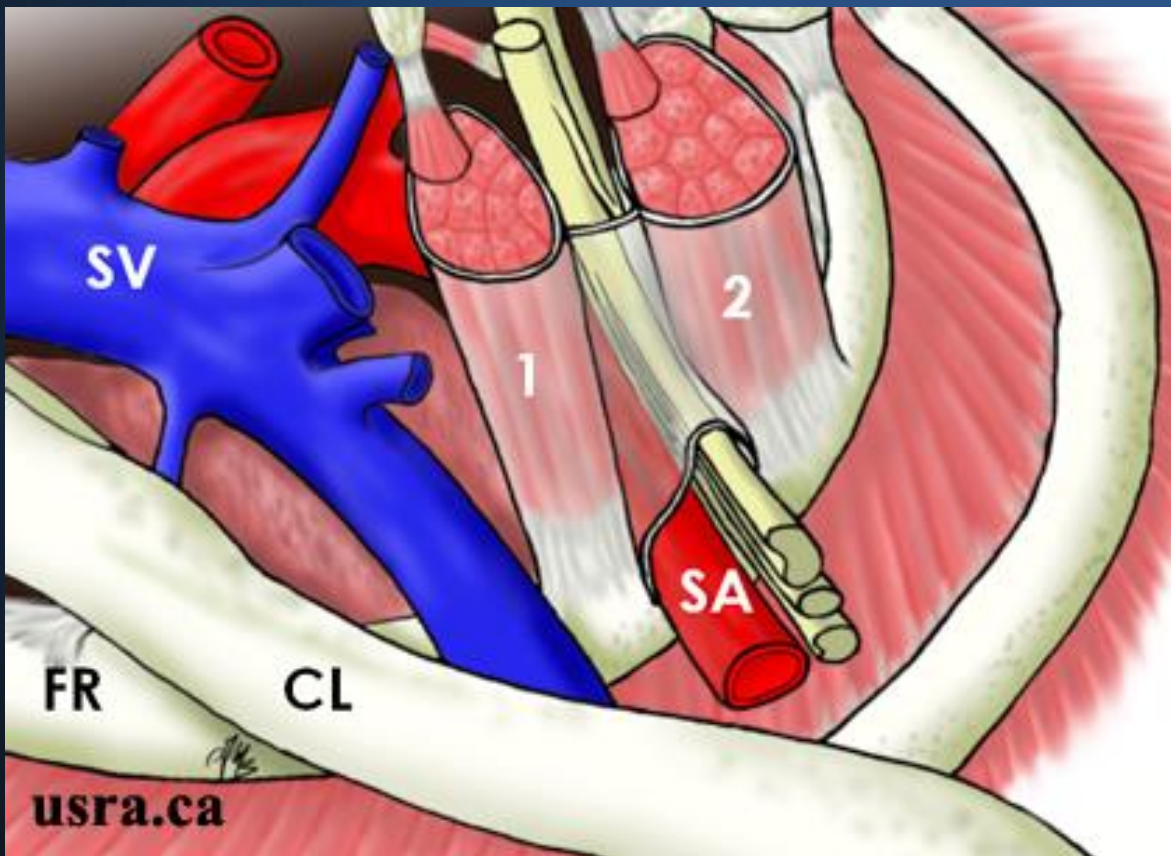
KNUH
CR950
Img:1



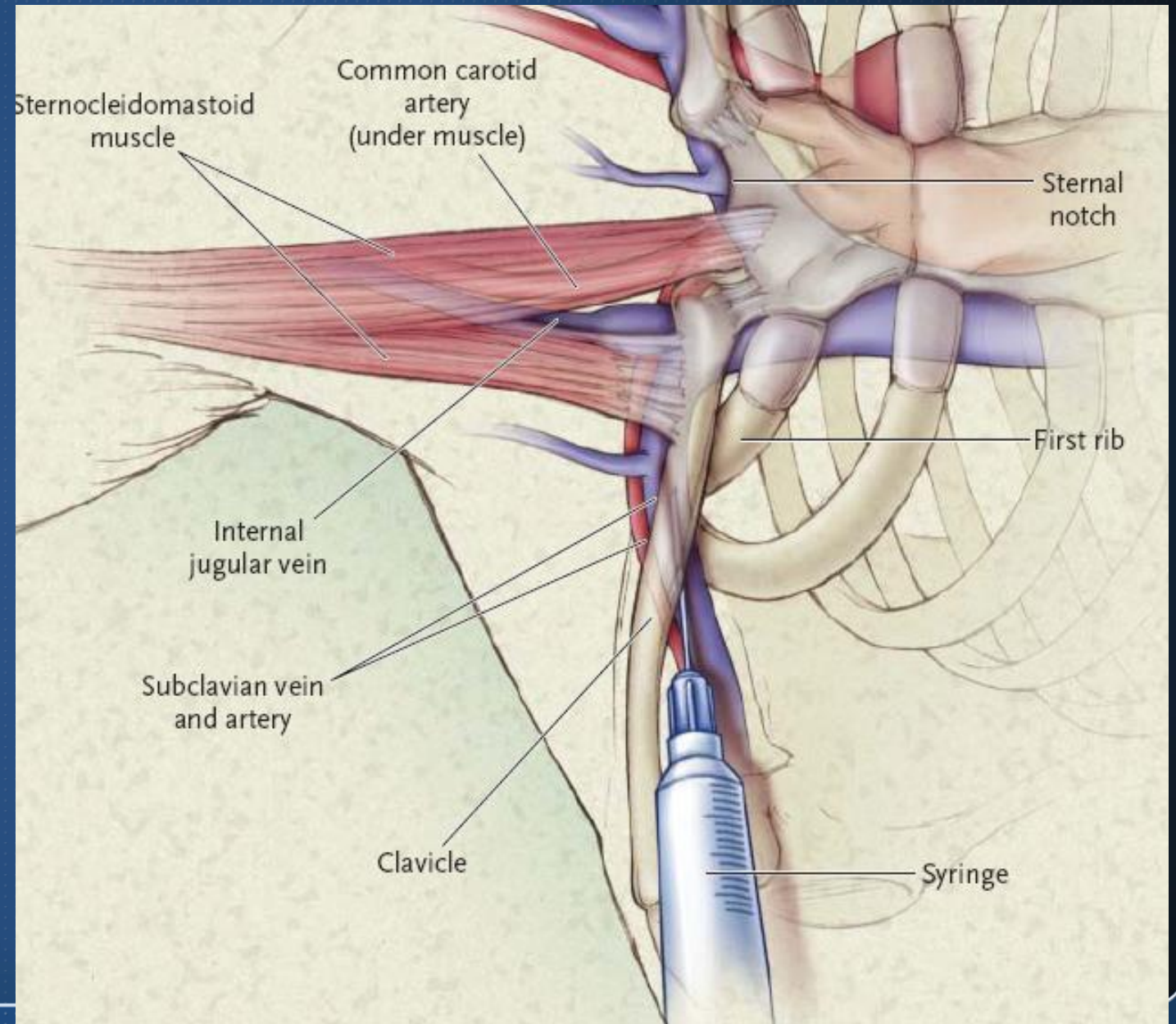
Central Line Insertion

Anatomy

- Subclavian vein, SCV

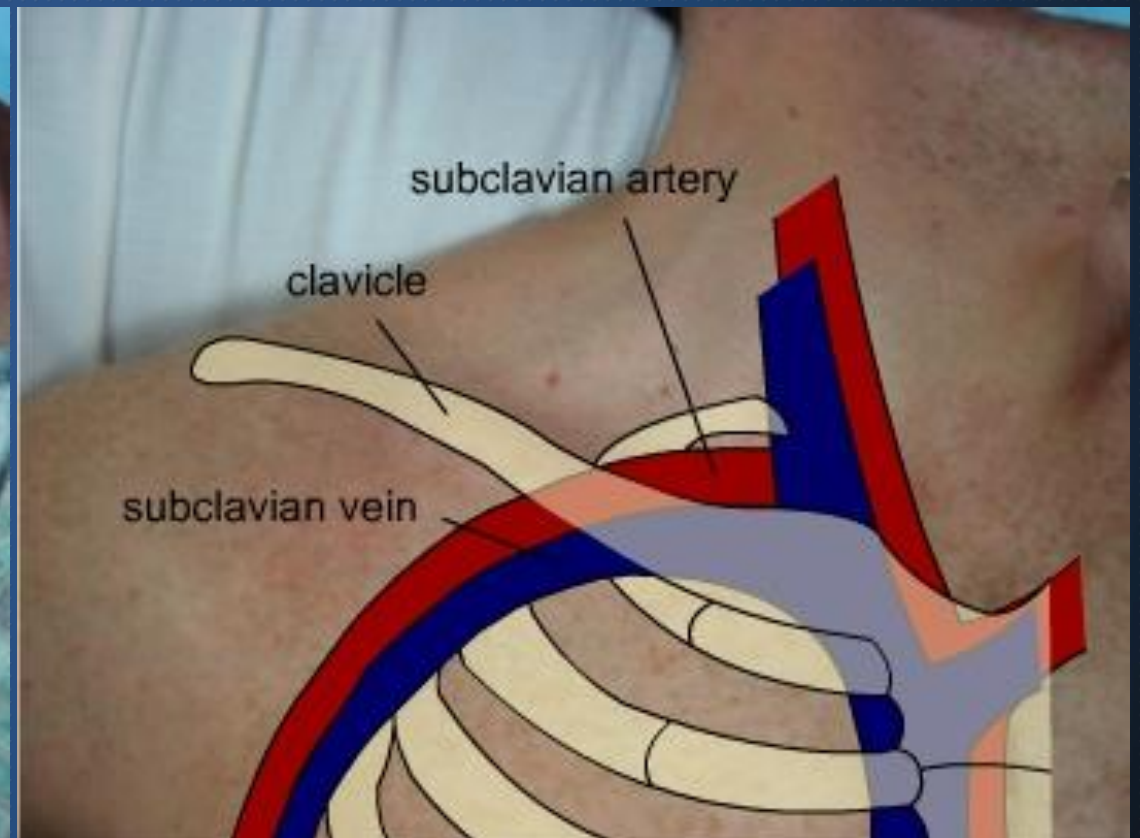
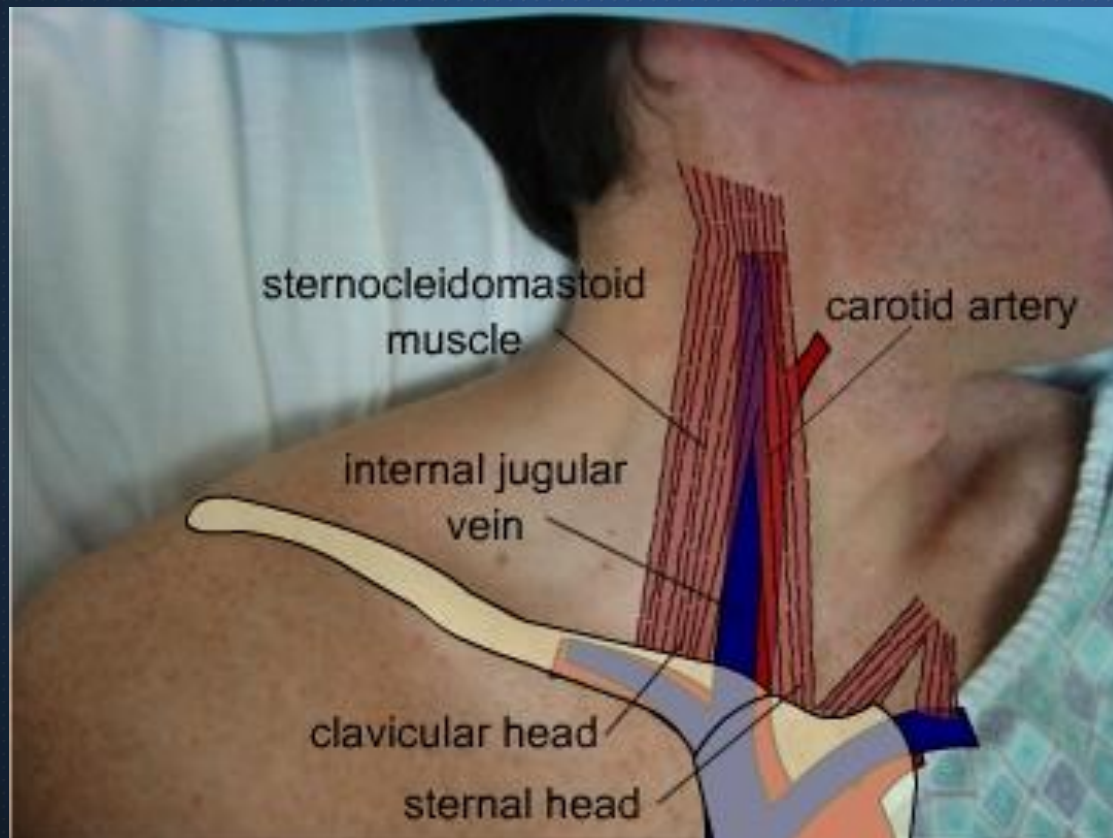


Subclavian vein



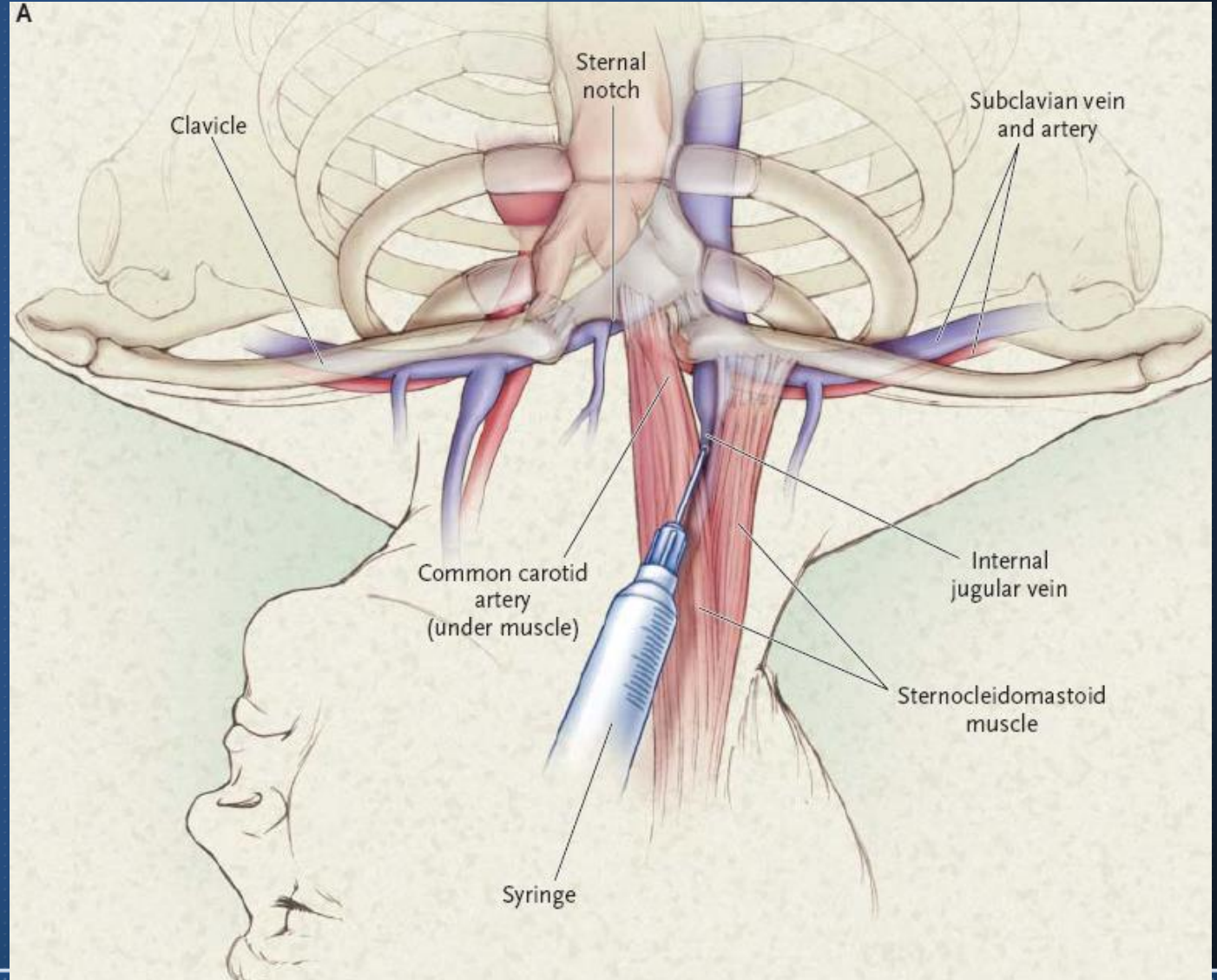
Internal Jugular vein

- Internal Jugular vein



Internal Jugular vein

- **Surface Anatomy**



Internal Jugular vein

- Surface Anatomy

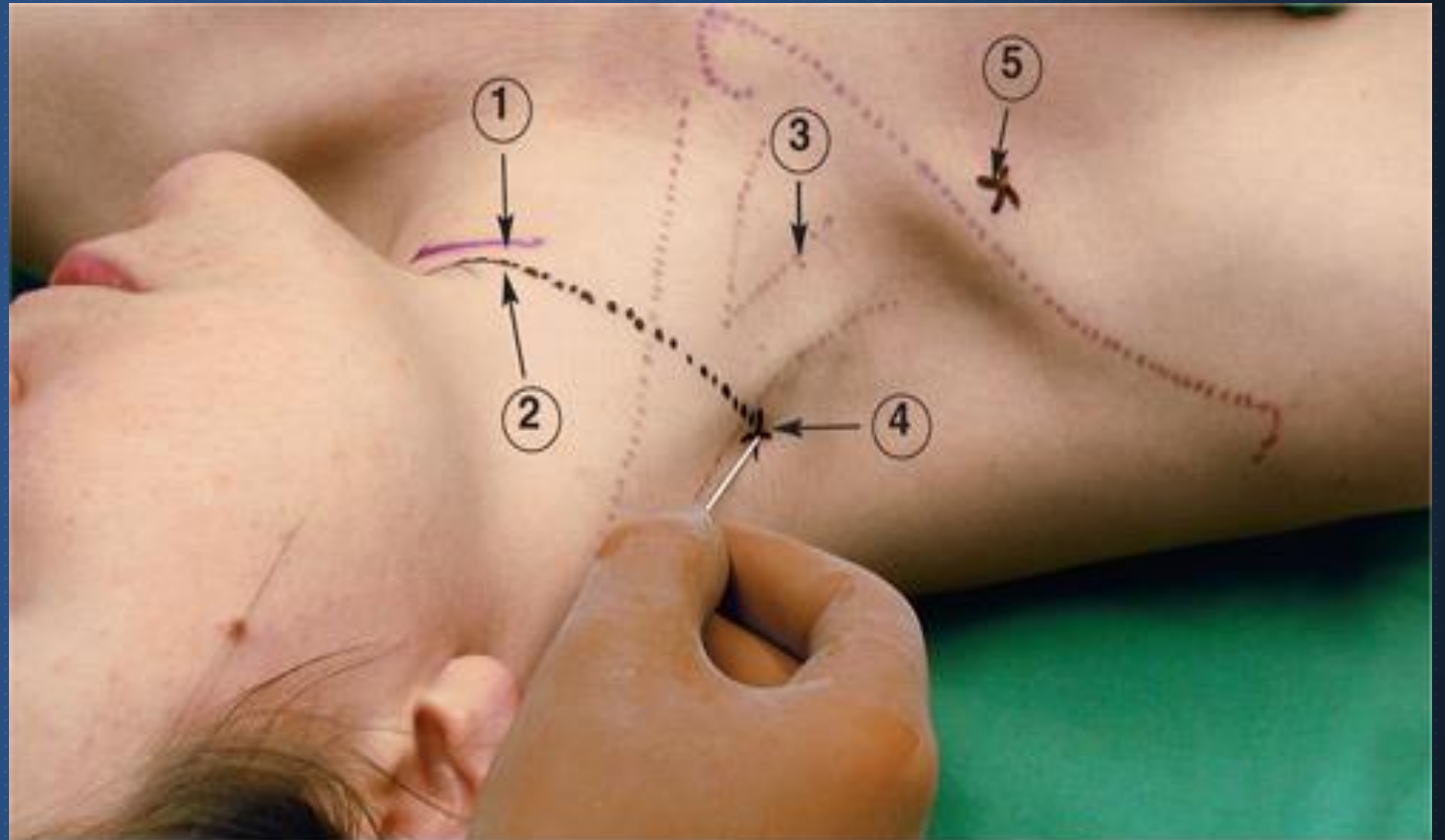
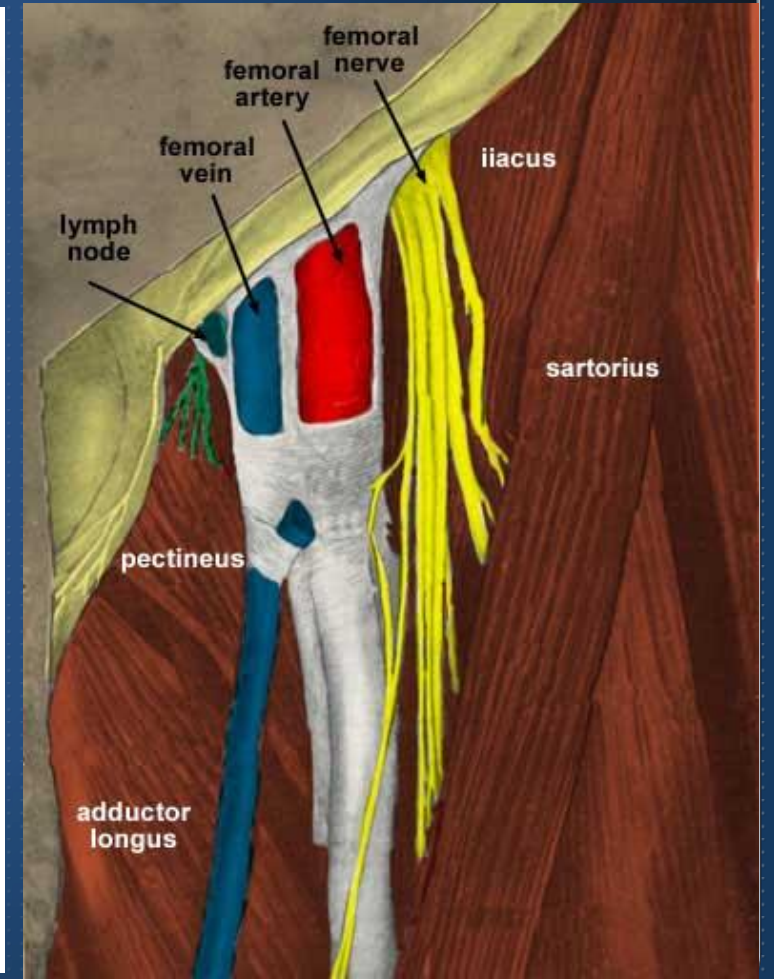
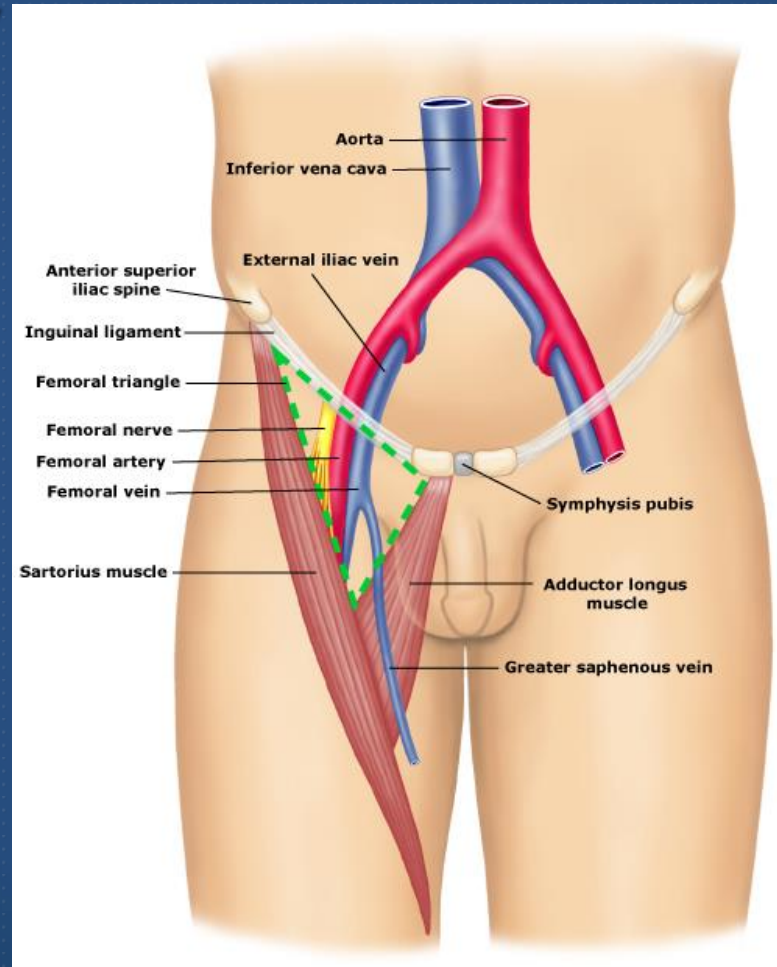


Fig. 11: Interscalene nerve block: Modification according to G. Meier

- | | |
|-------------------------------|--|
| 1. Cricoid | 4. Puncture site for anterior access |
| 2. Superior thyroid notch | 5. Vertical, infraclavicular puncture site |
| 3. Sternocleidomastoid muscle | |

Femoral vein

- Surface Anatomy



Indication of C-line insertion

- **Major Indication**

- Administration of Medication ; vasopressor, chemotherapy, TPN
- Hemodynamic monitoring ; CVP
- Plasmapheresis, hemodialysis, CVVH

- **Minor Indication**

- Poor peripheral access
- Volume resuscitation – large bore cath.
- Frequent blood draw

Contra-Indication of C-line insertion

- **Absolute**

- Peripheral IV access is adequate for the clinical needs of the patient
- Infection over catheter site
- Operator inexperience (unless supervised by an experienced practitioner)
- Uncooperative or combative patients
- Clot in the selected vein

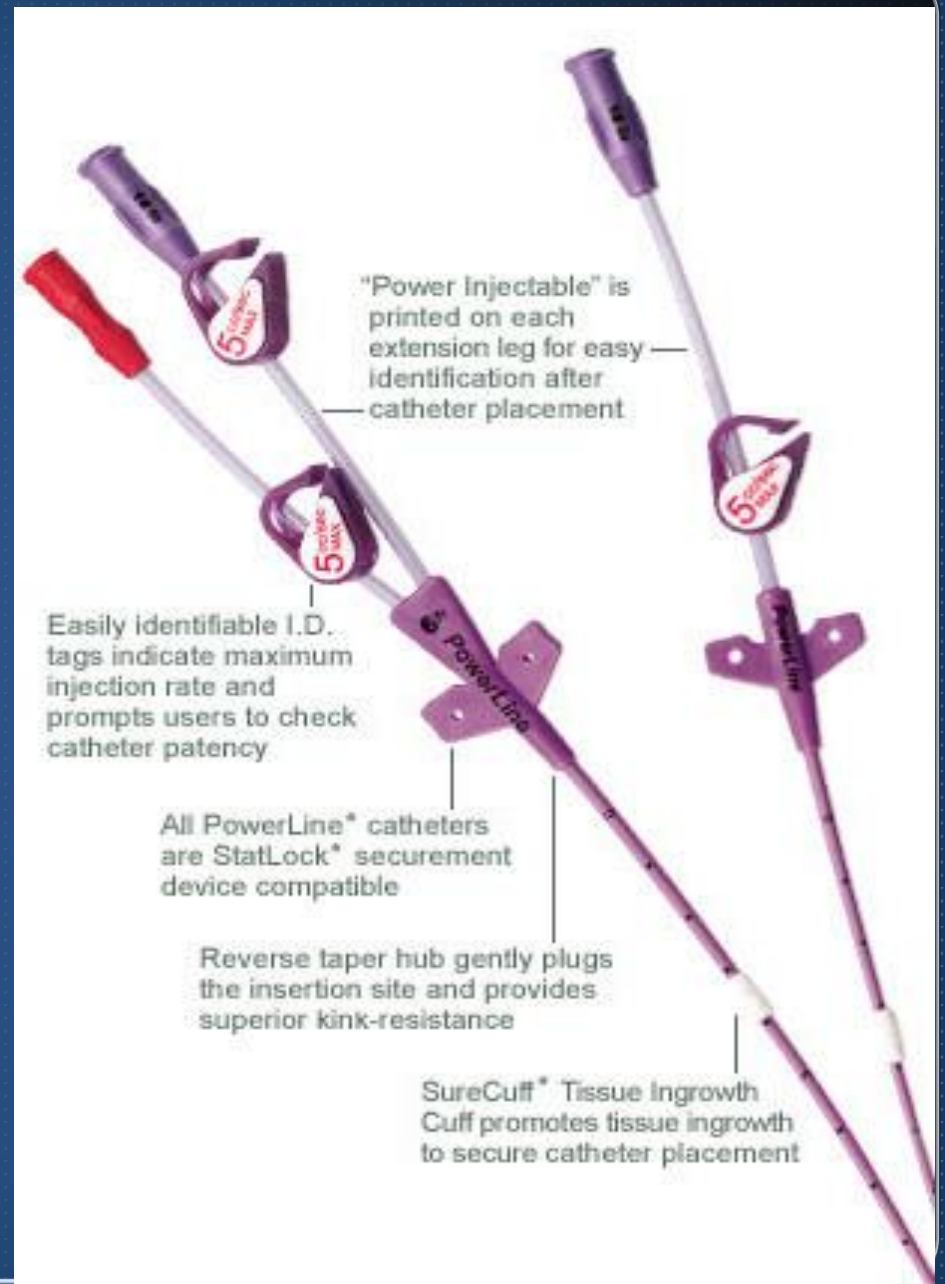
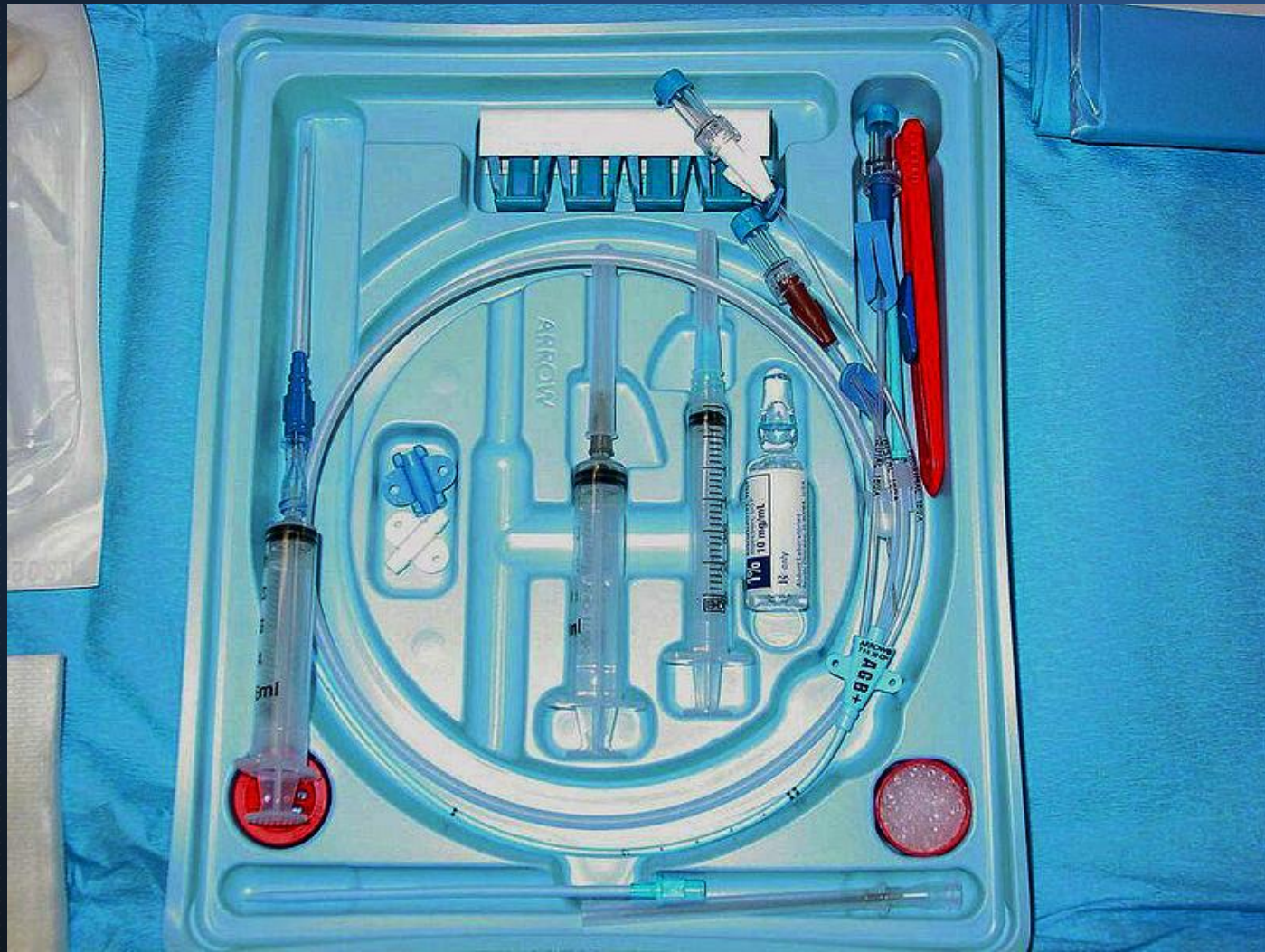
- **Relative**

- Coagulopathy and thrombocytopenia (platelets are $< 50k$ and INR > 1.5)
- Injury or previous surgery to superior vena cava (e.g., superior vena cava syndrome)
- Complications that can be life-threatening (i.e pneumothorax in COPD or bleed).

Site selection

Location	Advantages	Disadvantages
Femoral Vein	Fast, easy, high success rate Does not interfere with Intubation 0% risk of pneumothorax	No CVP monitoring Prevents patient mobilization Higher rates of thrombosis, infection than SCV Femoral artery puncture more frequent than SCV
Internal Jugular Vein	Easy to control bleeding Pneumothorax is less common Straight shot into SVC	Difficult to access (intubation, tracheostomy) Poor landmarks in obese, short neck patients Carotid puncture more frequent than SCV Higher rates of thrombosis than SCV
Subclavian Vein	Most comfortable for patient Bony landmarks in obesity Lowest risk of thrombosis Lowest risk of line infection	Higher risk for pneumothorax Compression of bleeding site difficult Long pass from skin to vein (consider in obesity) Contraindications in lung disease, coagulopathy

Equipment



"Power Injectable" is printed on each extension leg for easy identification after catheter placement

Easily identifiable I.D. tags indicate maximum injection rate and prompts users to check catheter patency

All PowerLine® catheters are StatLock® securement device compatible

Reverse taper hub gently plugs the insertion site and provides superior kink-resistance

SureCuff® Tissue Ingrowth Cuff promotes tissue ingrowth to secure catheter placement

General complications

- Complications during insertion
 - Arterial puncture
 - Pneumothorax
 - Arrhythmias
 - Bleeding, haematoma, haemothorax
 - Damage to thoracic duct, chylothorax
 - Nerve injury
 - Air emboli
 - Catheter shearing/fragment
 - Malplacement
 - Airway obstruction (rare : may be due to large bilateral hematoma)

General complications

- Late complications
 - Infection
 - local
 - systemic
 - endocarditis
 - Thrombosis, thromboembolism
 - Cardiac dysrhythmias
 - Cardiac perforation and tamponade
 - Mediastinitis

General complications

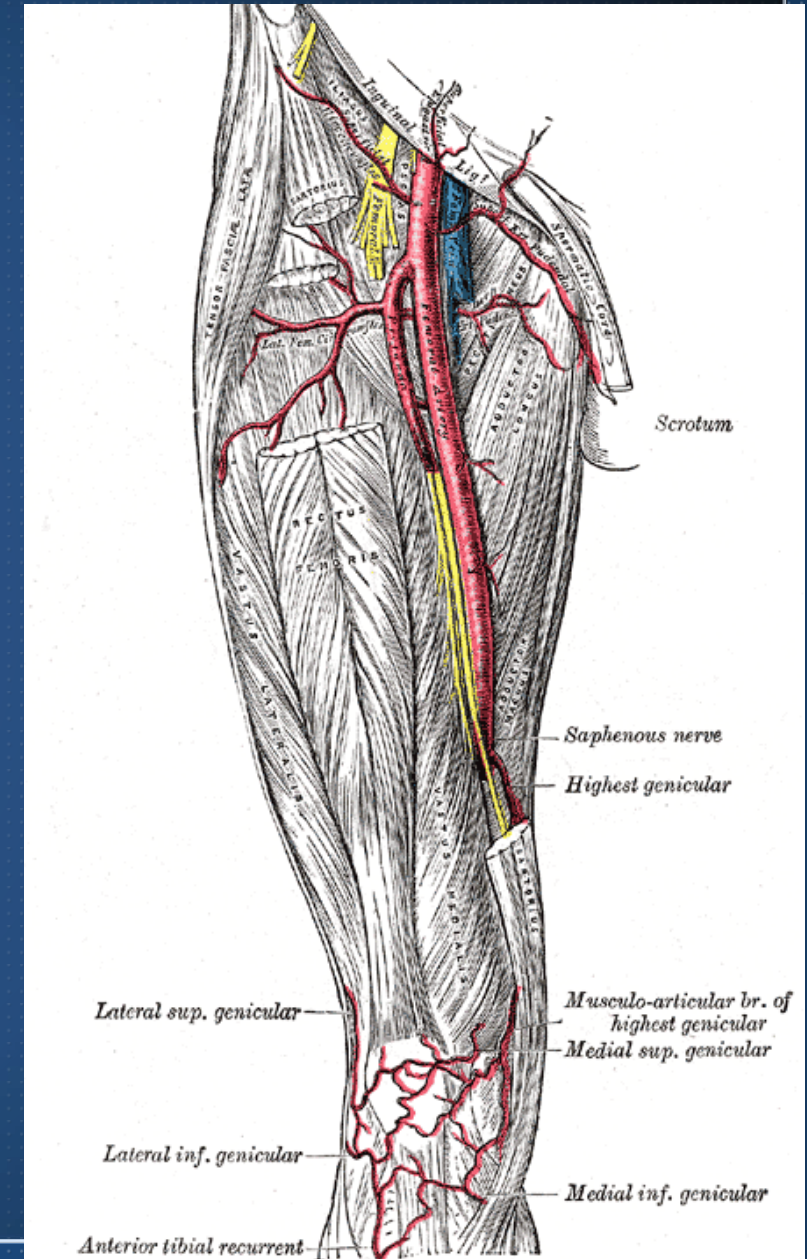
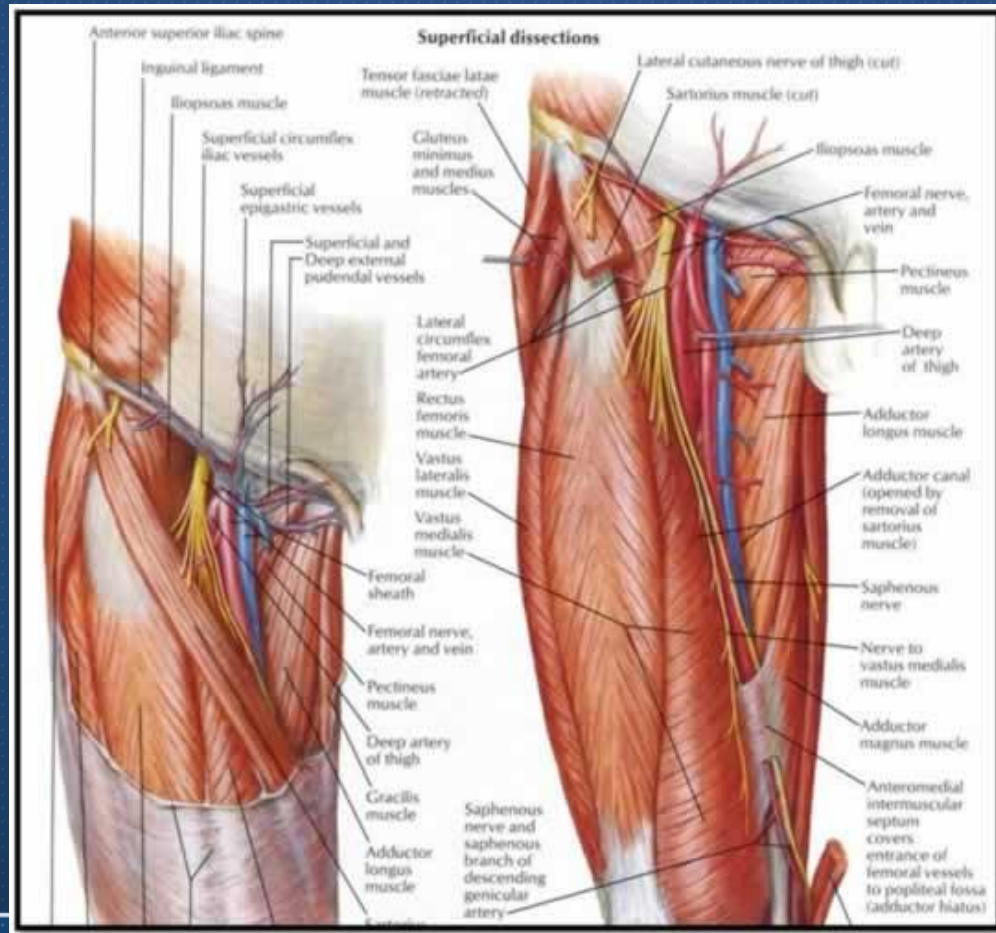
Table 1. Risk of Complications Associated with Internal Jugular, Subclavian, and Femoral Central Venous Catheterization.

Complication	Risk of Complication at Catheterization Site*		
	Internal Jugular Vein	Subclavian Vein	Femoral Vein
Pneumothorax (%)	<0.1 to 0.2	1.5 to 3.1	NA
Hemothorax (%)	NA	0.4 to 0.6	NA
Infection (rate per 1000 catheter-days)	8.6	4	15.3
Thrombosis (rate per 1000 catheter-days)	1.2 to 3	0 to 13	8 to 34
Arterial puncture (%)	3	0.5	6.25
Malposition	Low risk (into inferior vena cava, passing through right atrium)	High risk (crossing to contralateral subclavian vein, ascending internal jugular vein)	Low risk (lumbar venous plexus)

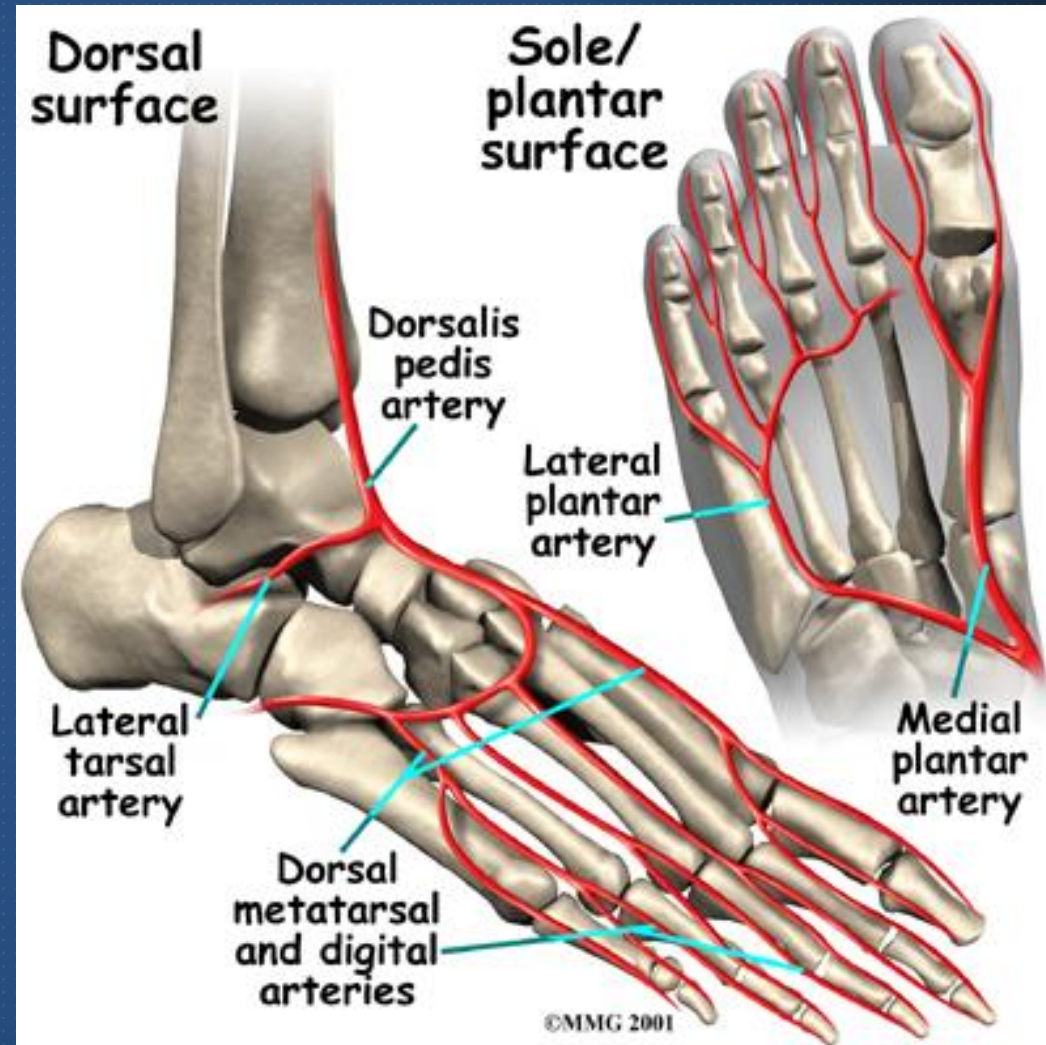
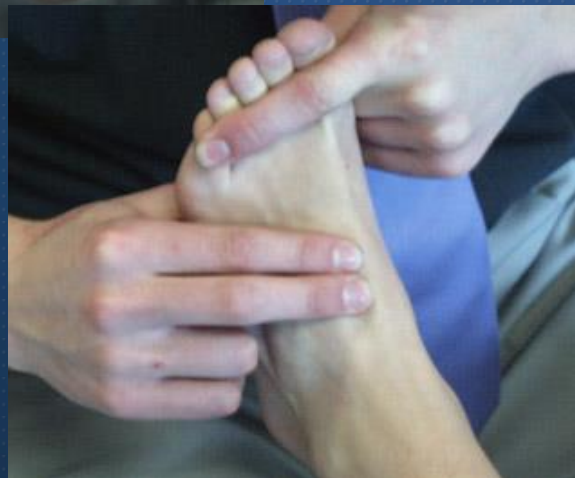
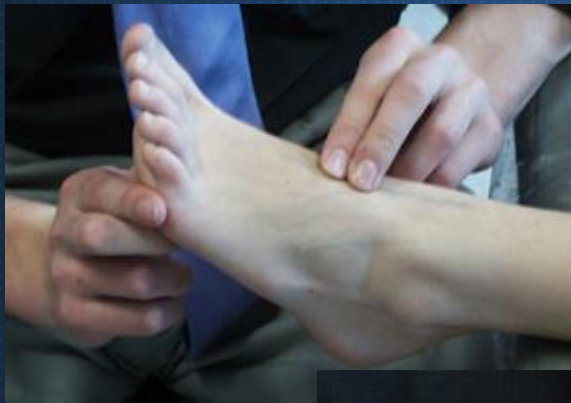
A line insertion

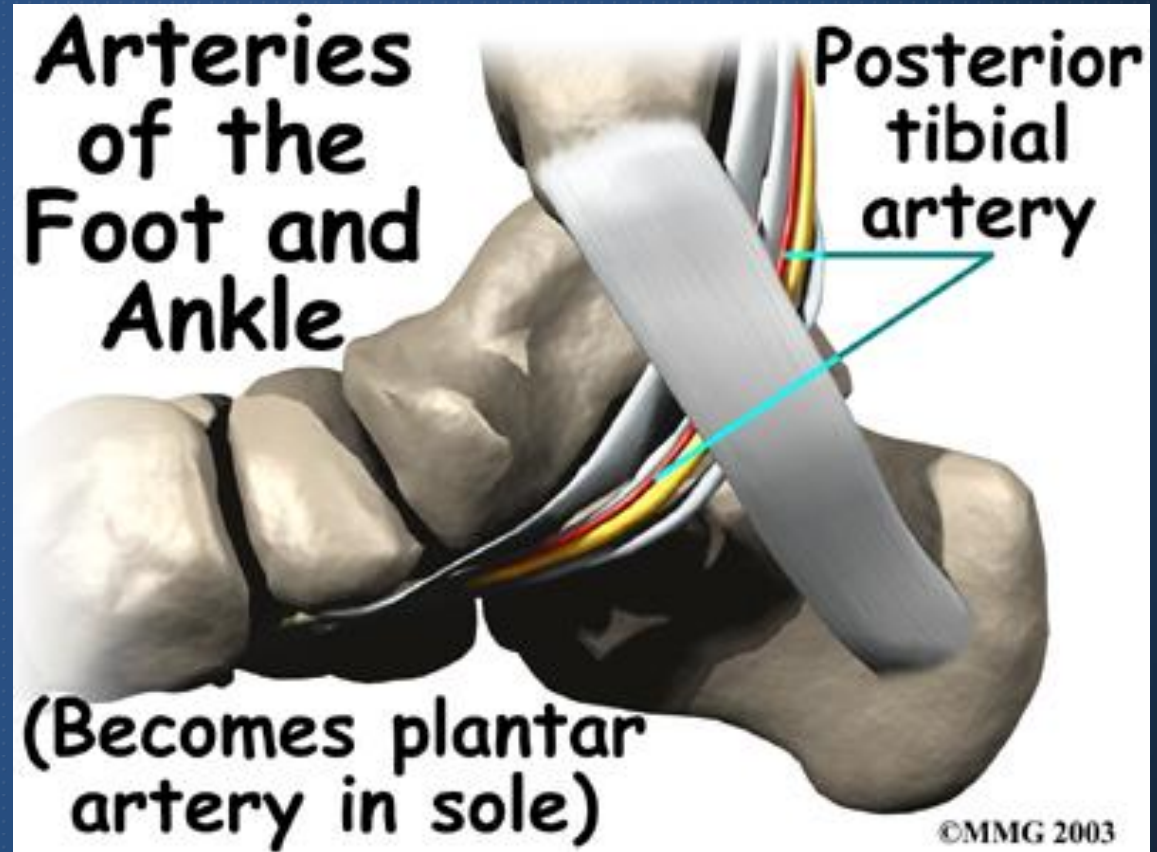
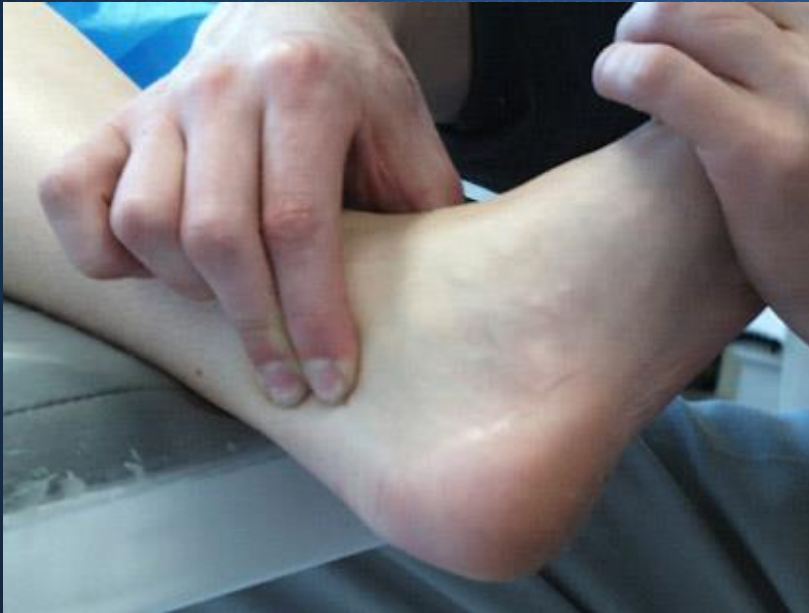- Femoral artery



- **DPA and PTA**



- **DPA and PTA**





Indication of A line insertion

- Frequent ABGA, blood sample
- Consistent monitoring of blood pressure, wave form (IABP)
- Impossible to checking NBP : burn, obesity, multiple trauma

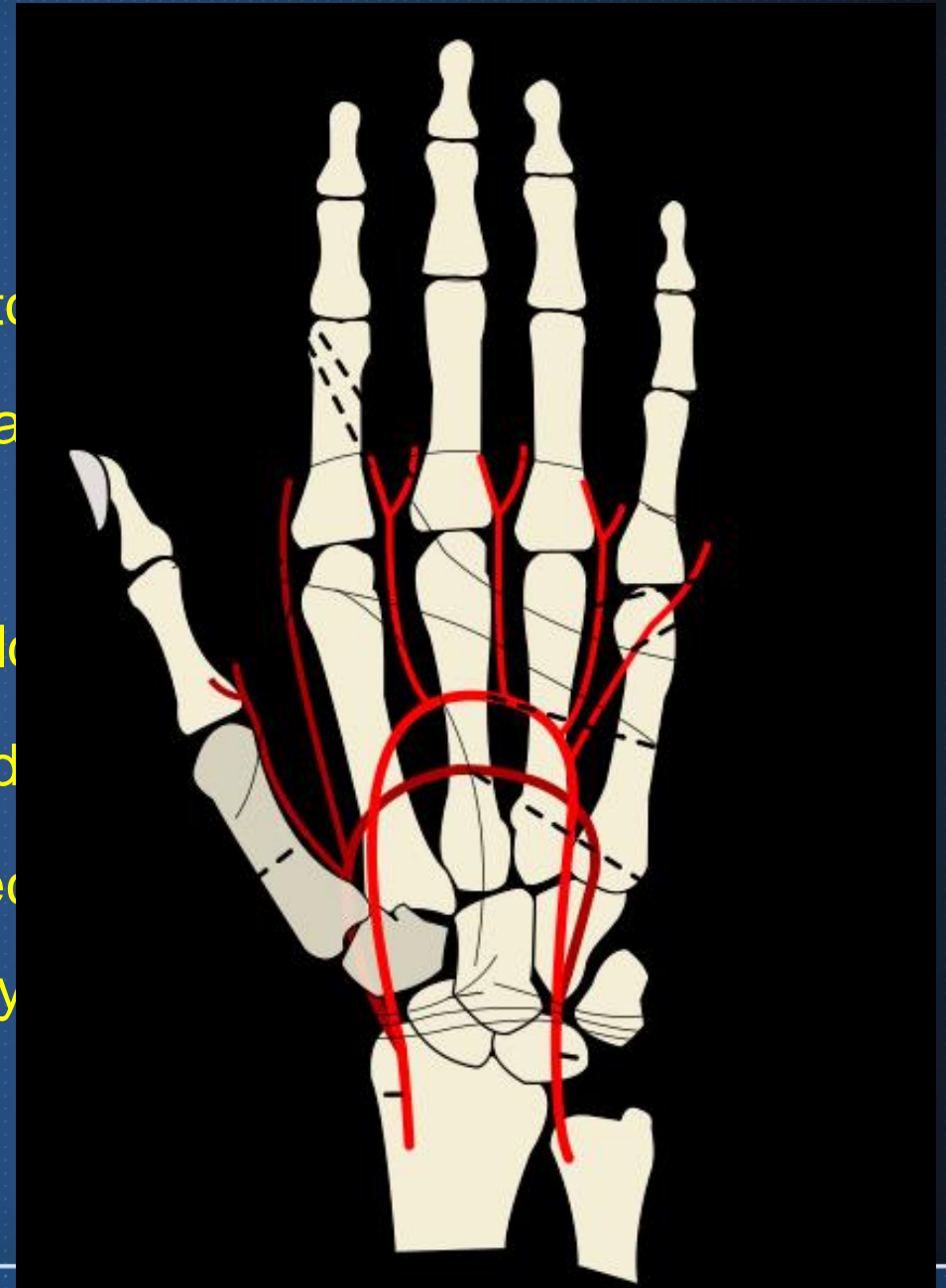


Contra-Indication of A line insertion

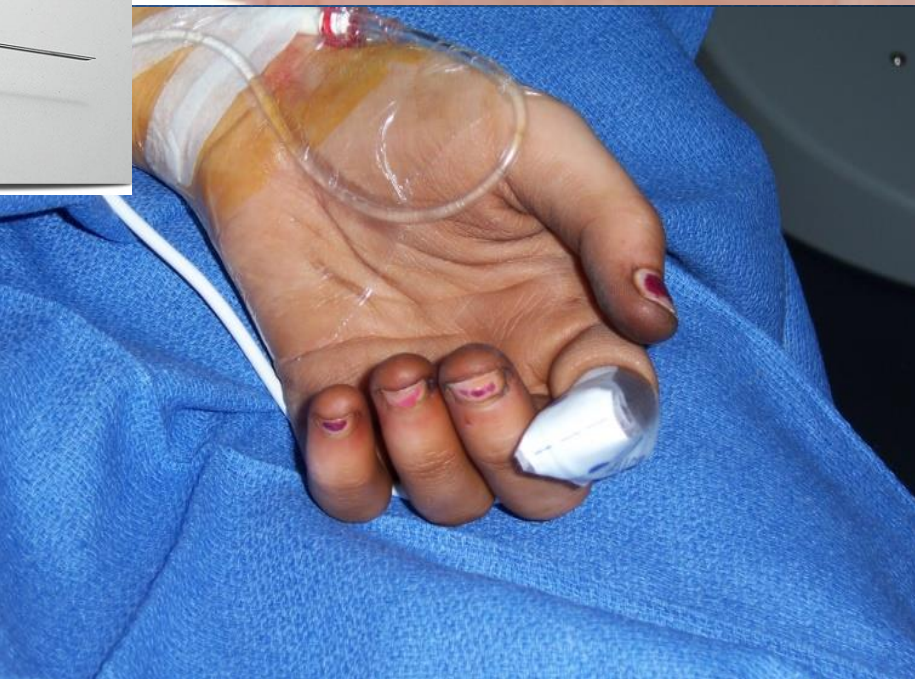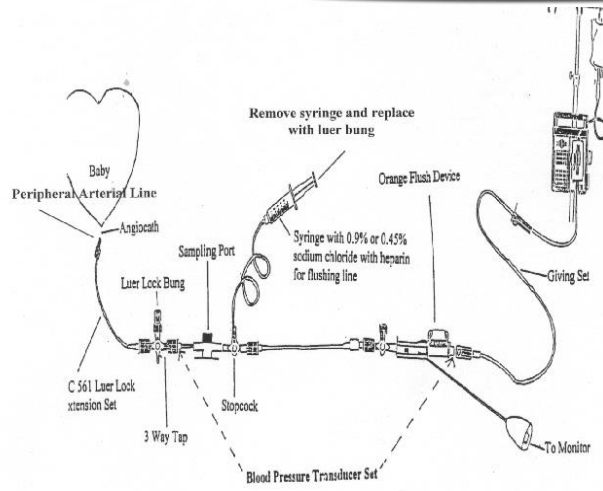
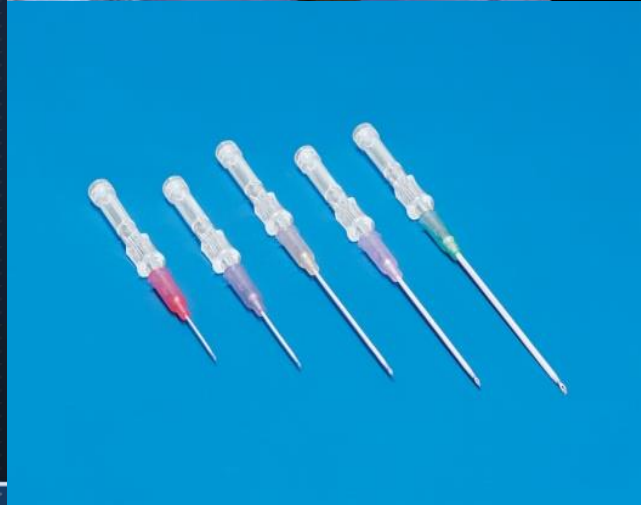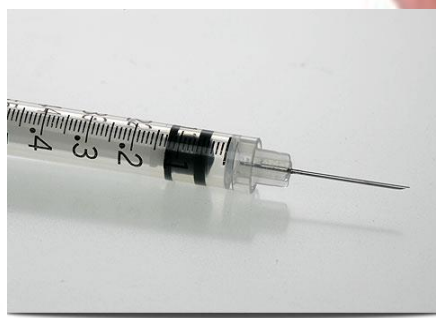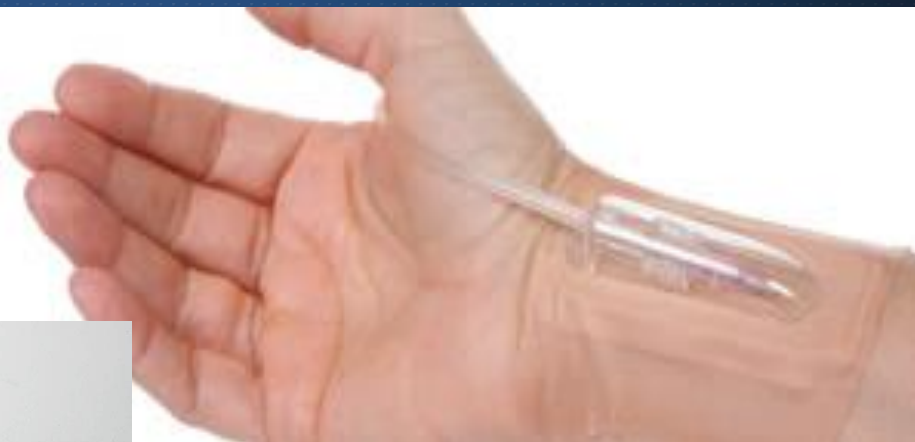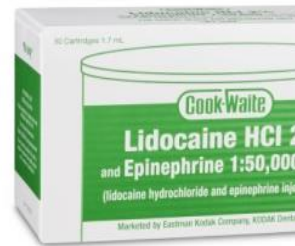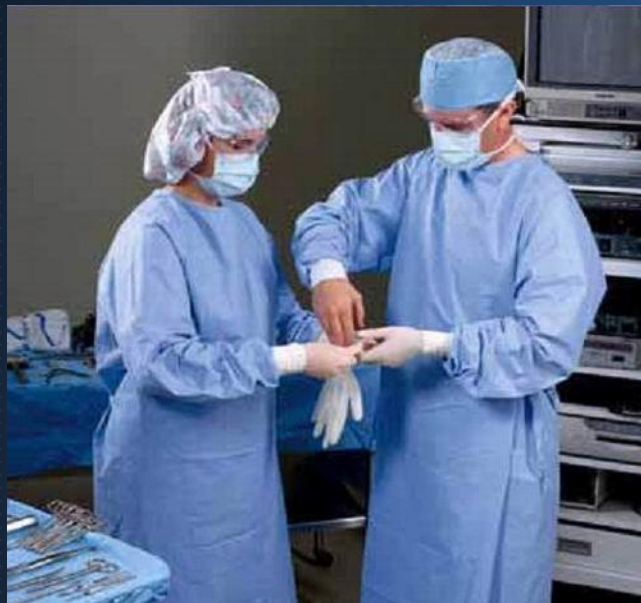- Cellulitis or other infections over the radial artery
- Absence of palpable radial arterial pulse
- Positive Allen test
- Coagulation defects and bleeding tendency

Allen Test

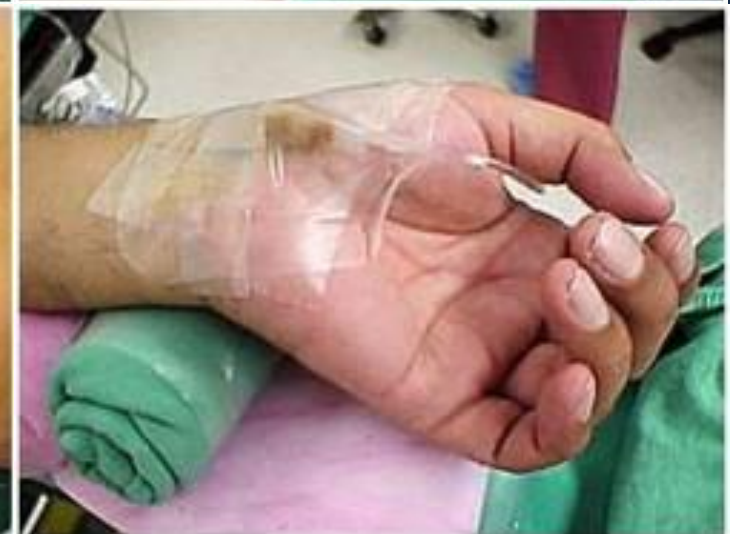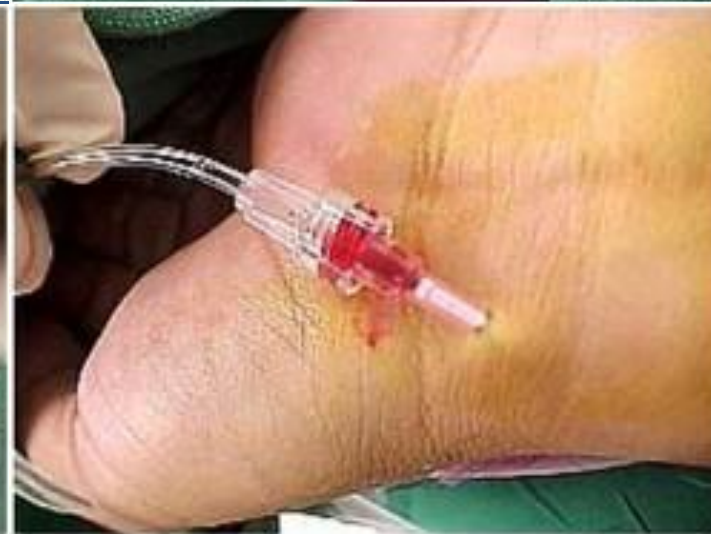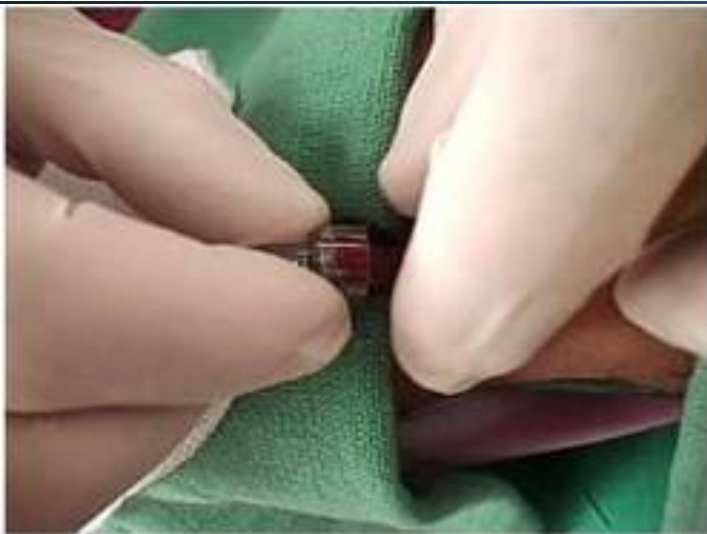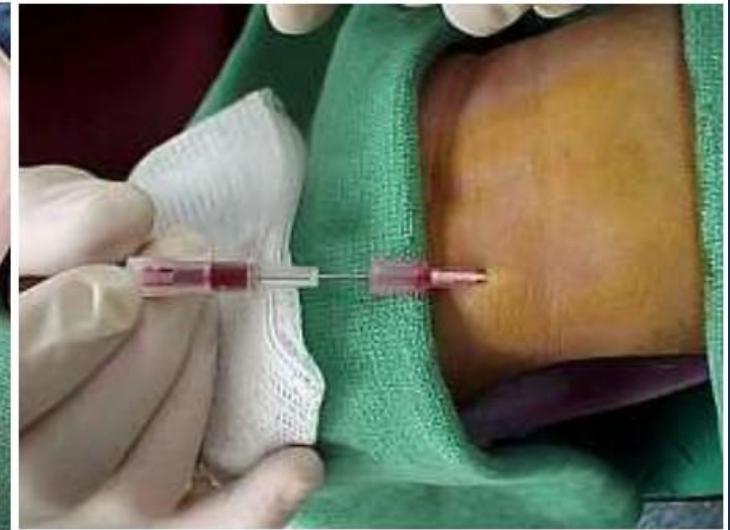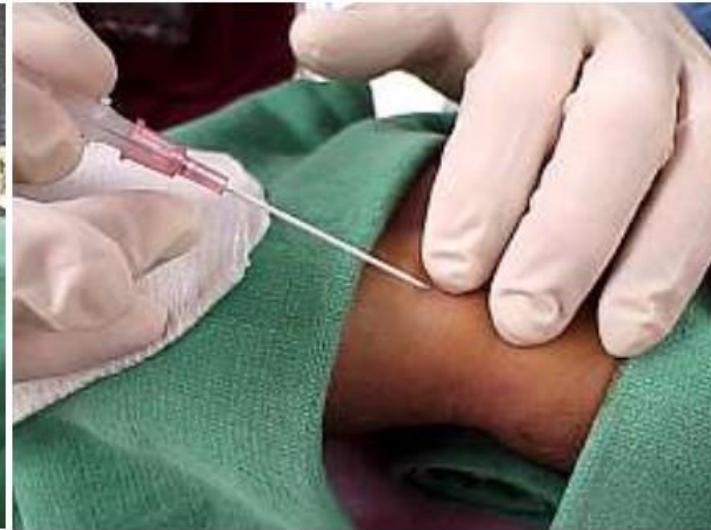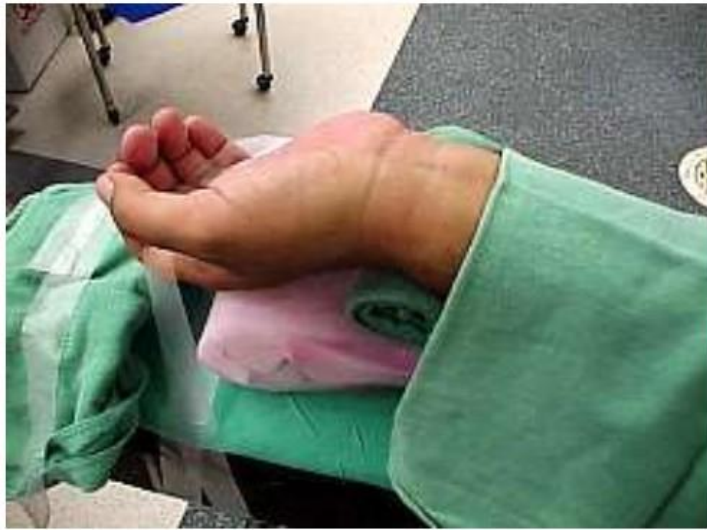1. The hand is elevated and the patient is asked to
 2. Pressure is applied over the ulnar and the radial
 3. Still elevated, the hand is then opened. It should
 4. Ulnar pressure is released and the color should
 5. If color does not return or returns after 7–10 sec
- to the hand is not sufficient and the radial artery
pricked/cannulated



Equipment



Equipment



Complications

- Rare fatal complication (less than 1%)
 - Ischemia :
 - PAD,
 - indwelling time,
 - Pseudoaneurysm
 - Hematoma
 - Nerve injury
 - Infection



Closed thoracostomy



Indication of chest tube insertion

- **Drainage and Lung expansion**
 1. Pneumothorax
 2. Malignant pleural effusion
 3. Empyema, Complicated parapneumonic effusion.
 4. Traumatic hemopneumothorax
 5. Post thoracotomy

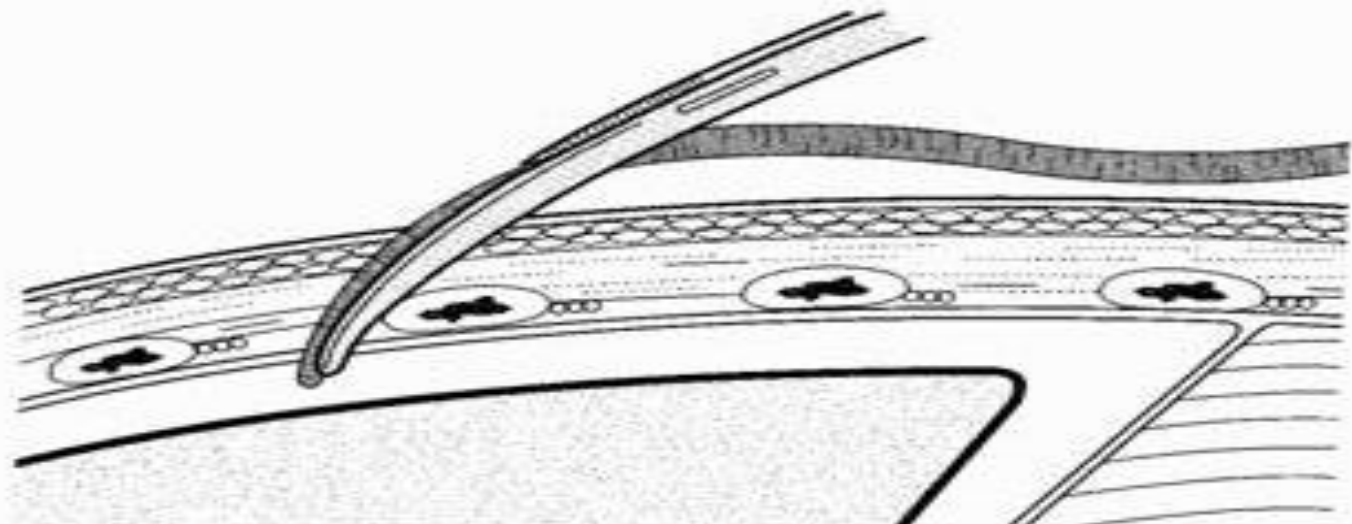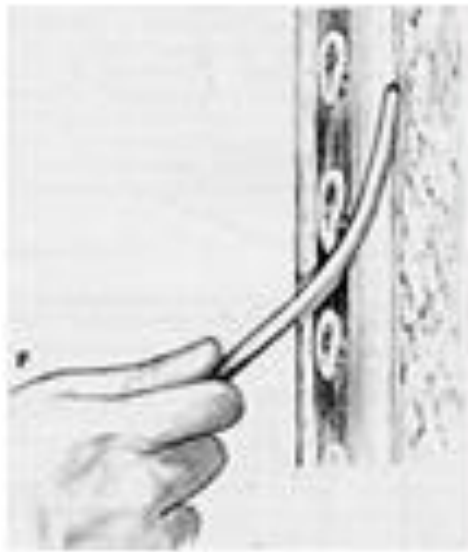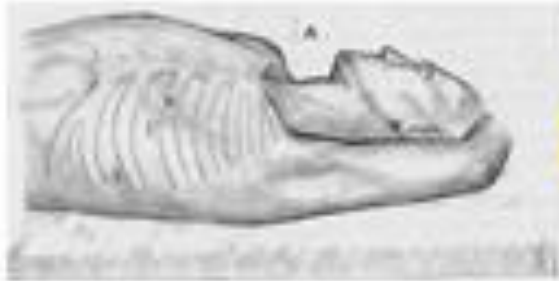Contra-Indication of chest tube insertion

- **no absolute Cix, if pt in respiratory distress**
 1. Infection over insertion site
 2. Uncontrolled bleeding diathesis
- **Never forget caution when the pt has**
 - * **Obesity**
 - * **Adhesion possibility**
 - * **Giant bullae**
 - * **LVH**

Equipment

1. Gowning and Scrubbing
2. Confirm Chest film or CT
3. Patient positioning – Supine, Lateral decubitus, Sitting position
4. Target point marking (4th, 5th, 6th ICS MAL → lateral line of Nipple)
5. Skin scrubbing
6. Diagnostic thoracentesis and Lidocain insertion (ETF and Parietal Pleura)
7. 2-3Cm transverse incision
8. Blunt dissection
9. Tube insertion using hemostat (advance the tube superiorly and posterioly)
10. Connect tube to under water seal
11. Wound closure
12. Dressing
13. Confirm Chest film

Procedure





Complications

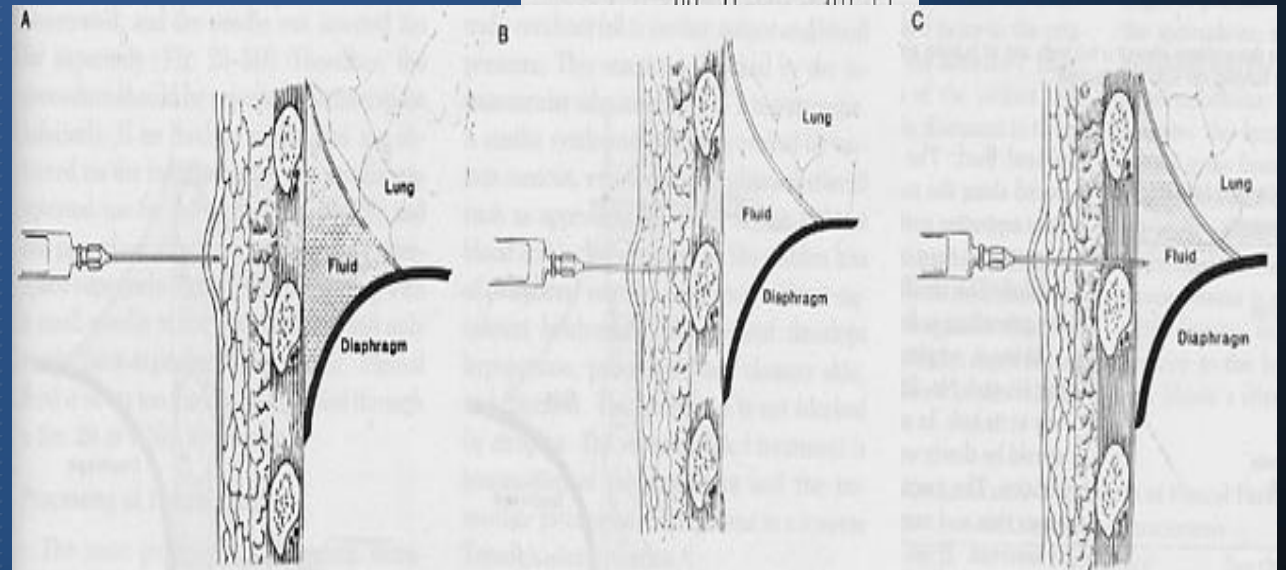

1. Malposition – Abdominal cavity (liver, spleen, diaphragm injury)
2. Insertion into pulmonary parenchyma
3. Mediastinal organ injury (Left Ventricle)
4. Intercostal neurovascular Injury (pain, bleeding)



Thoracentesis

Procedure

- Damage of intercostal vessel or nerve
- Lung parenchymal damage
- Diaphragm or intra-abdominal puncture
- **Complication of thoracentesis**
 - Pneumothorax / lung laceration
 - hemothorax
 - Infection, contamination of pleural space
 - shock vasovagal reflex, pain shock
 - splenic or hepatic laceration



고진감래

[苦盡甘來]

고생이 다하면 즐거움이 찾아온다

