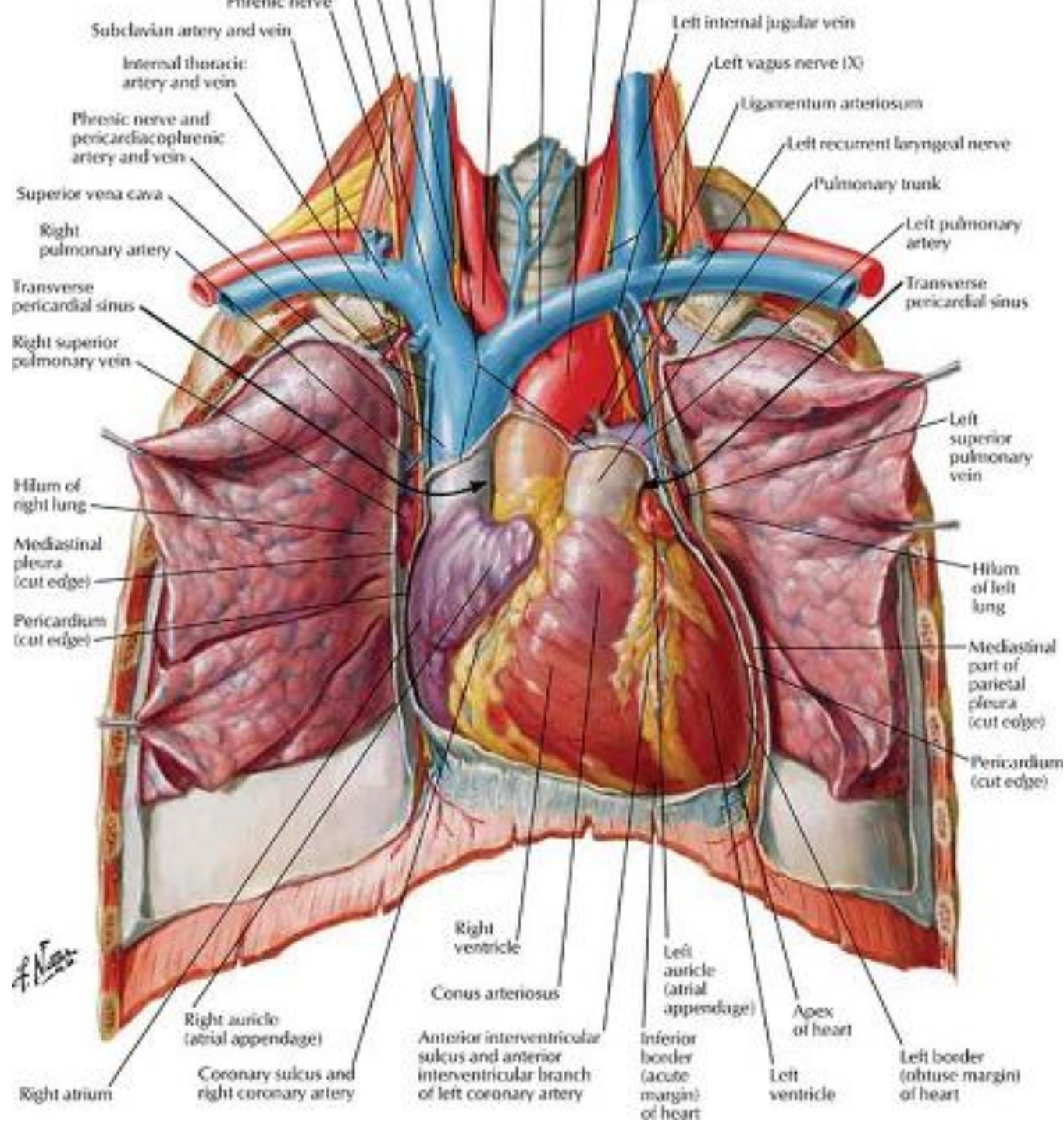


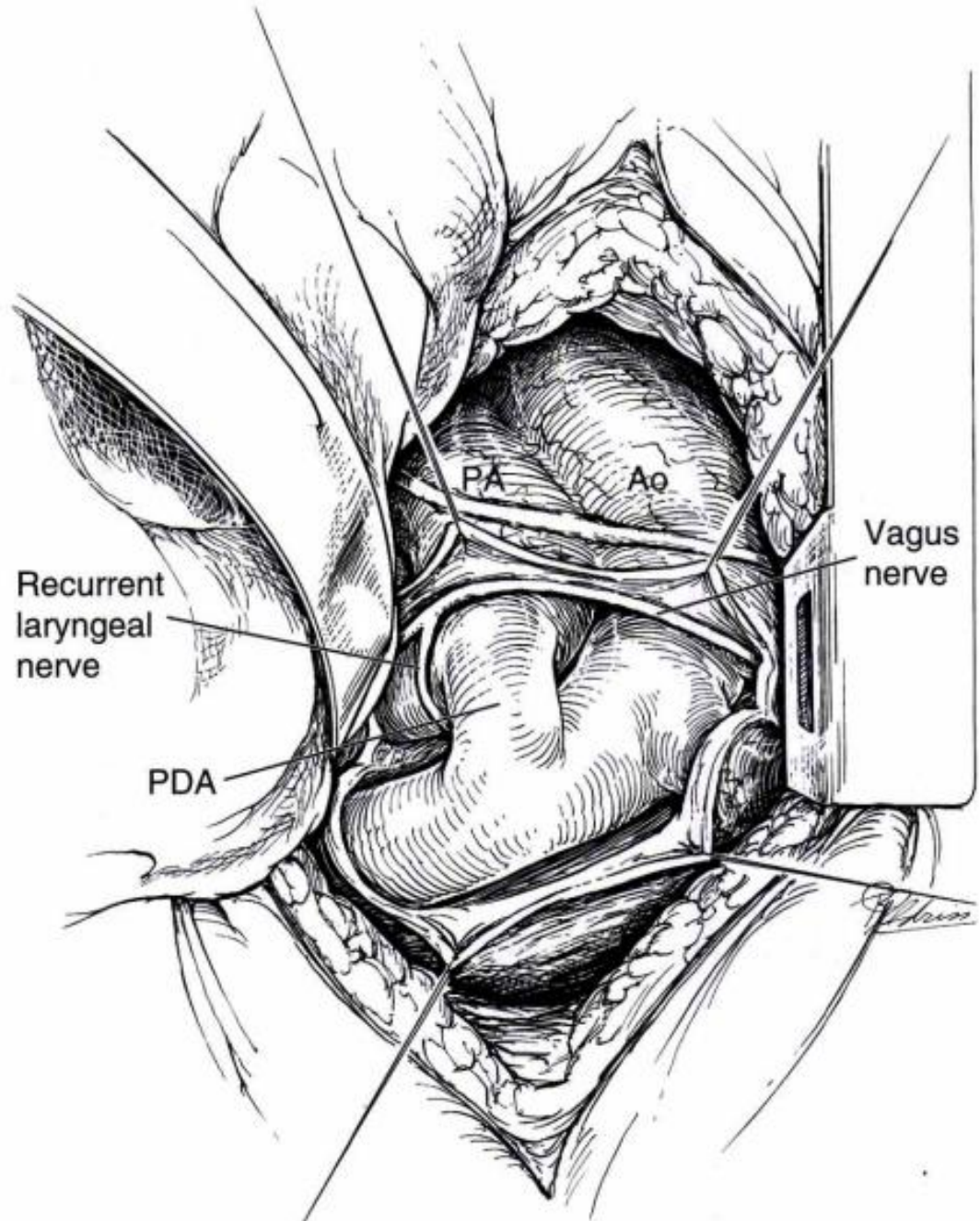
2020년 전공의 연수강좌

Normal Cardiac Anatomy

Keimyung University Dongsan Medical Center

Woo Sung Jang, MD., PhD.





Recurrent
laryngeal
nerve

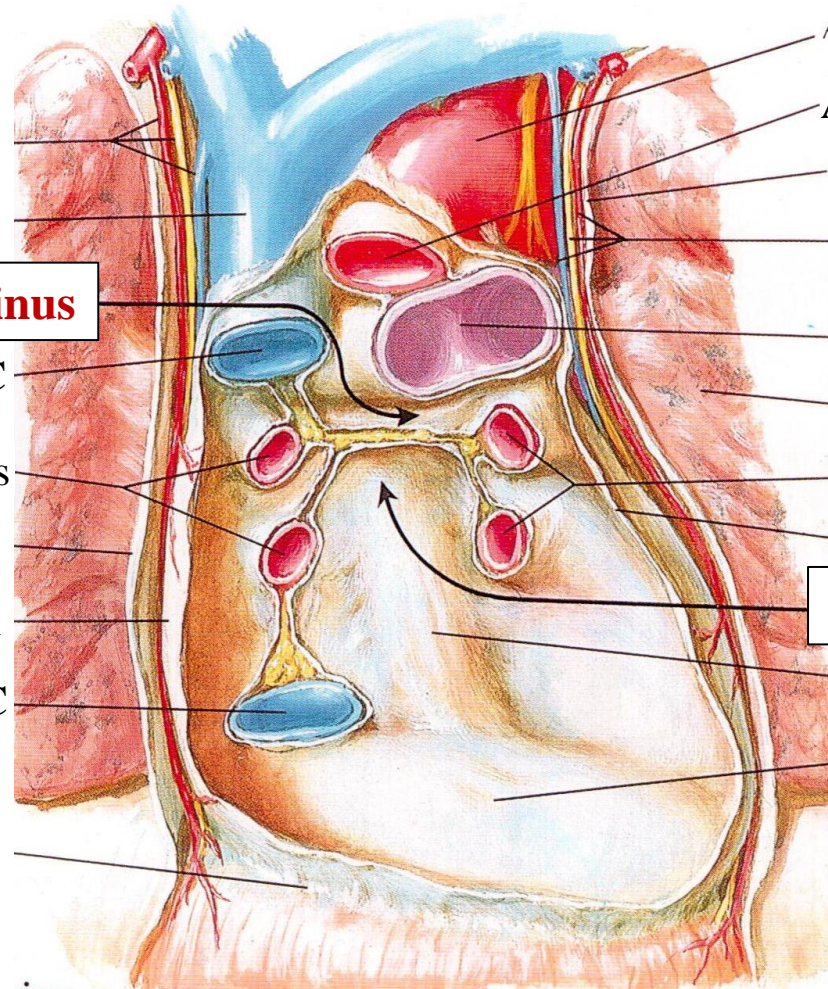
PDA

PA

Ao

Vagus
nerve

Pericardium



Transverse pericardial sinus

SVC

Right pulmonary veins

Pericardium

IVC

Aorta

Pulmonary trunk

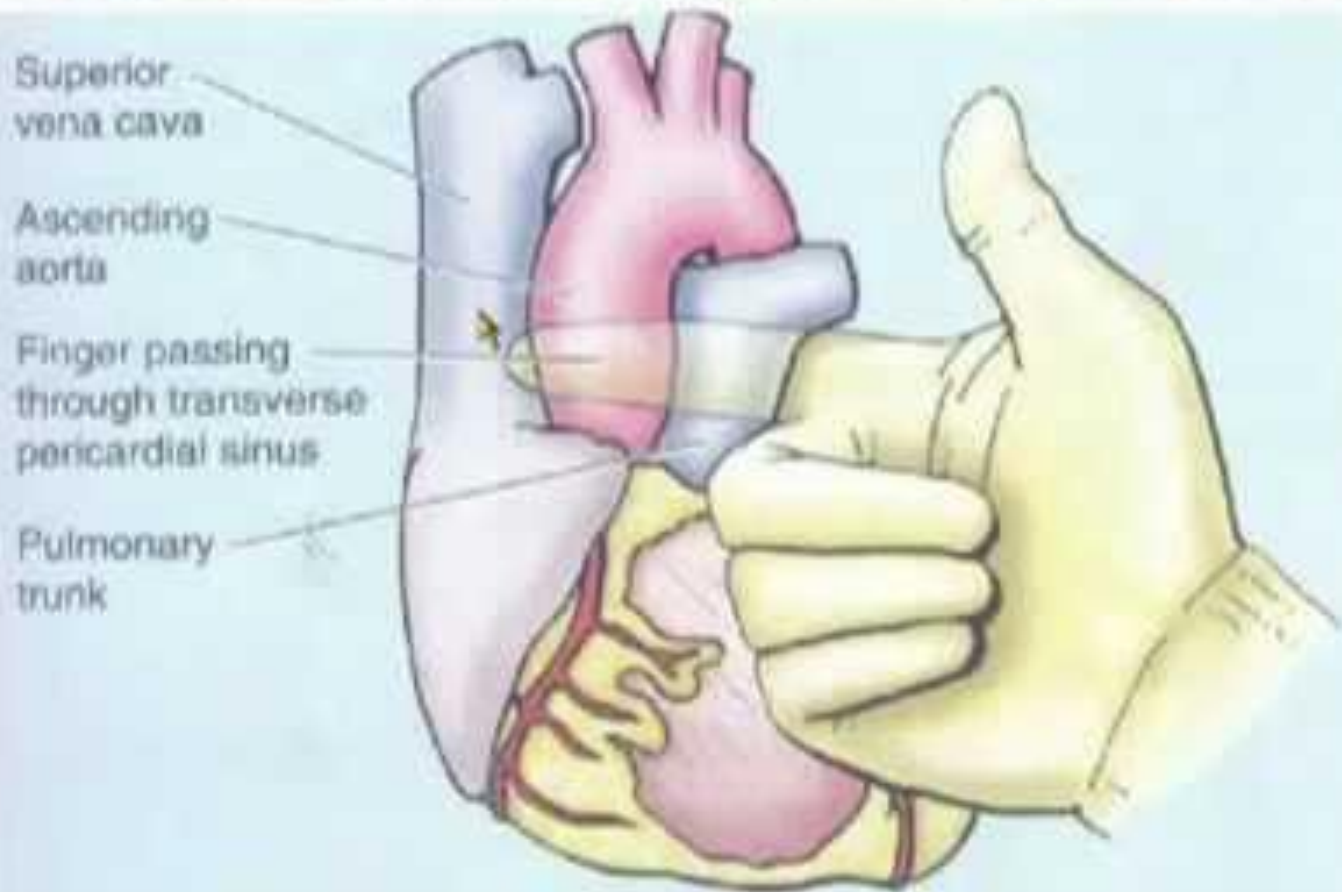
Left pulmonary veins

Pericardium

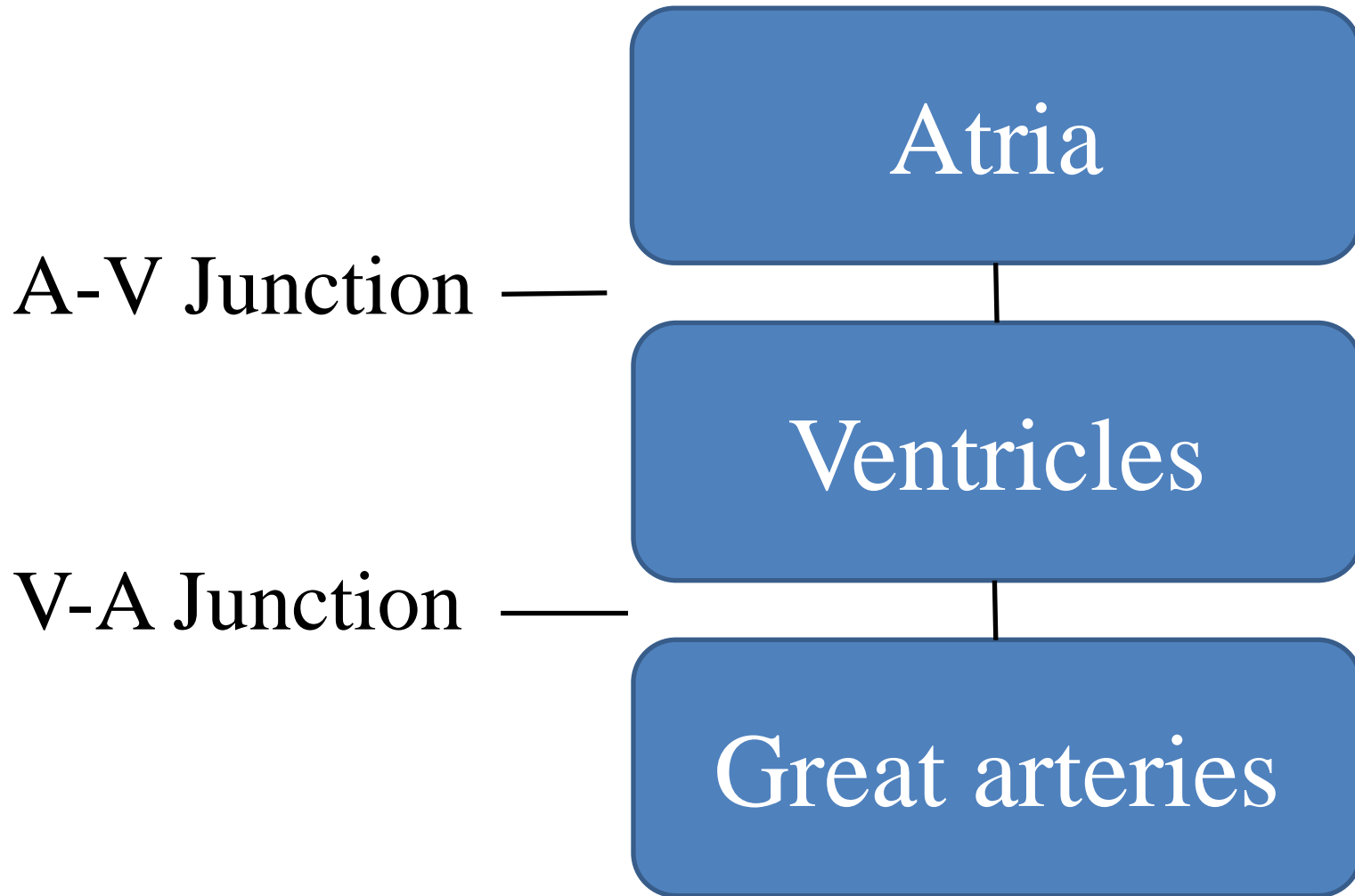
Oblique pericardial sinus

Esophageal prominence

TRANSVERSE SINUS OF PERICARDIUM

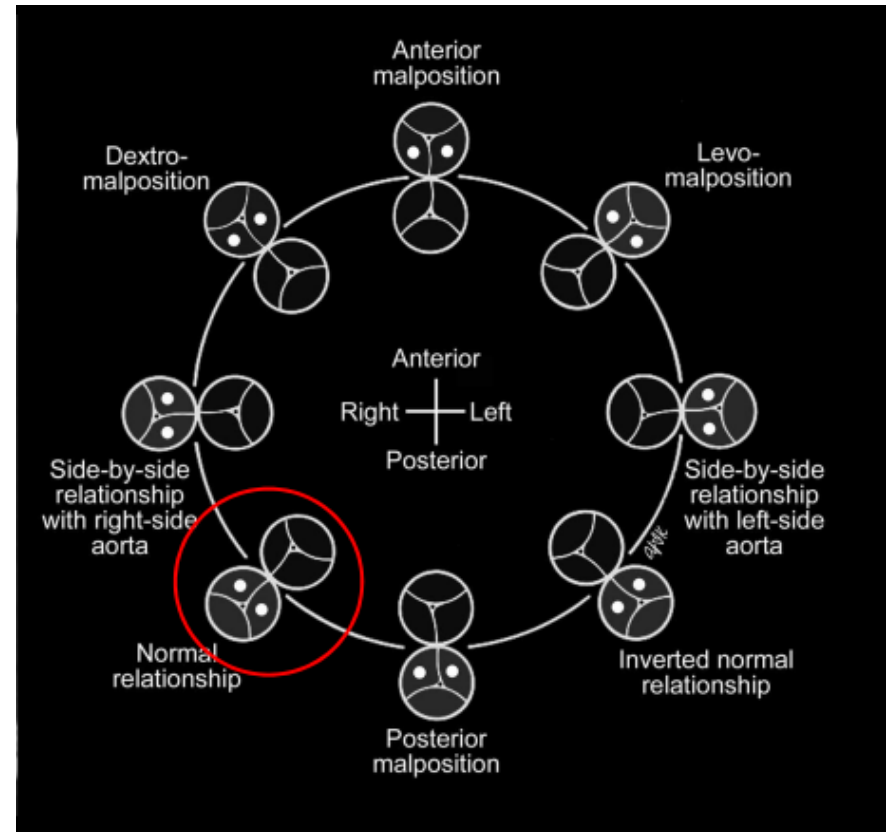


Segments of the heart

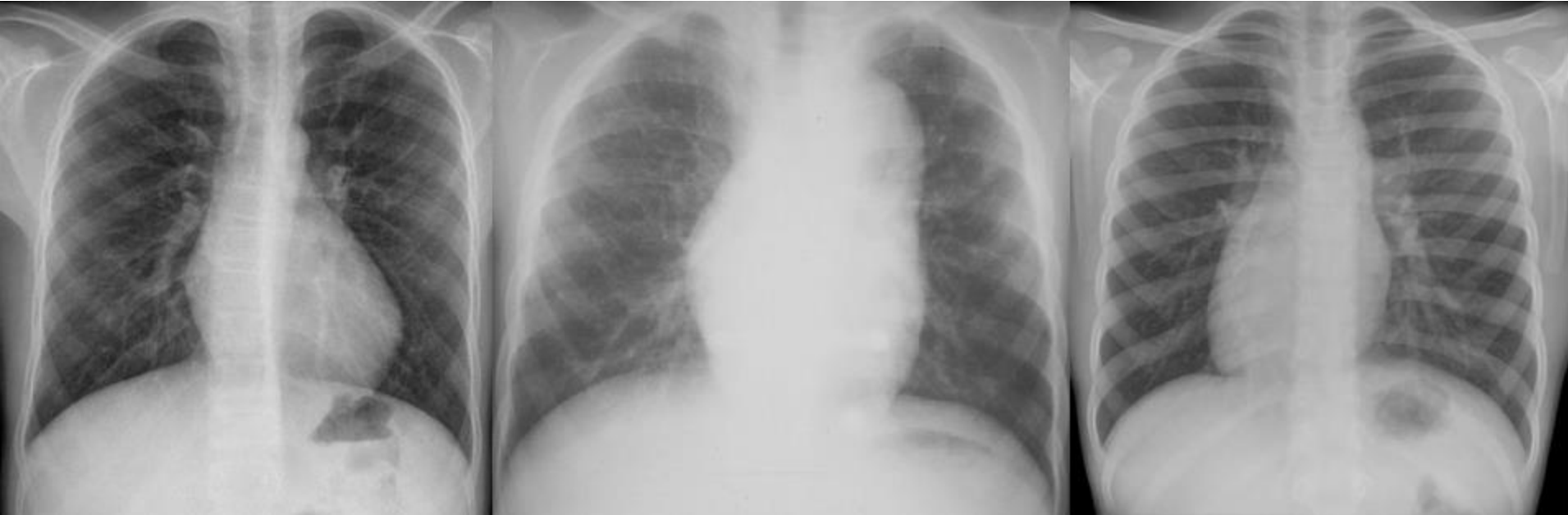

Three Facets

- Morphology
- Relationship
- Connection



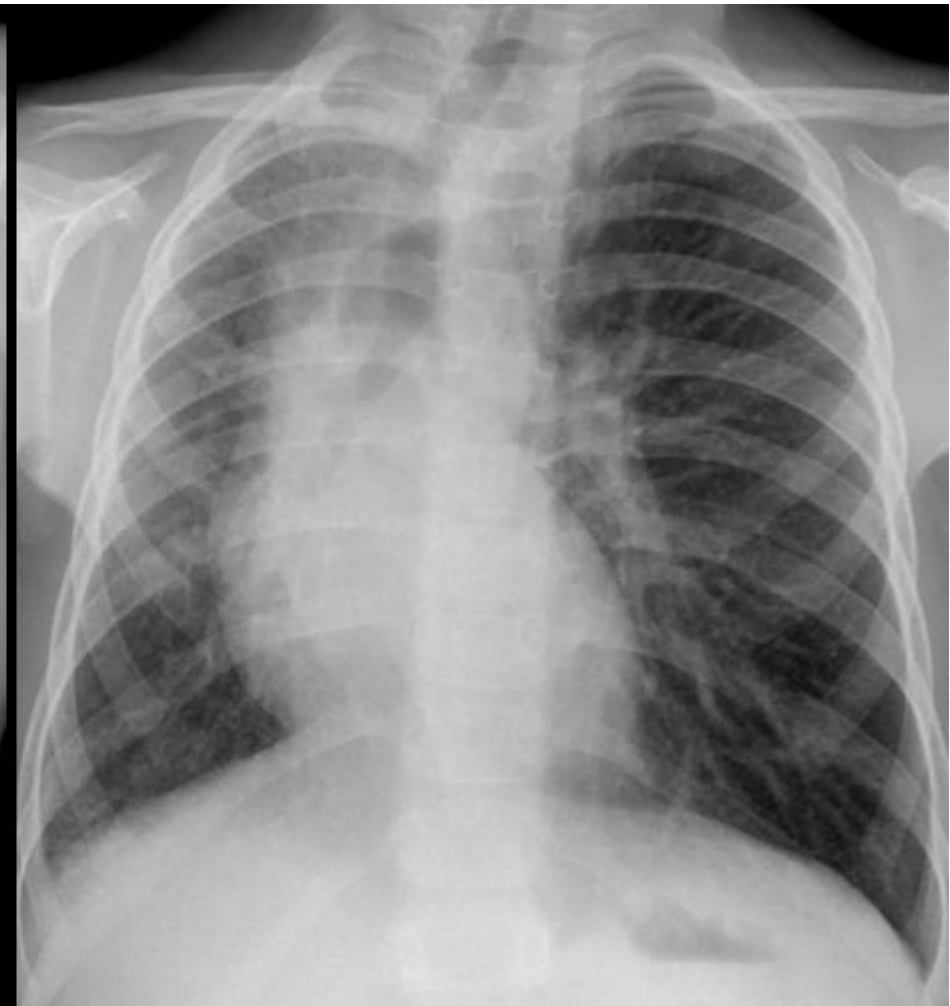
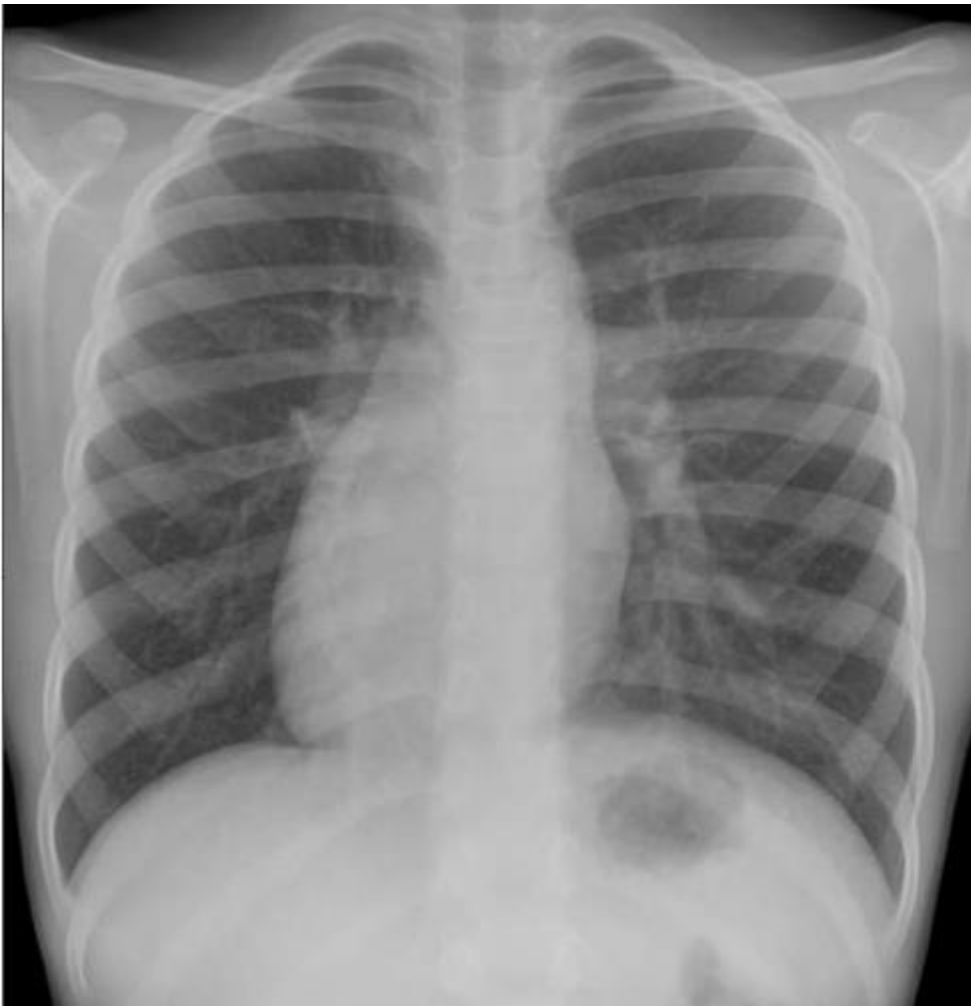Heart Position



Levocardia

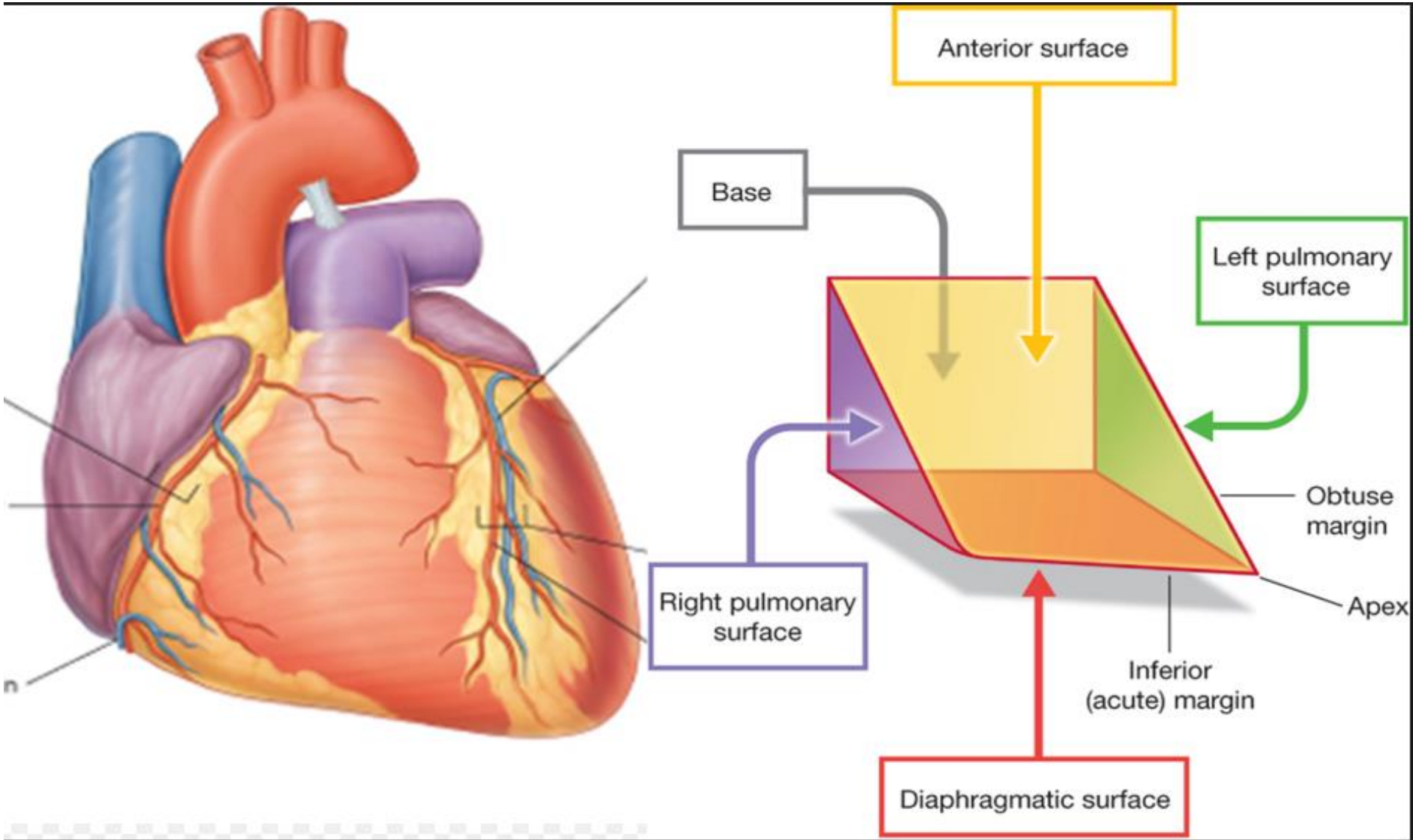
Mesocardia

Dextrocardia

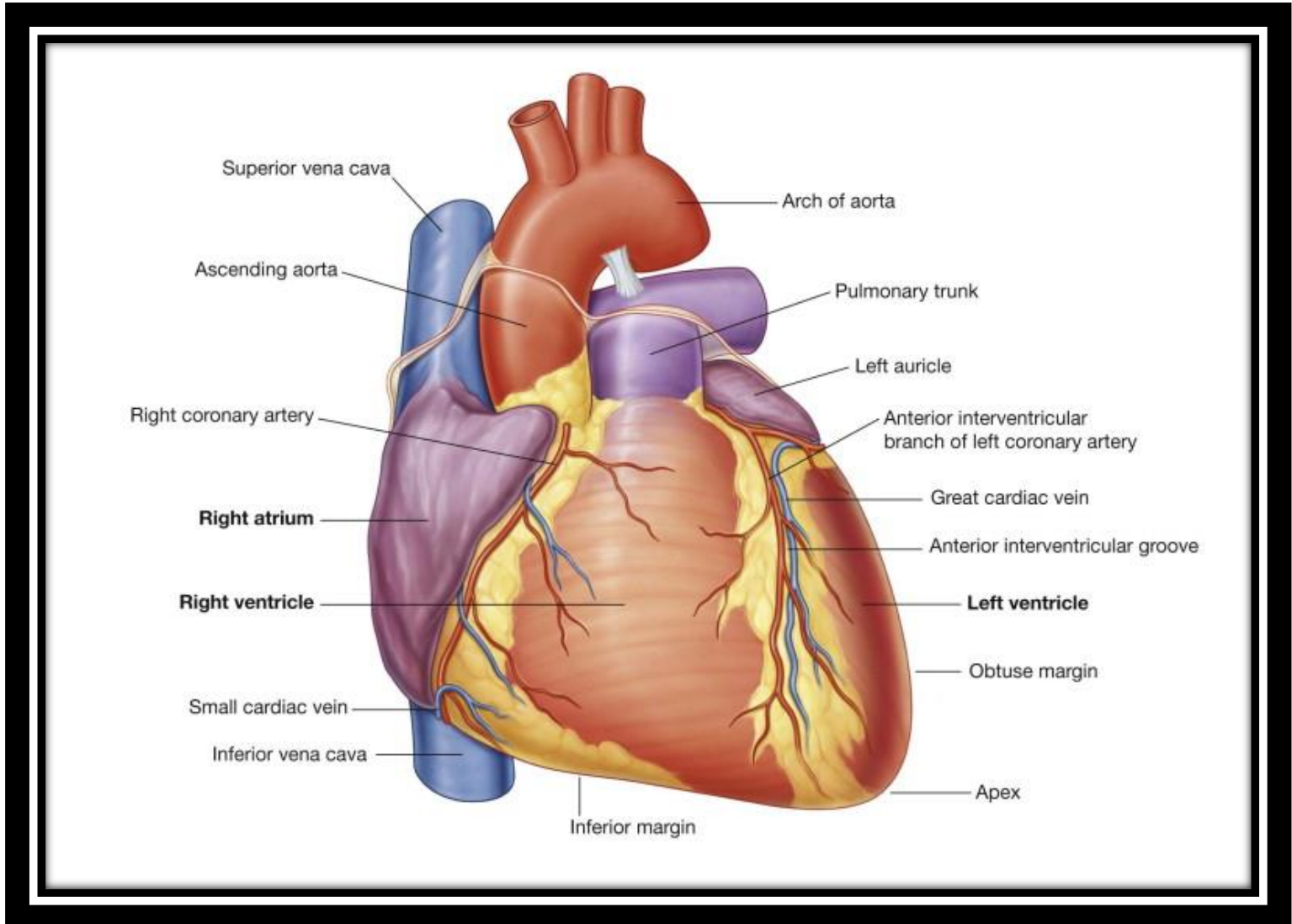


‘Dextrocardia’ VS “Displacement’

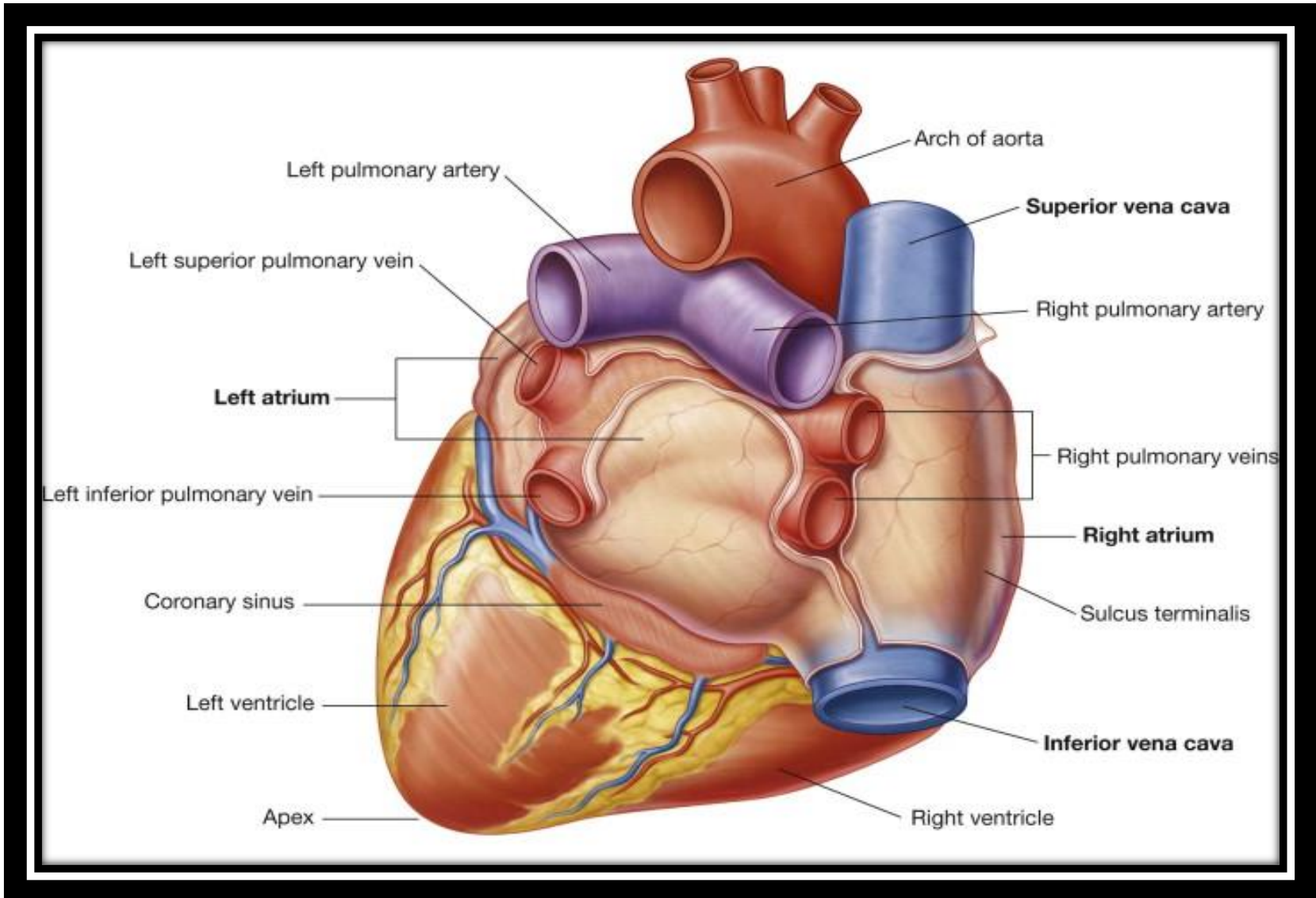
Normal cardiac anatomy



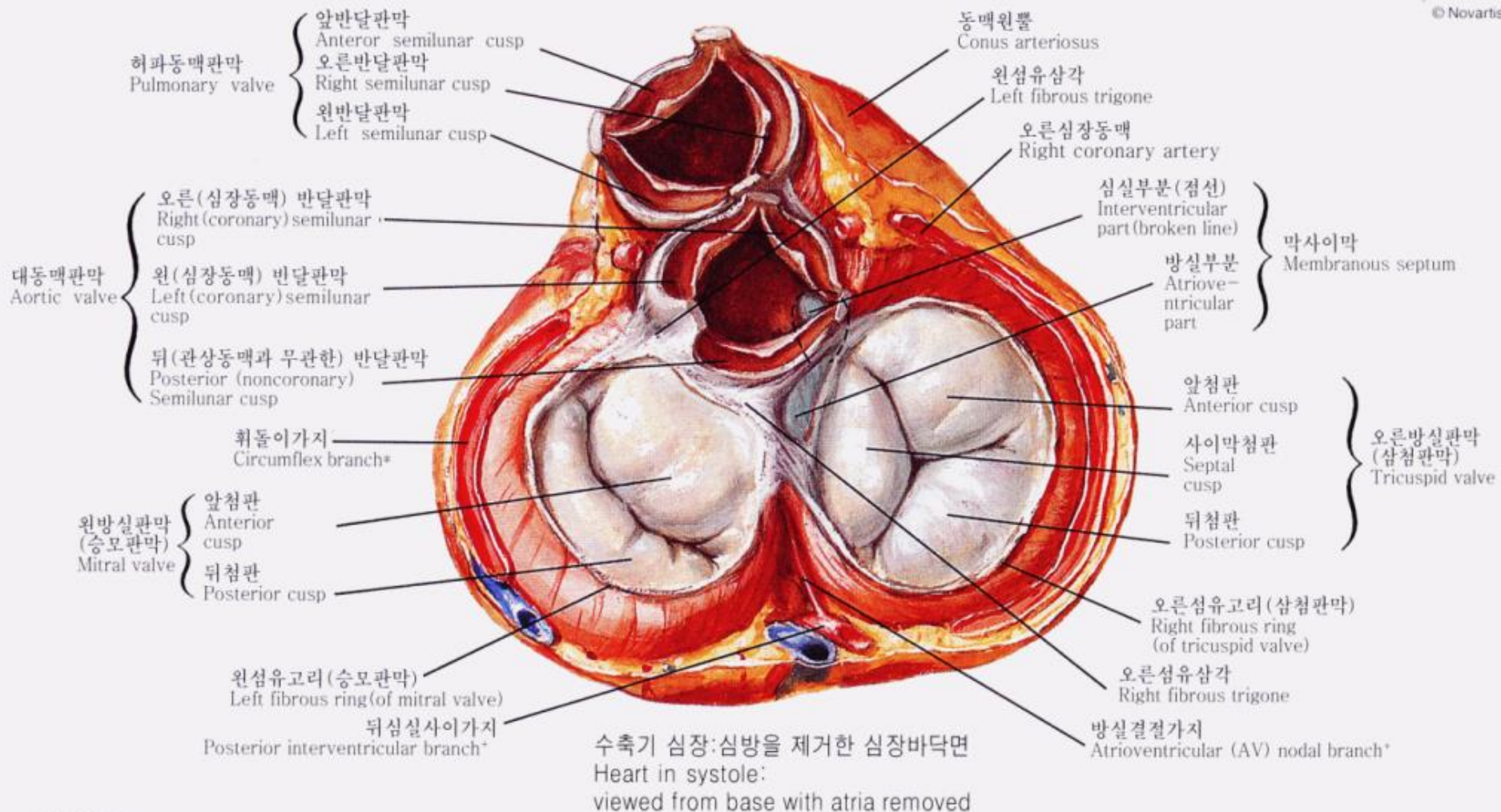
Anterior Surface



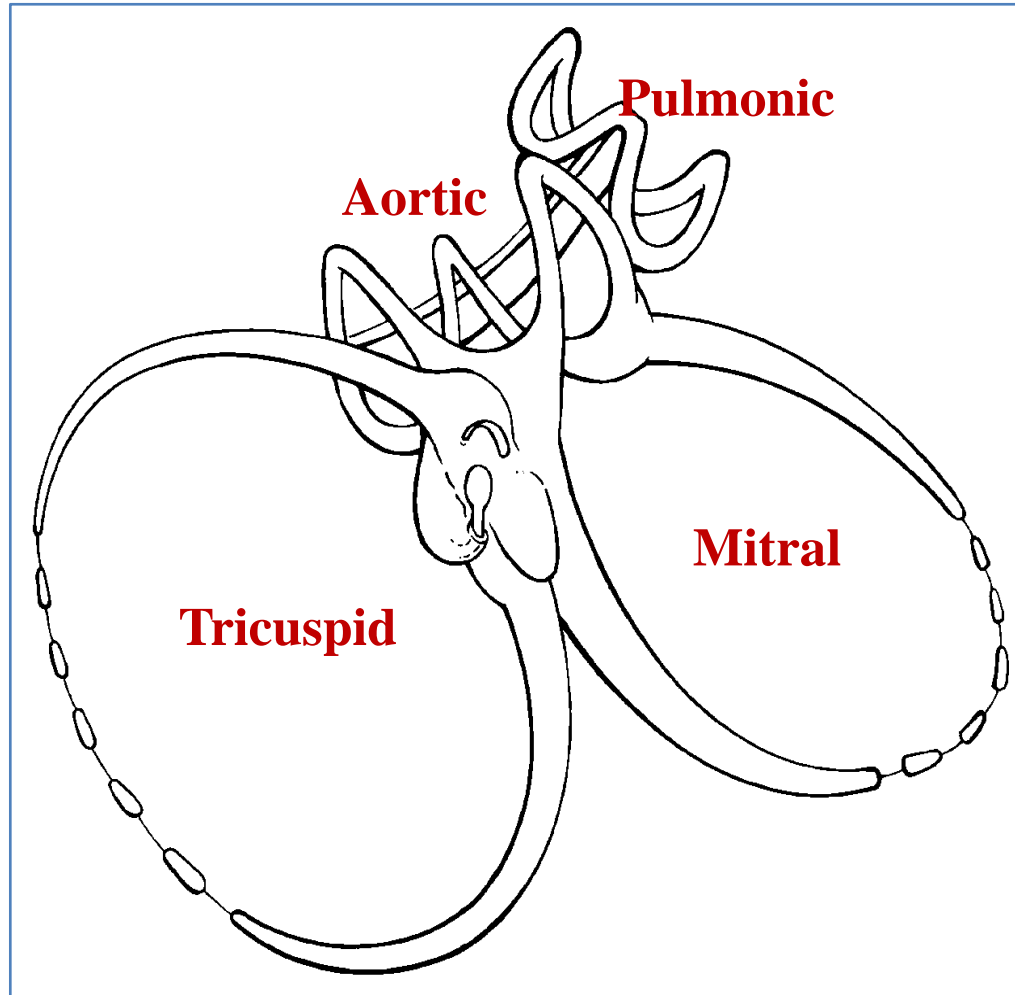
Posterior Surface



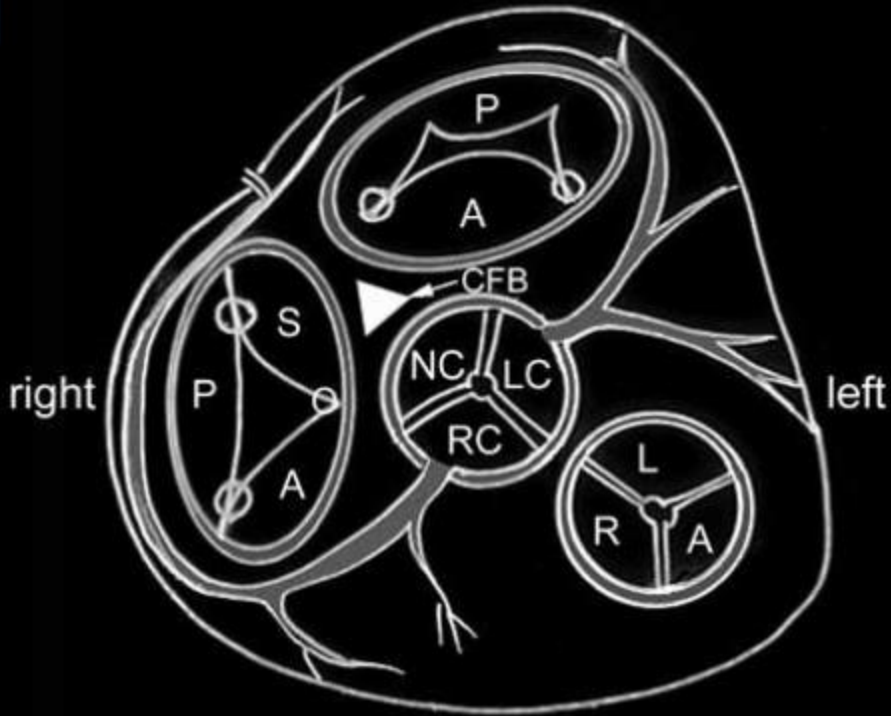
Heart Valves



Fibrous Skeleton



posterior / inferior

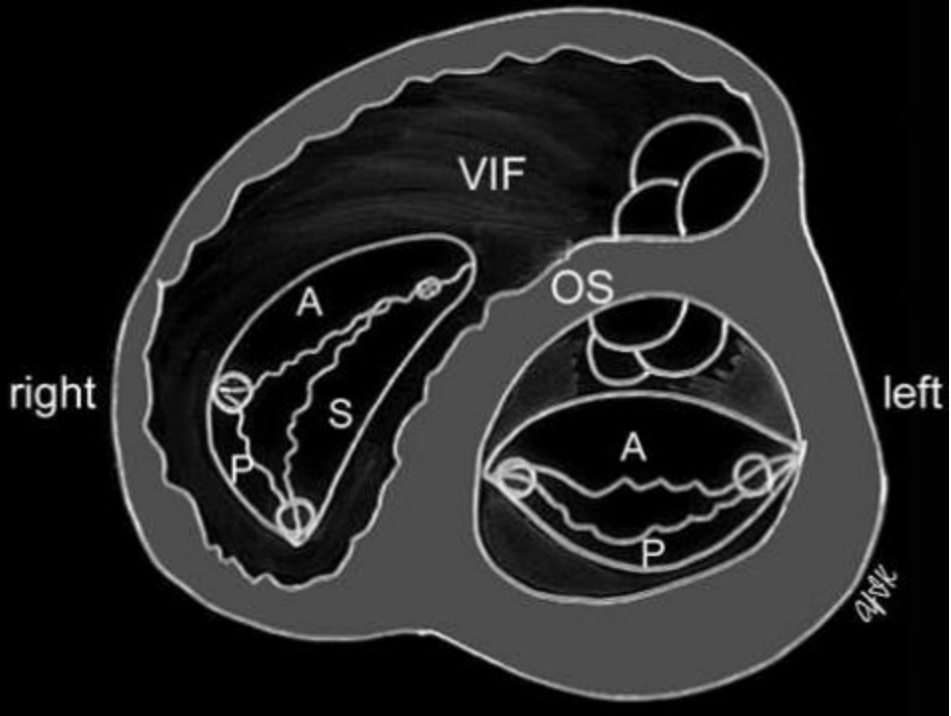


right

left

anterior / superior

anterior / superior

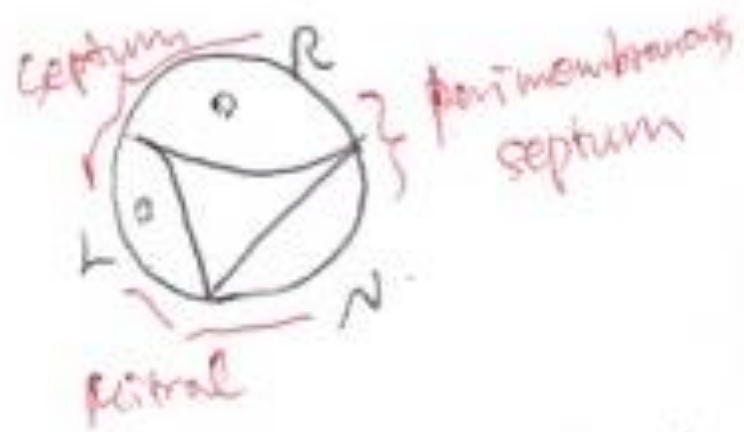


right

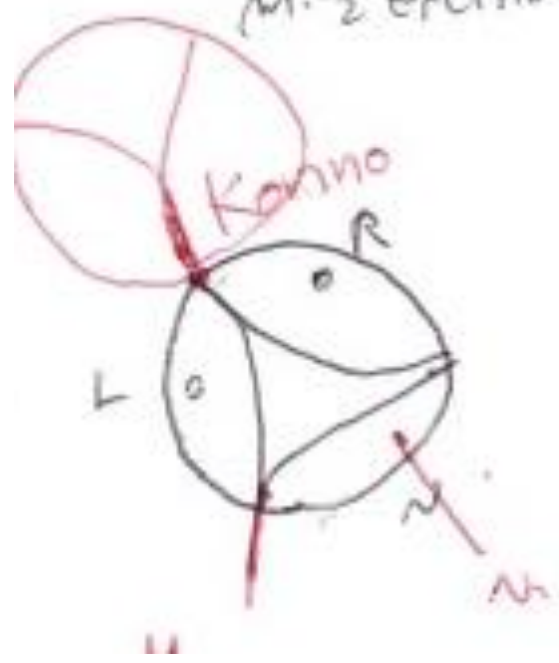left

posterior / inferior

< Surgeon's View >



∴ H.C.M.P. $\frac{1}{2}$ Septum
M. $\frac{1}{2}$ Excretion



Atrial Identification

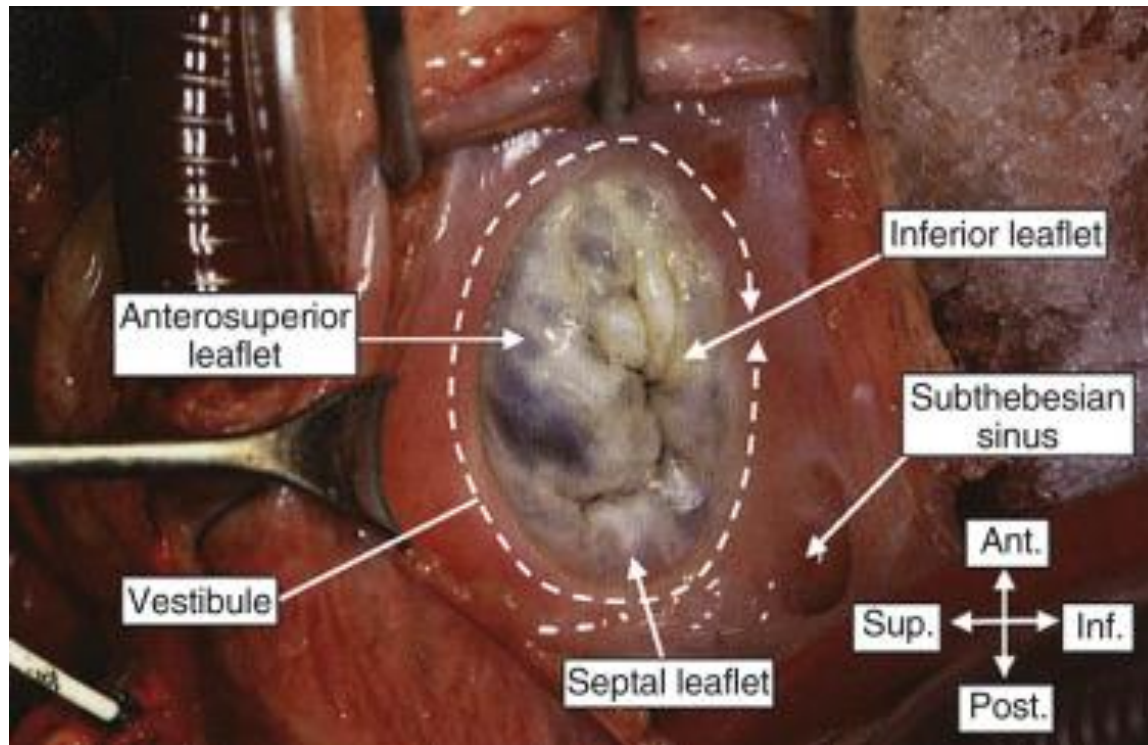
- Atrial appendages
- Pectinate muscles
- Crista terminalis
- Septal morphology
- Not by venous connections

RA Morphology

- Appendage
- Venous sinus
- Vestibule

RA Morphology

: Vestibule



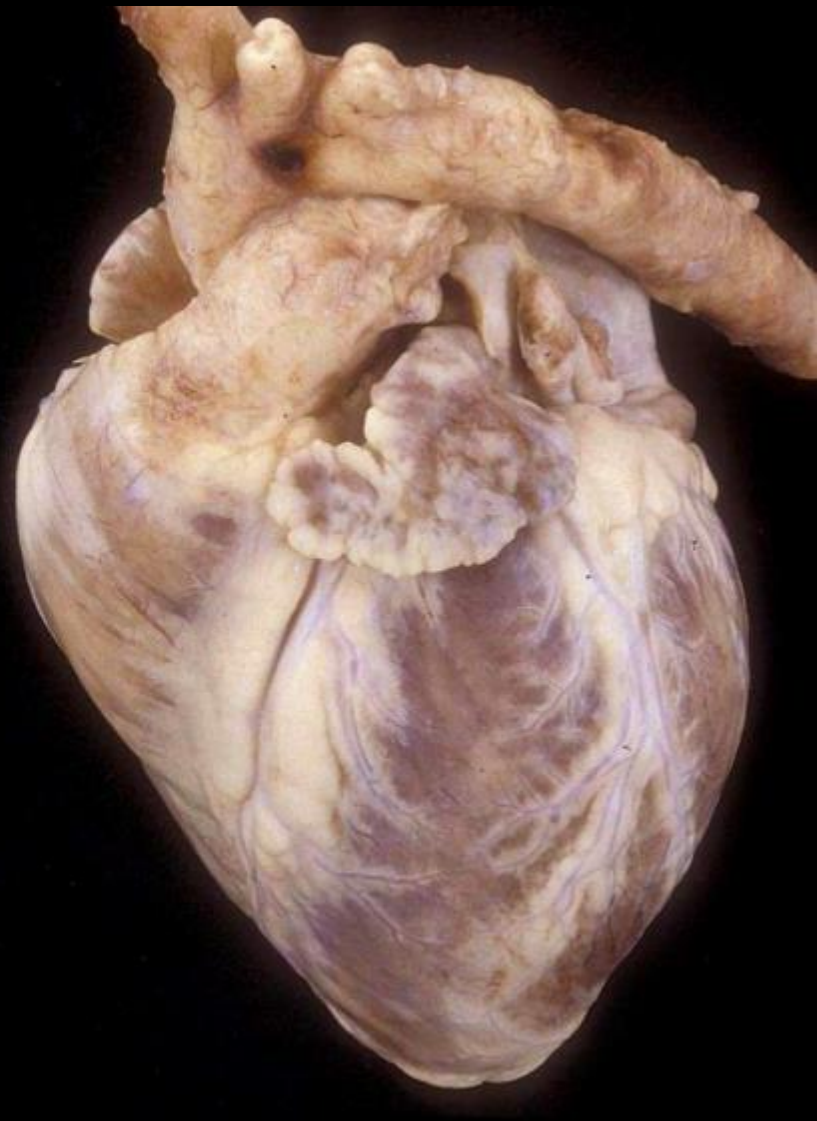
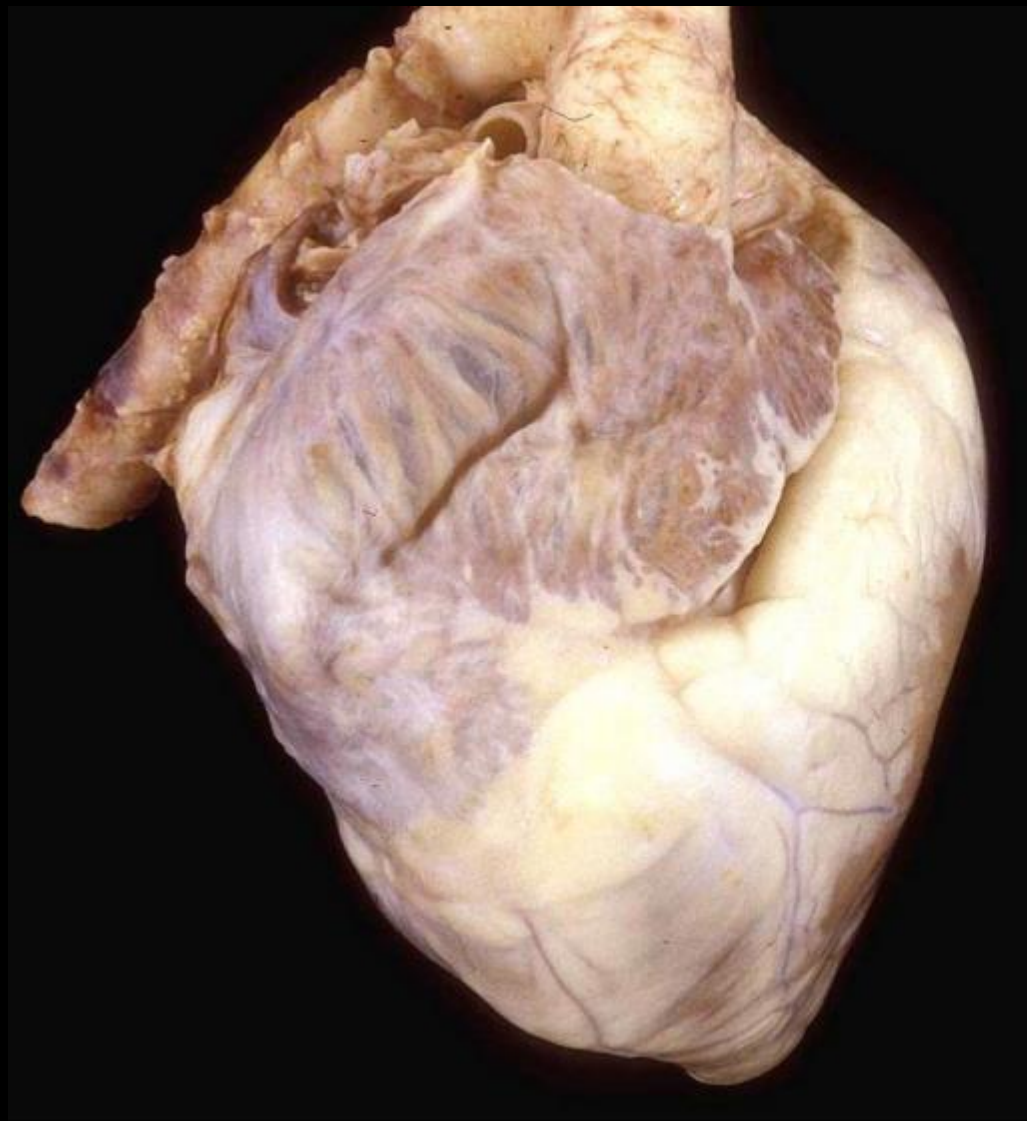
Atria

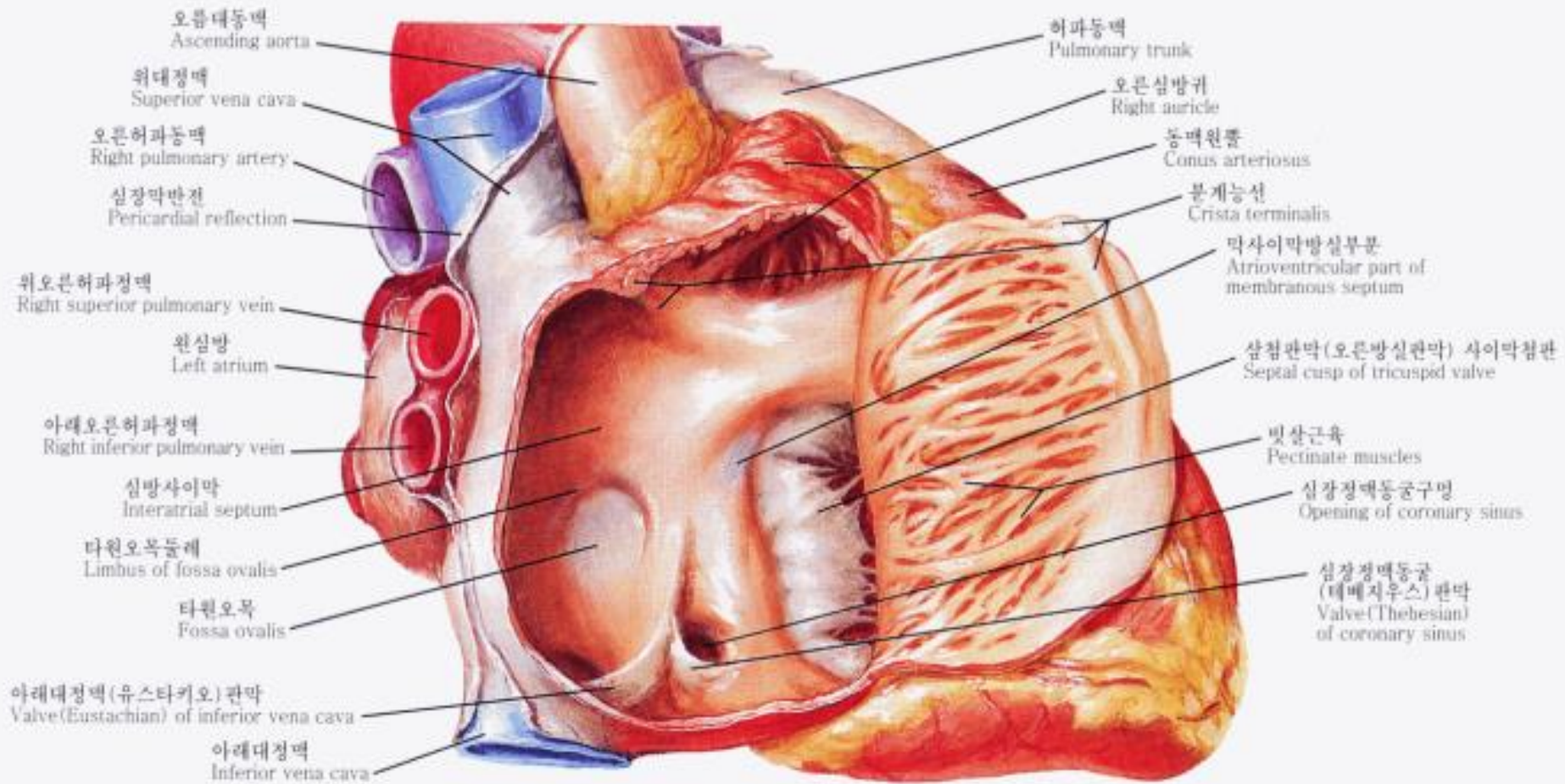
Right atrium

- Triangular appendage with a broad junction
- Pectinate muscles extending to AV junction
- Crista terminalis
- Fossa ovalis with a limb

Left atrium

- Finger-like appendage with a narrow junction
- Pectinate muscles not extending to AV junction
- No crista terminalis
- No fossa ovalis








RA Morphology : sinus node

RESEARCH ARTICLE

Anatomical Variations in the Sinoatrial Nodal Artery: A Meta-Analysis and Clinical Considerations

Jens Vikse^{1,2}, Brandon Michael Henry^{1,2}^{*}, Joyeeta Roy^{1,2}, Piravin Kumar Ramakrishnan^{1,2}, Wan Chin Hsieh³, Jerzy A. Walocha^{1,2}, Krzysztof A. Tomaszewski^{1,2}

1 International Evidence-Based Anatomy Working Group, Krakow, Poland, 2 Department of Anatomy, Jagiellonian University Medical College, Krakow, Poland, 3 First Faculty of Medicine, Charles University, Prague, Czech Republic


 These authors contributed equally to this work.

* bmhenry55@gmail.com



CrossMark
click for updates

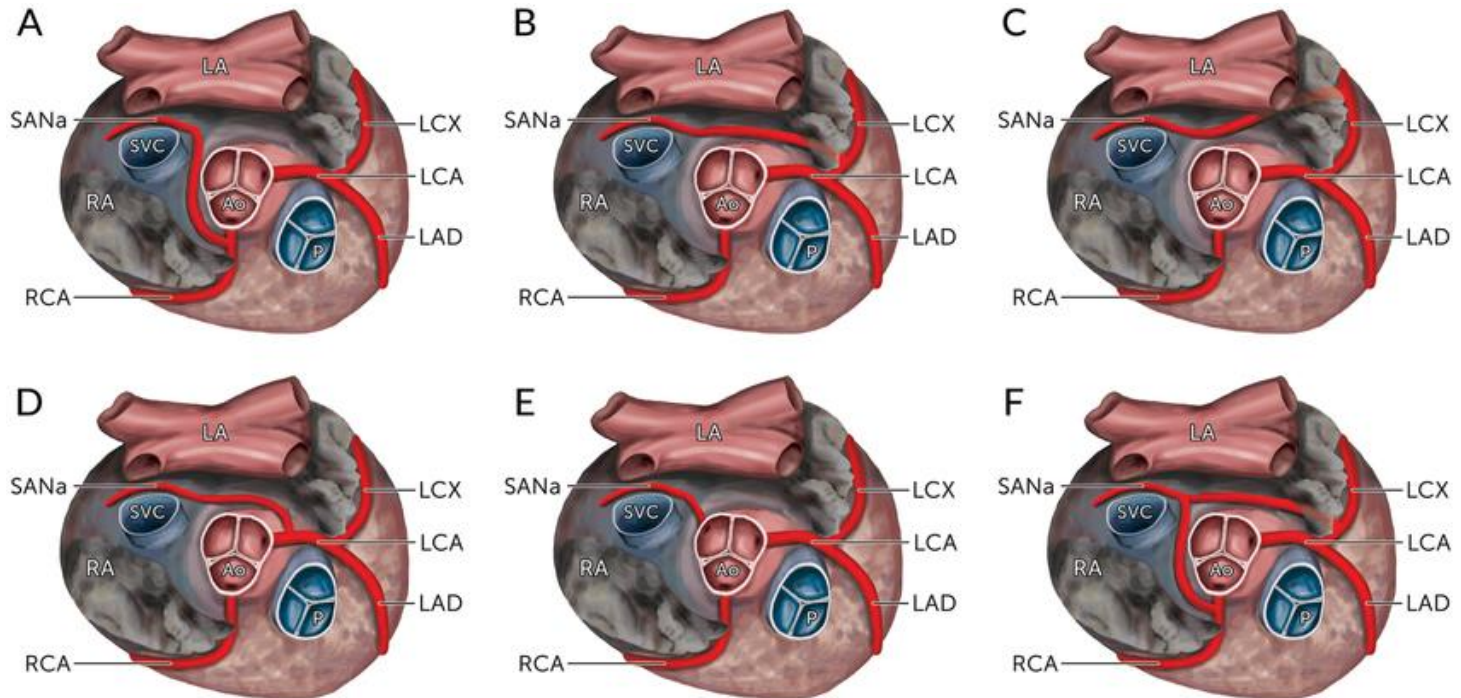
Abstract

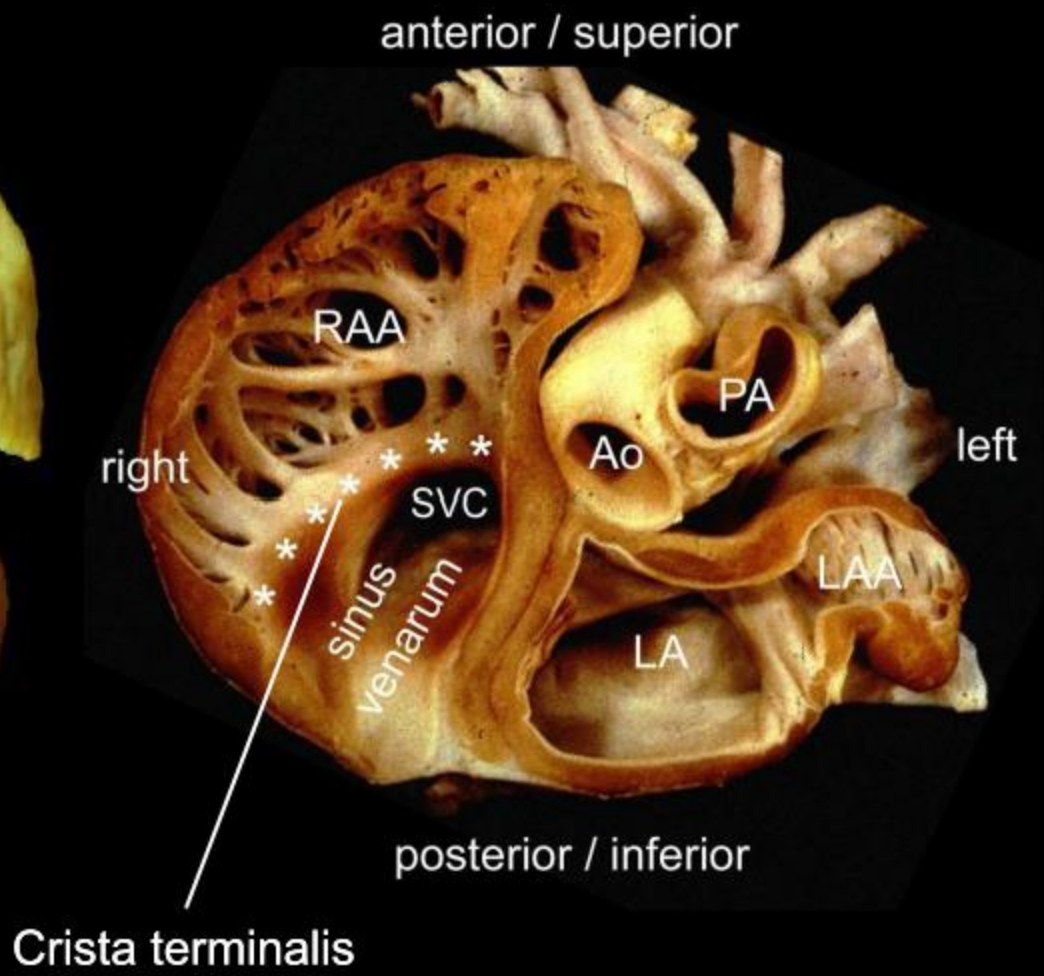
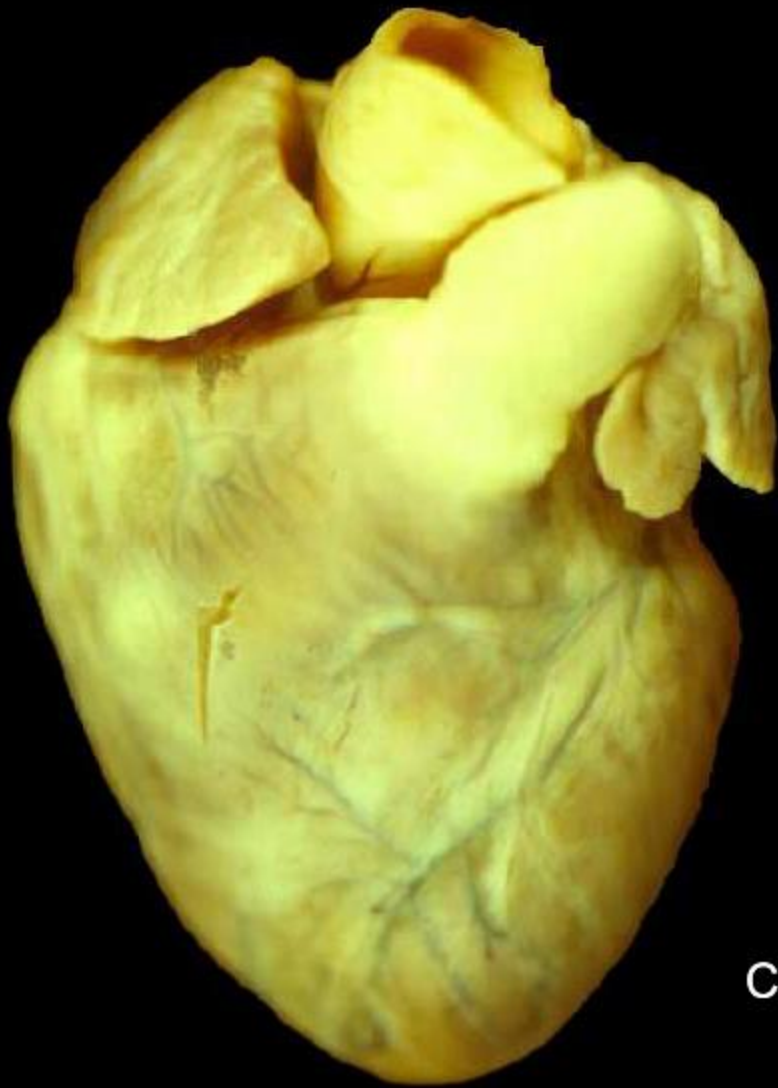 OPEN ACCESS

Background and Objective

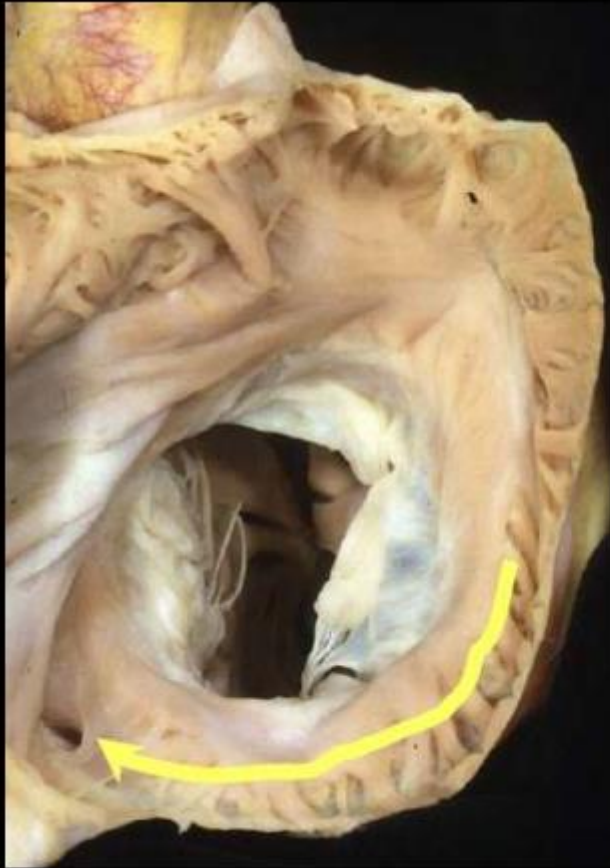
RA Morphology

: sinus node

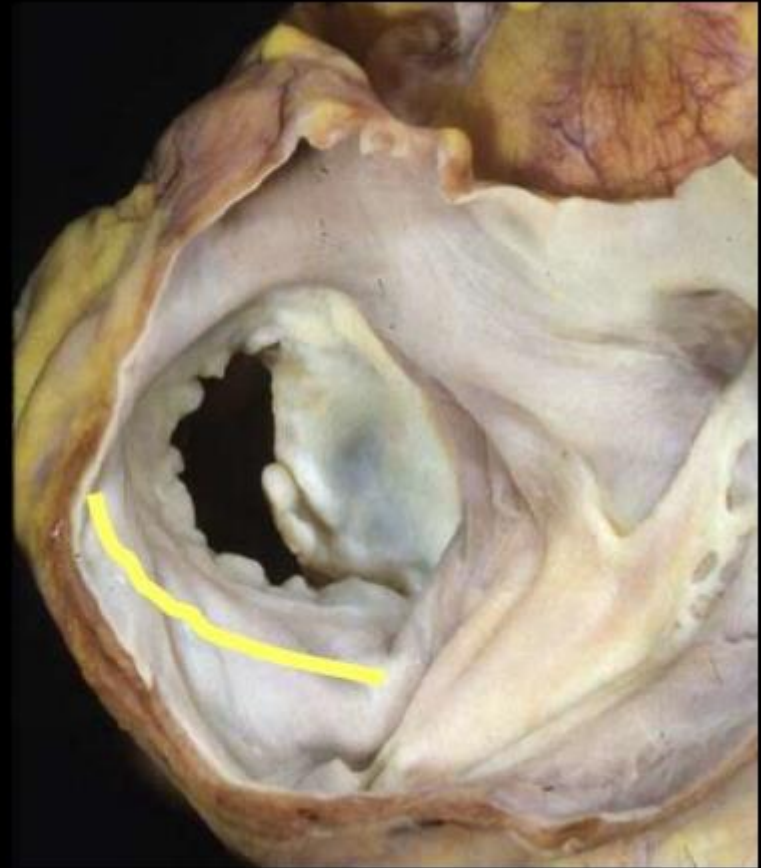




Extent of pectinate muscles

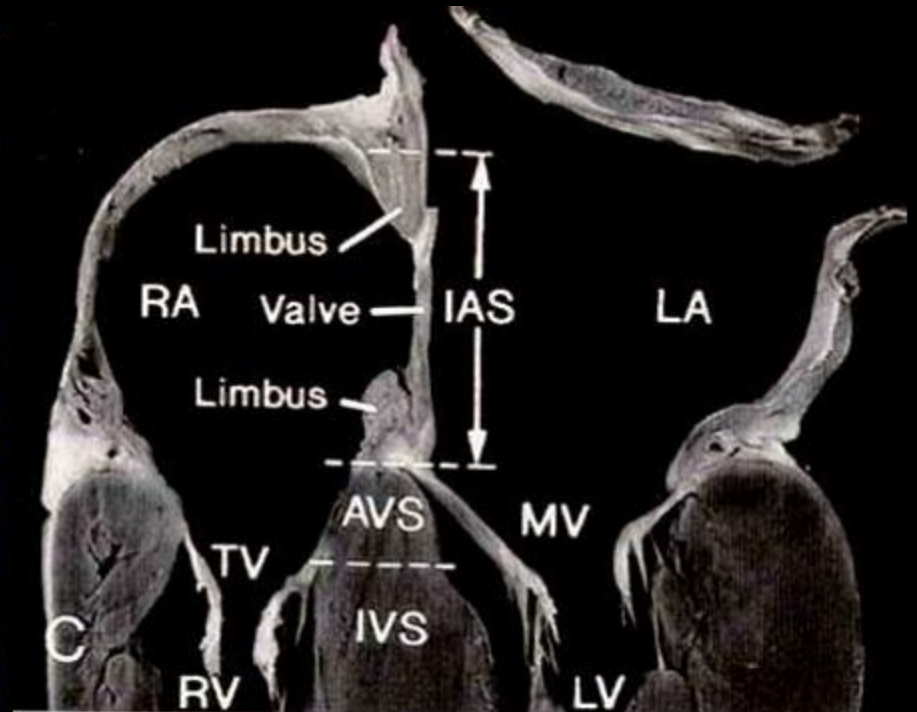
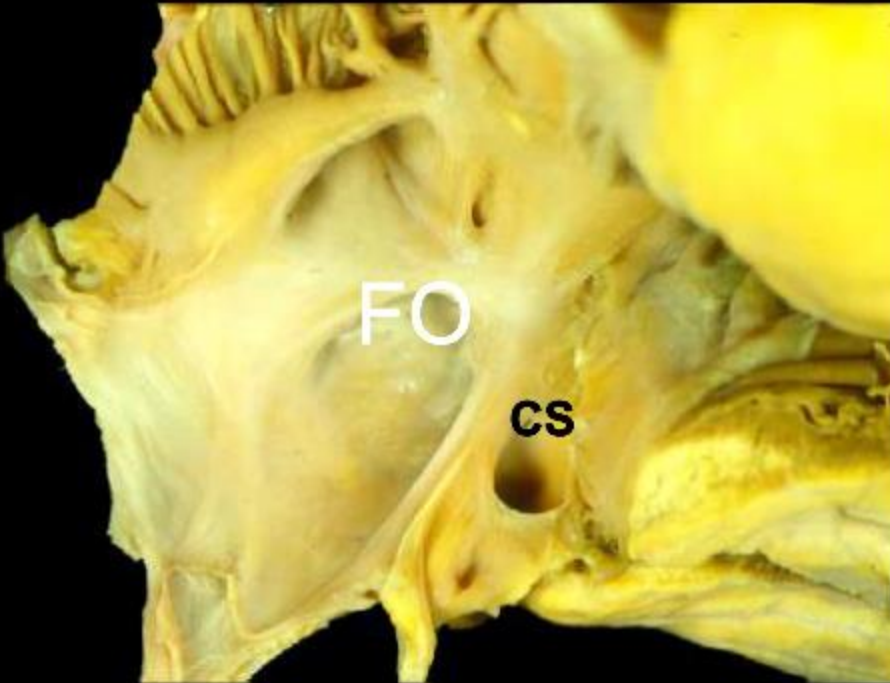


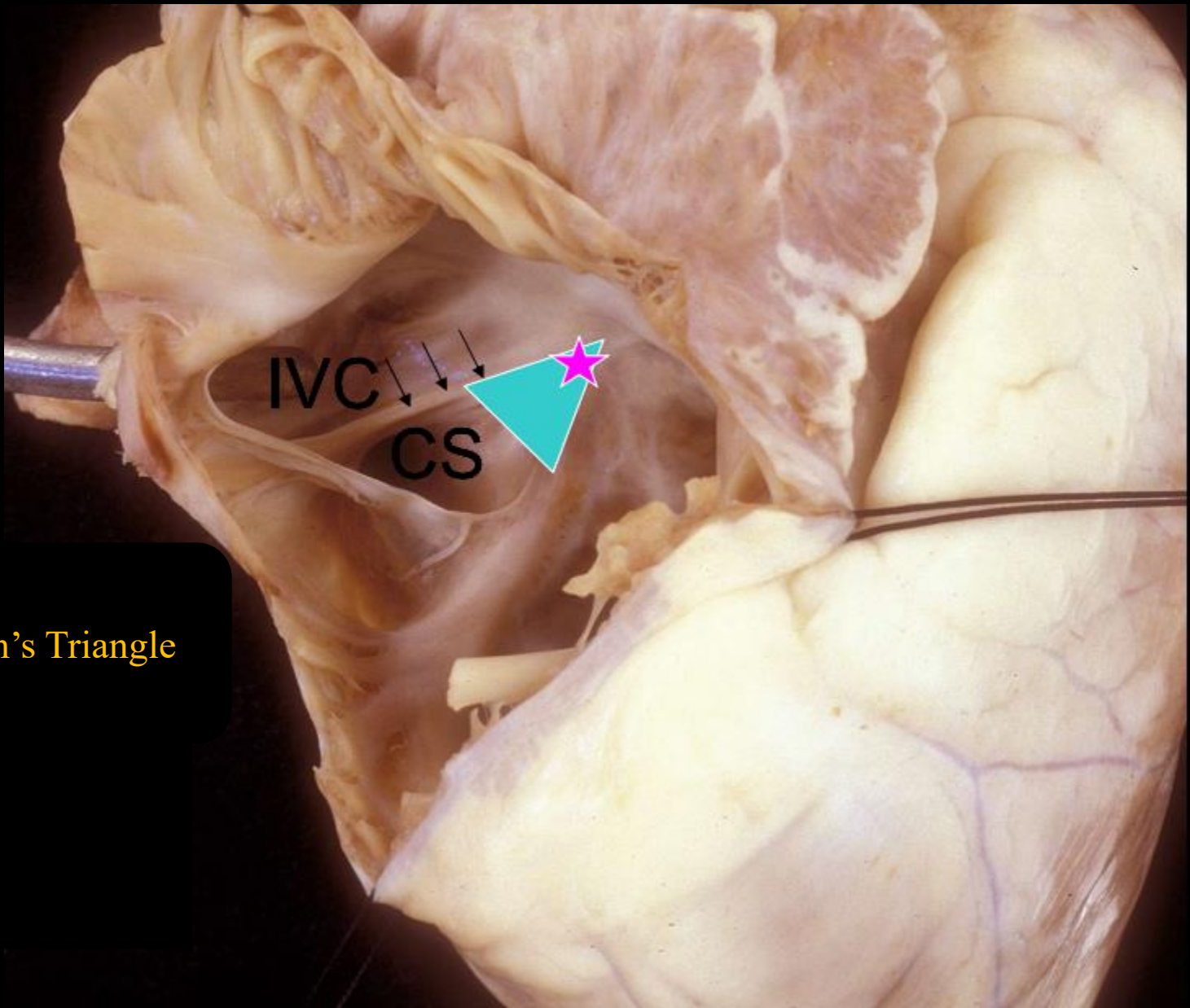
RA



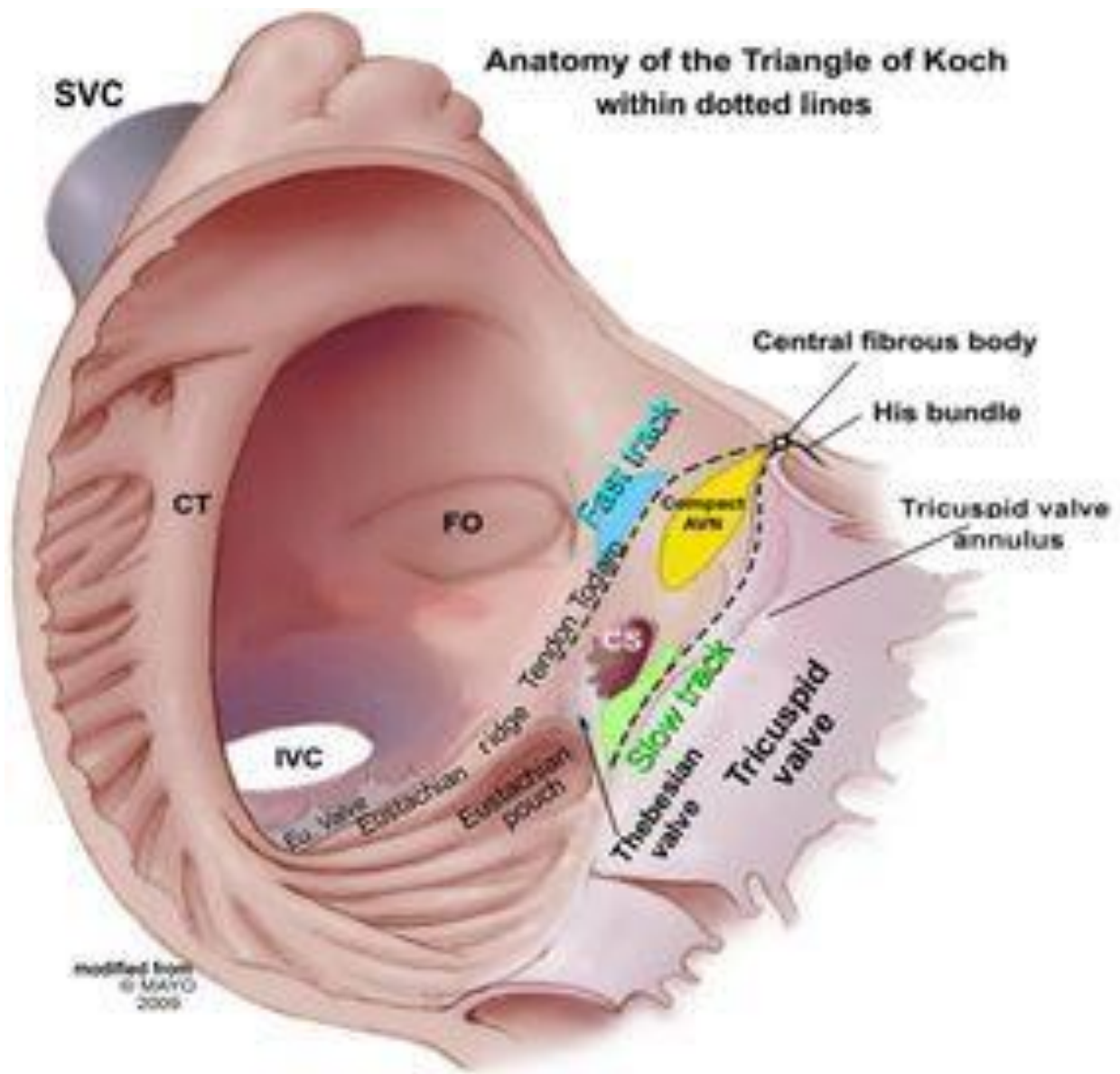
LA

Interatrial septum

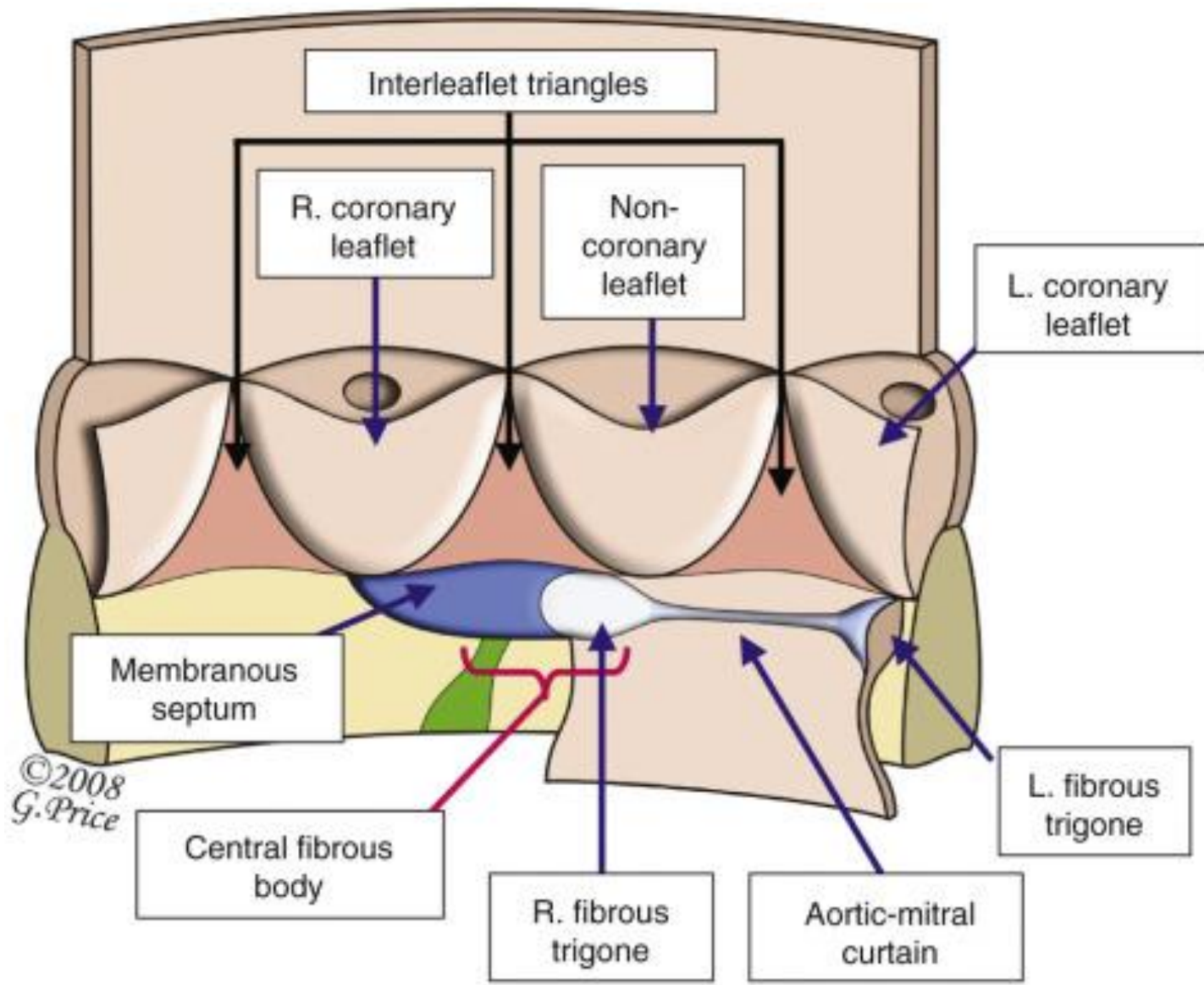





Koch's Triangle



modified from
© MAYO
2009





aortic valve (non-coronary cusp)

aortic valve (right coronary cusp)

pulmonary valve

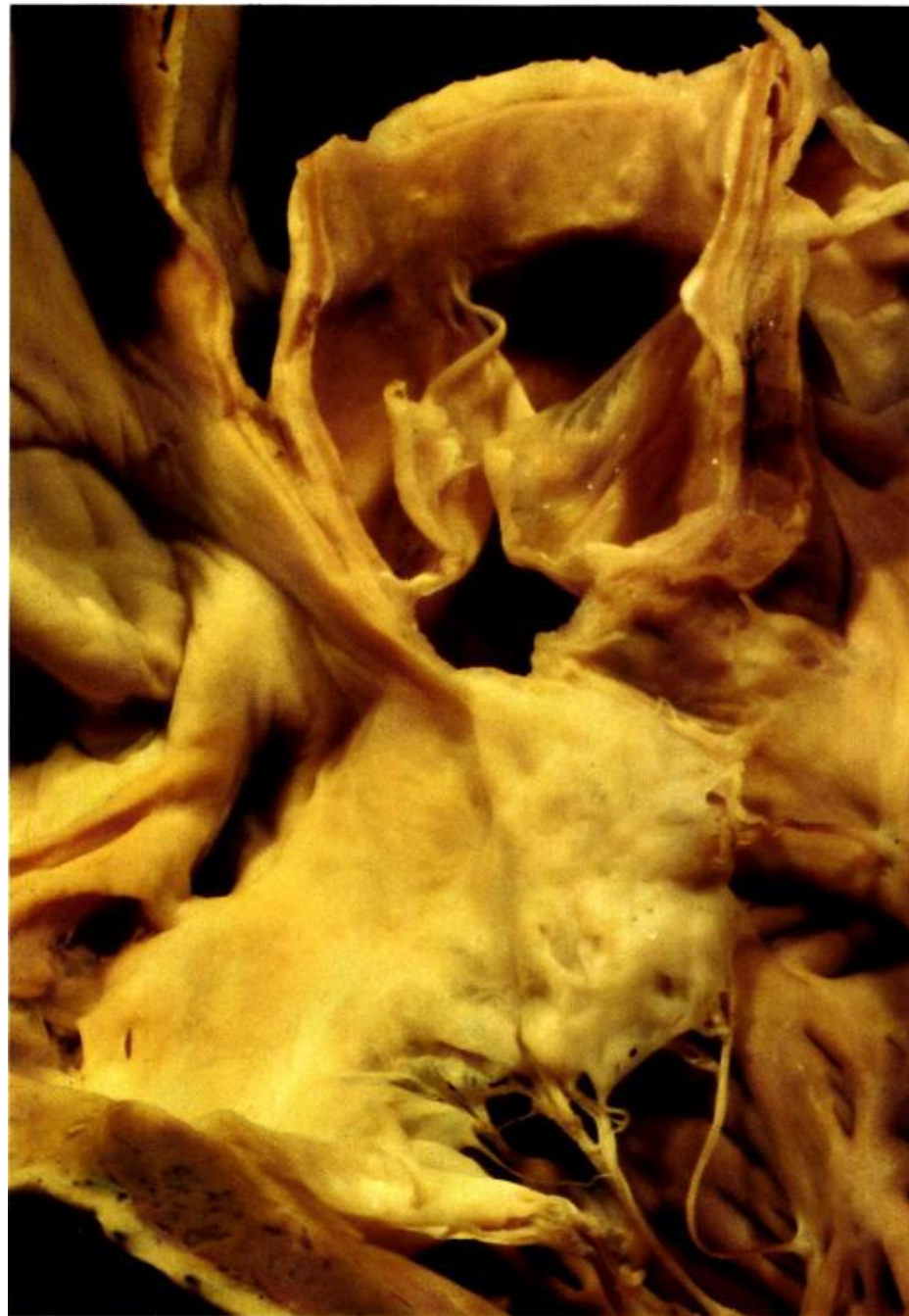infundibular septum

posterior extension (limb)
of trabecula septomarginalis

membranous septum

triangle of Koch

tricuspid septal leaflet



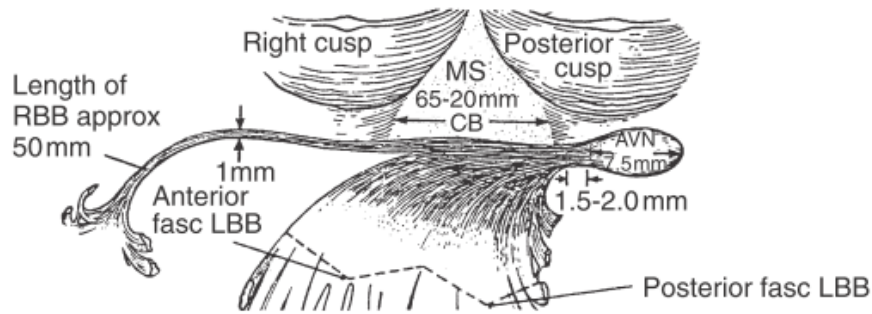


Figure 1-21 Diagram of atrioventricular (AV) conduction system and its relationship to membranous septum and aortic valve, viewed from left ventricular side. AV node is in the AV septum on right atrial side of the right trigone, which is beneath the nadir of the posterior (noncoronary) cusp of aortic valve. Common AV bundle courses along posteroinferior margin of membranous septum, giving off fibers that form the left bundle branch. This region lies beneath the commissure of right and noncoronary (posterior) aortic cusps. Right bundle branch originates from common AV bundle in the region of anteroinferior border of membranous septum. Key: *approx*, Approximately; *AVN*, atrioventricular node; *CB*, branching portion of common atrioventricular bundle; *fasc*, fascicle; *LBB*, left bundle branch; *MS*, membranous septum; *RBB*, right bundle branch. (From Titus.^{T5})

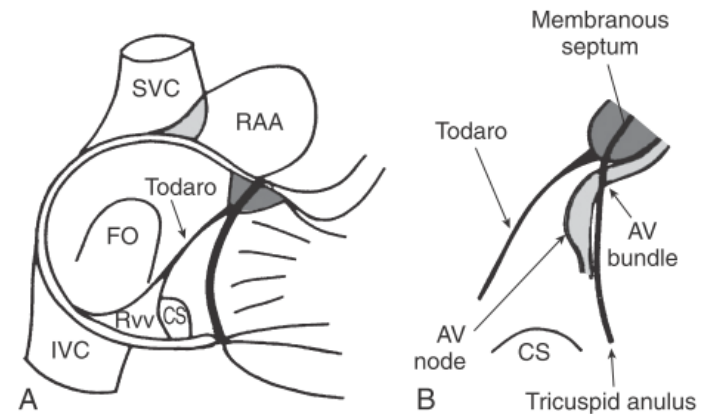
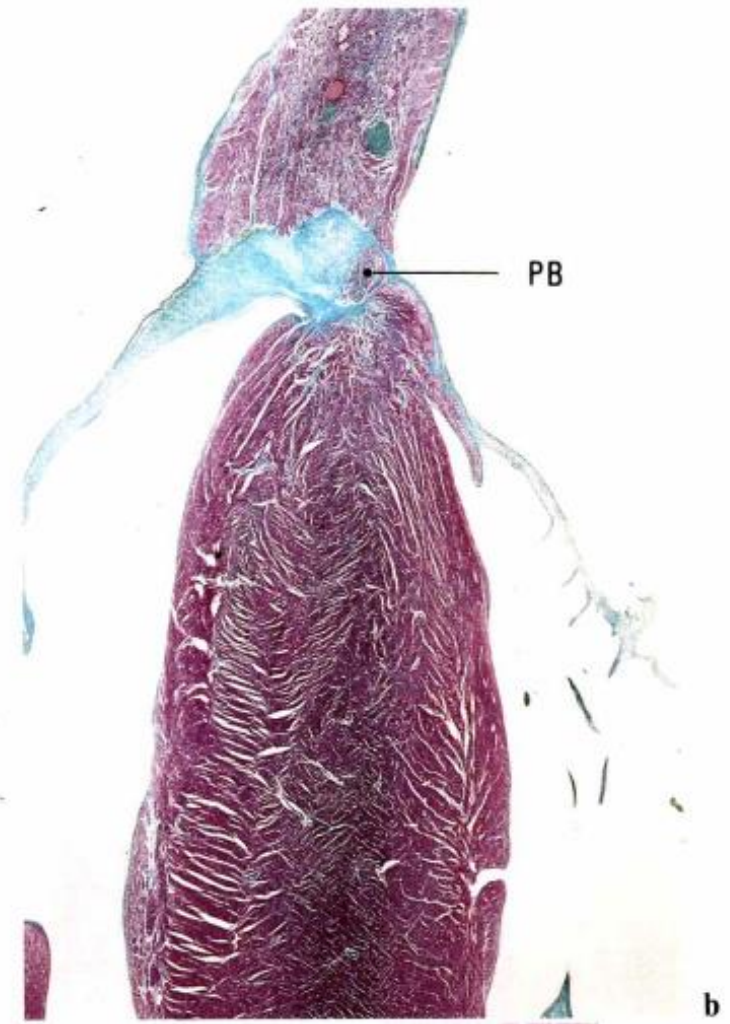
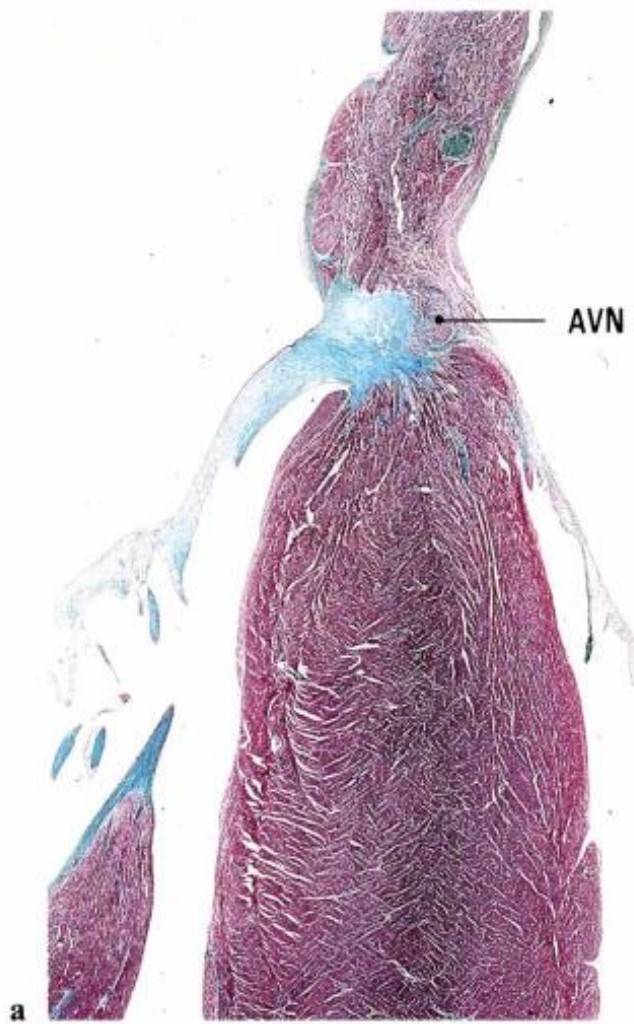
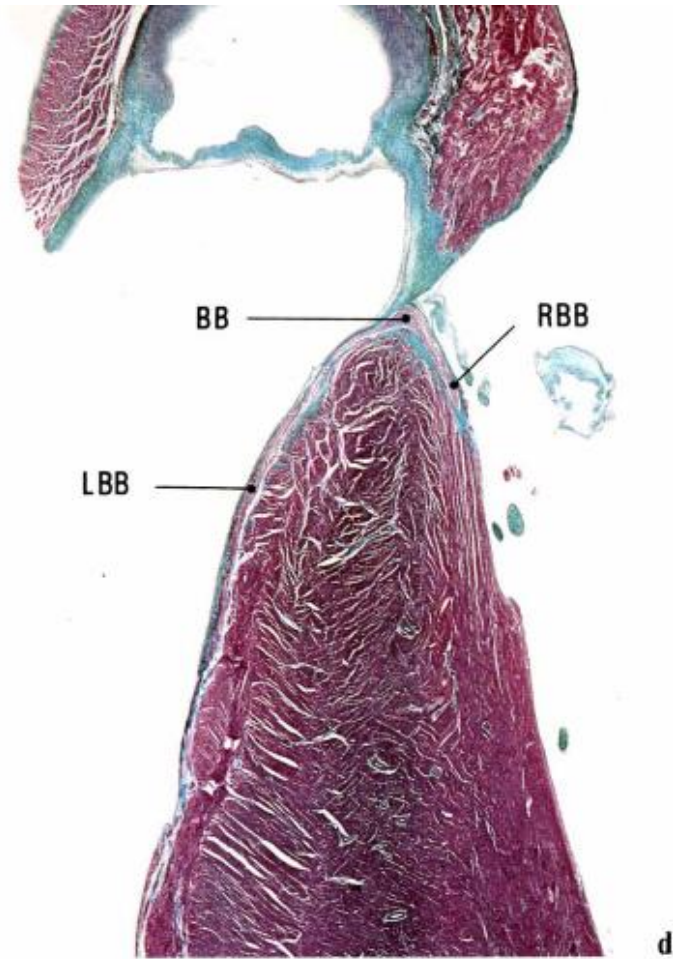
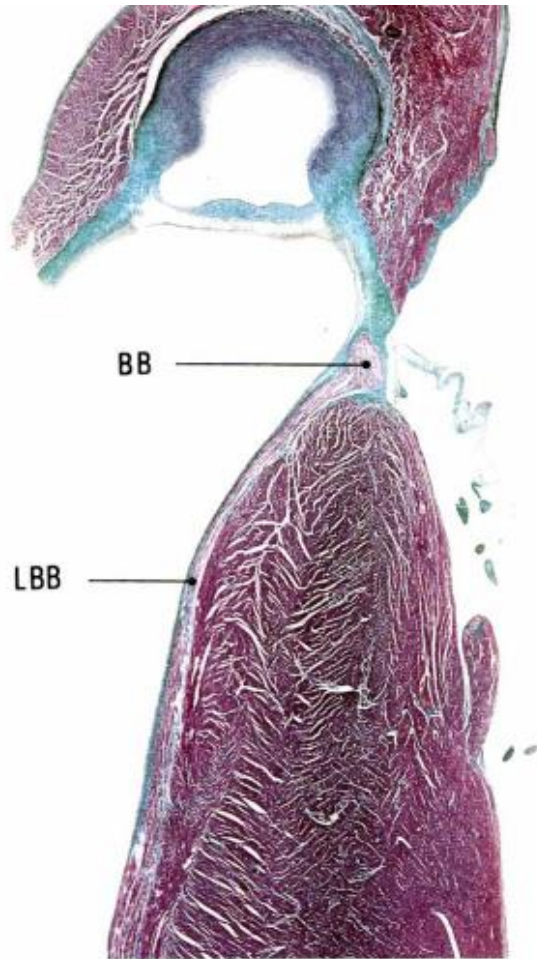
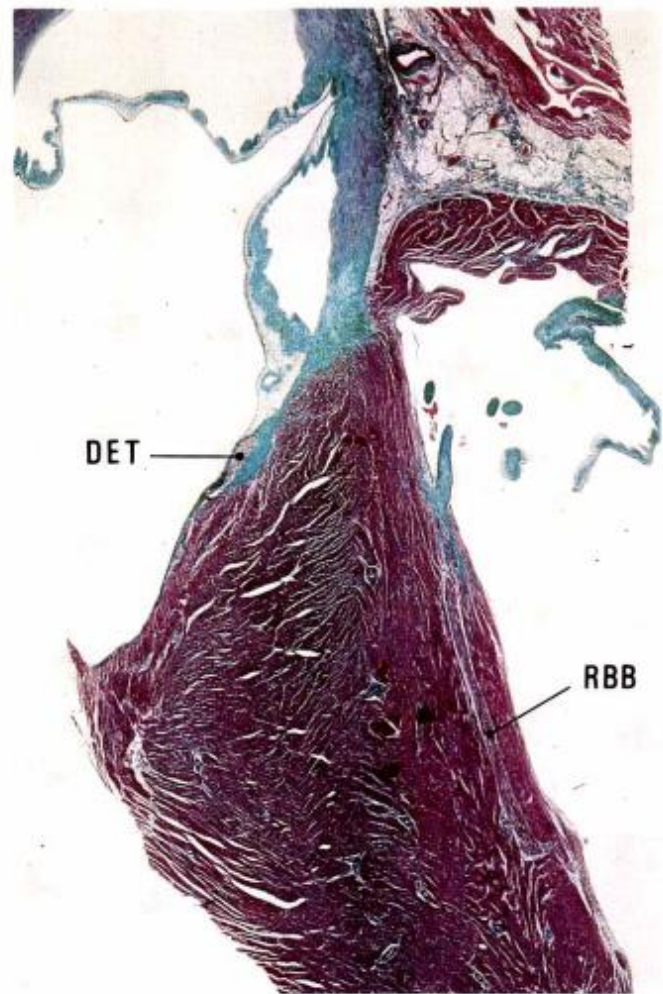
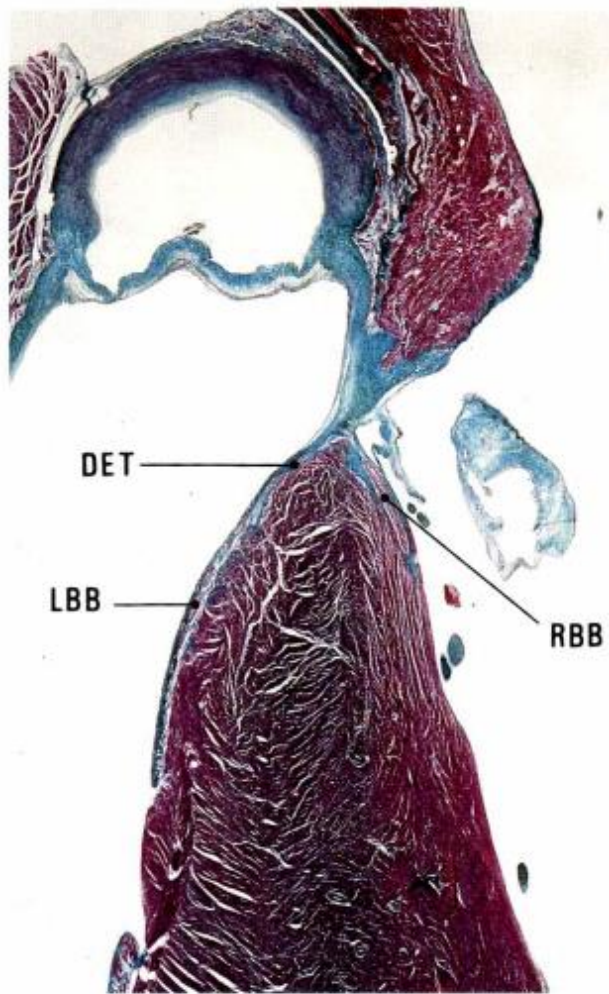


Figure 1-20 Anatomic and surgical aspects of cardiac conduction system. **A**, Diagram of triangle of Koch within right atrium; triangle is defined by tendon of Todaro, orifice of coronary sinus, and tricuspid annulus. **B**, Diagram showing relationship of atrioventricular (AV) node and atrioventricular bundle (bundle of His) to triangle of Koch. AV node lies within the triangle, and AV bundle is located at apex of triangle. CS, Coronary sinus; FO, fossa ovalis; IVC, inferior vena cava; RAA, right atrial appendage; RvV, right venous valve; SVC, superior vena cava. (From Anderson and colleagues.^{A11})

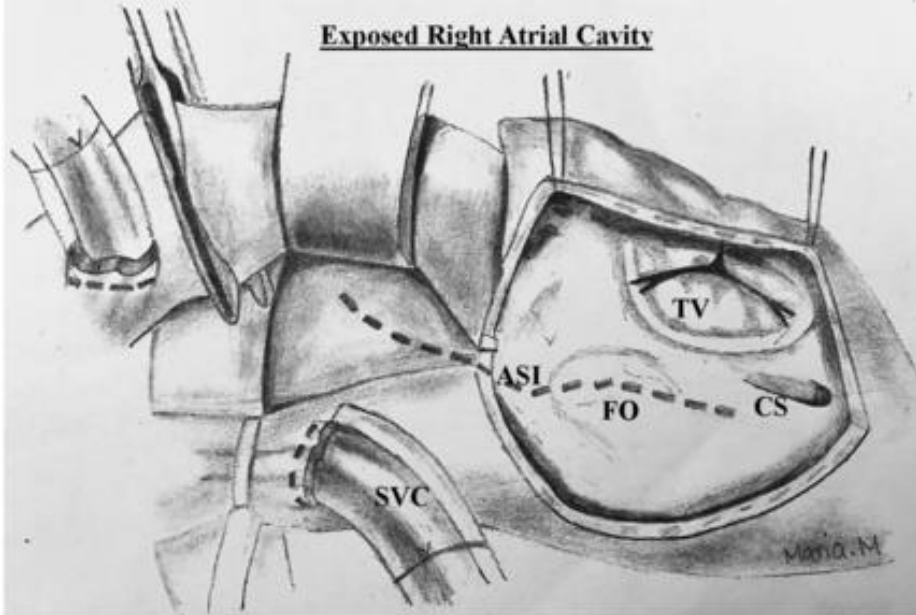




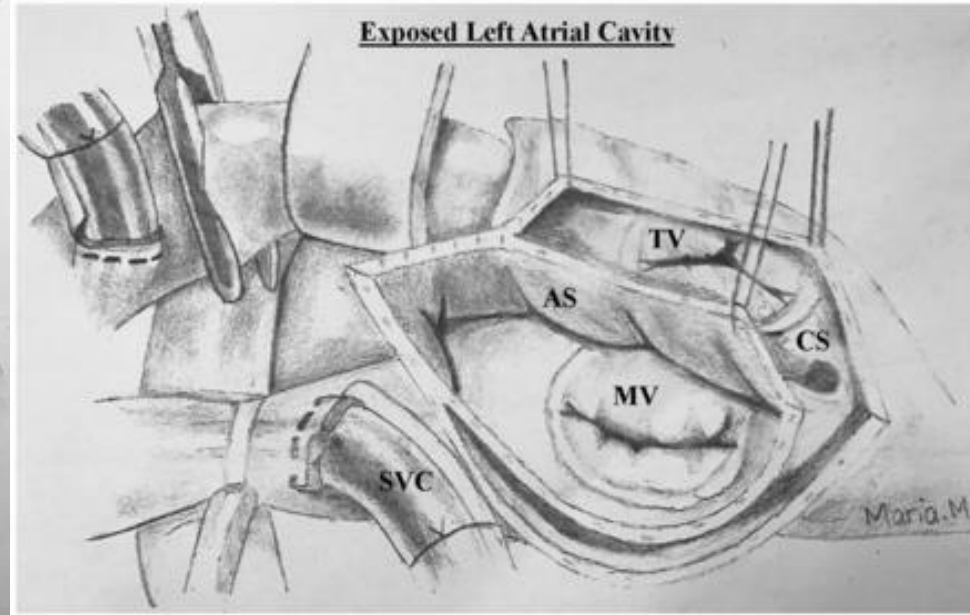


LA Morphology

Exposed Right Atrial Cavity

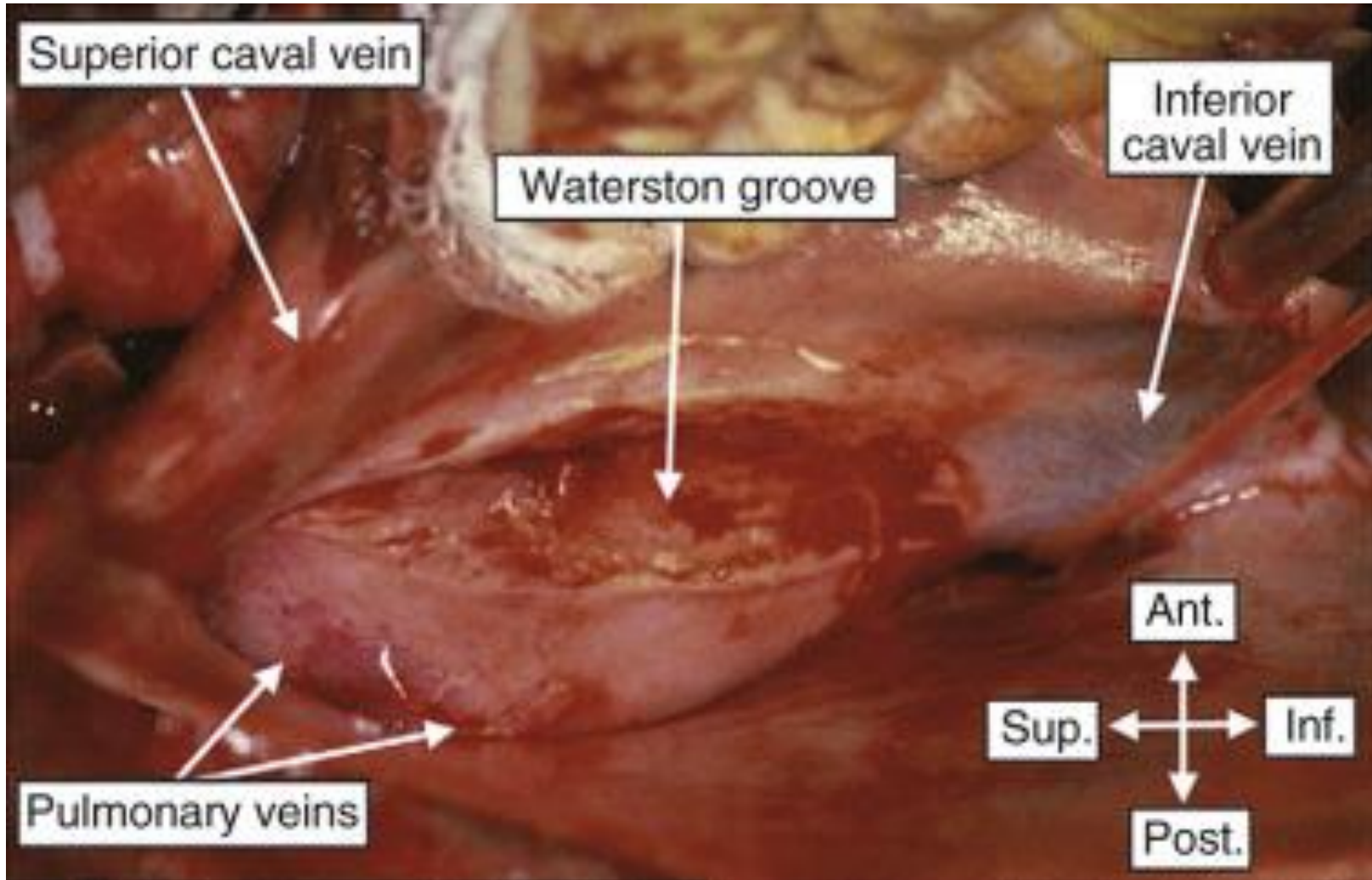


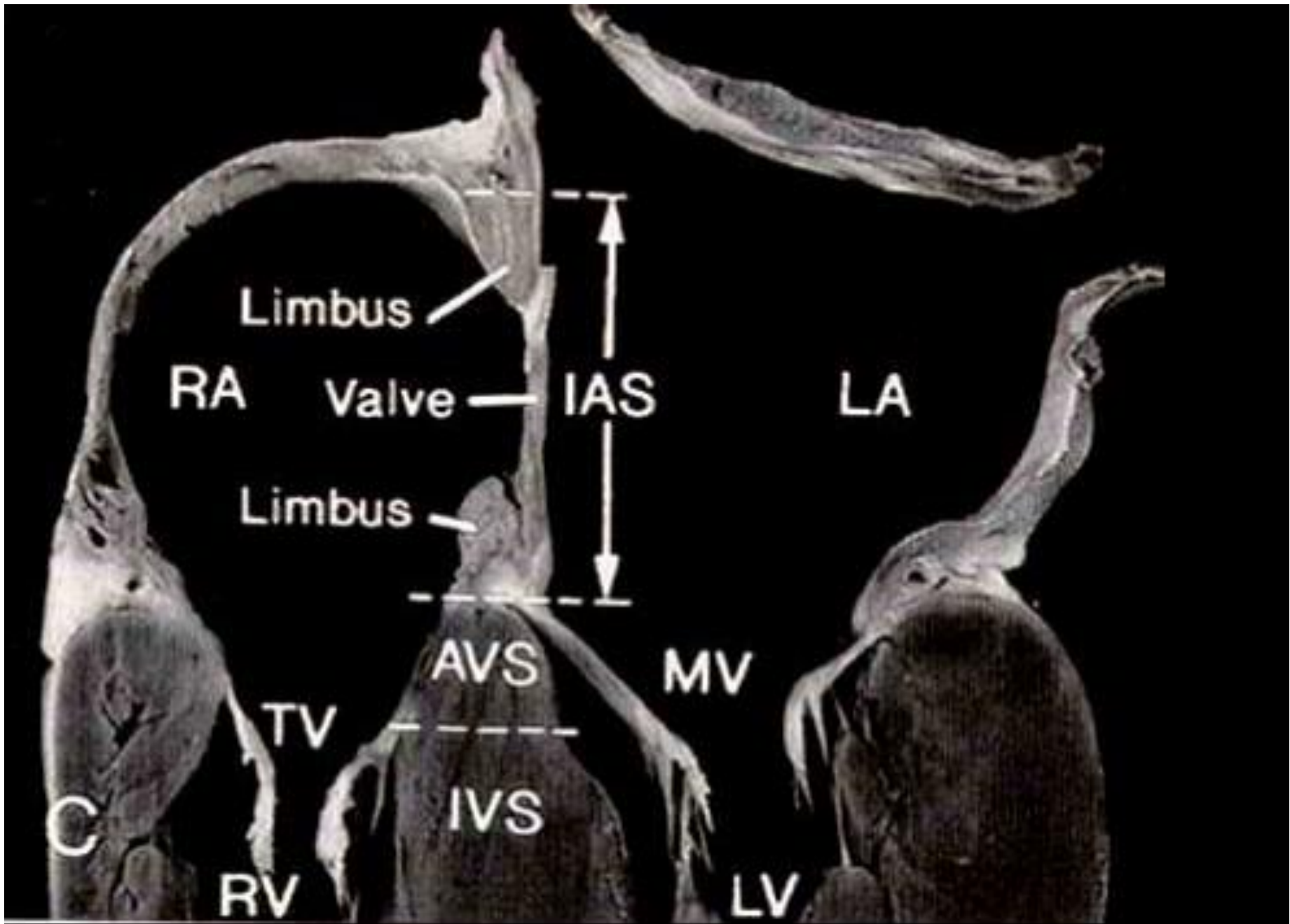
Exposed Left Atrial Cavity



Location of heart

: Waterston groove





Ventricles

RV

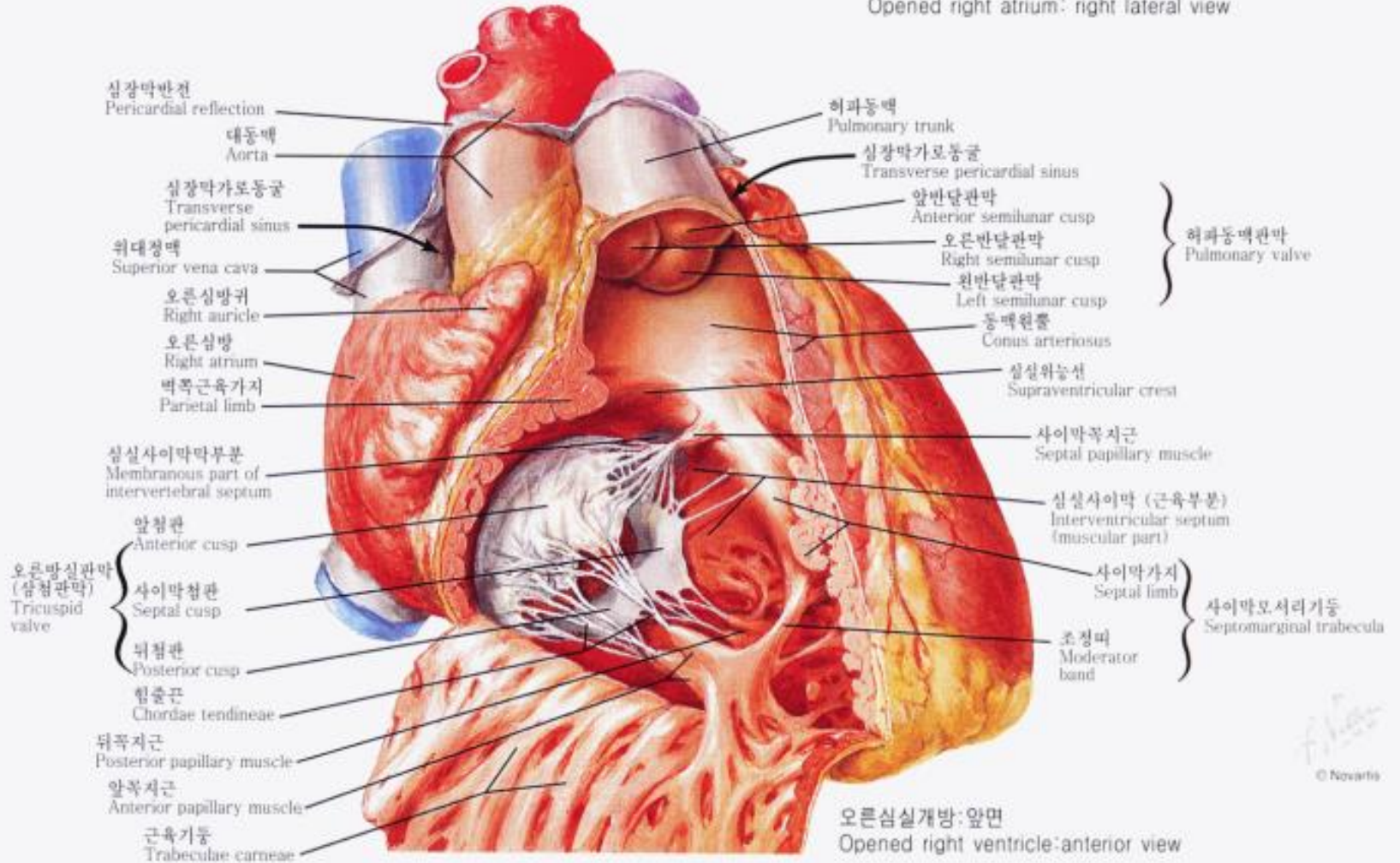
- Trabeculations: heavy and irregular
- Moderator band
- Septal attachment of AV valve: more apical
- **Septal attachment of papillary muscles**

LV

- Trabeculations: fine and regular
- No moderator band
- Septal attachment of AV valve: more cranial
- No septal attachment of papillary muscles

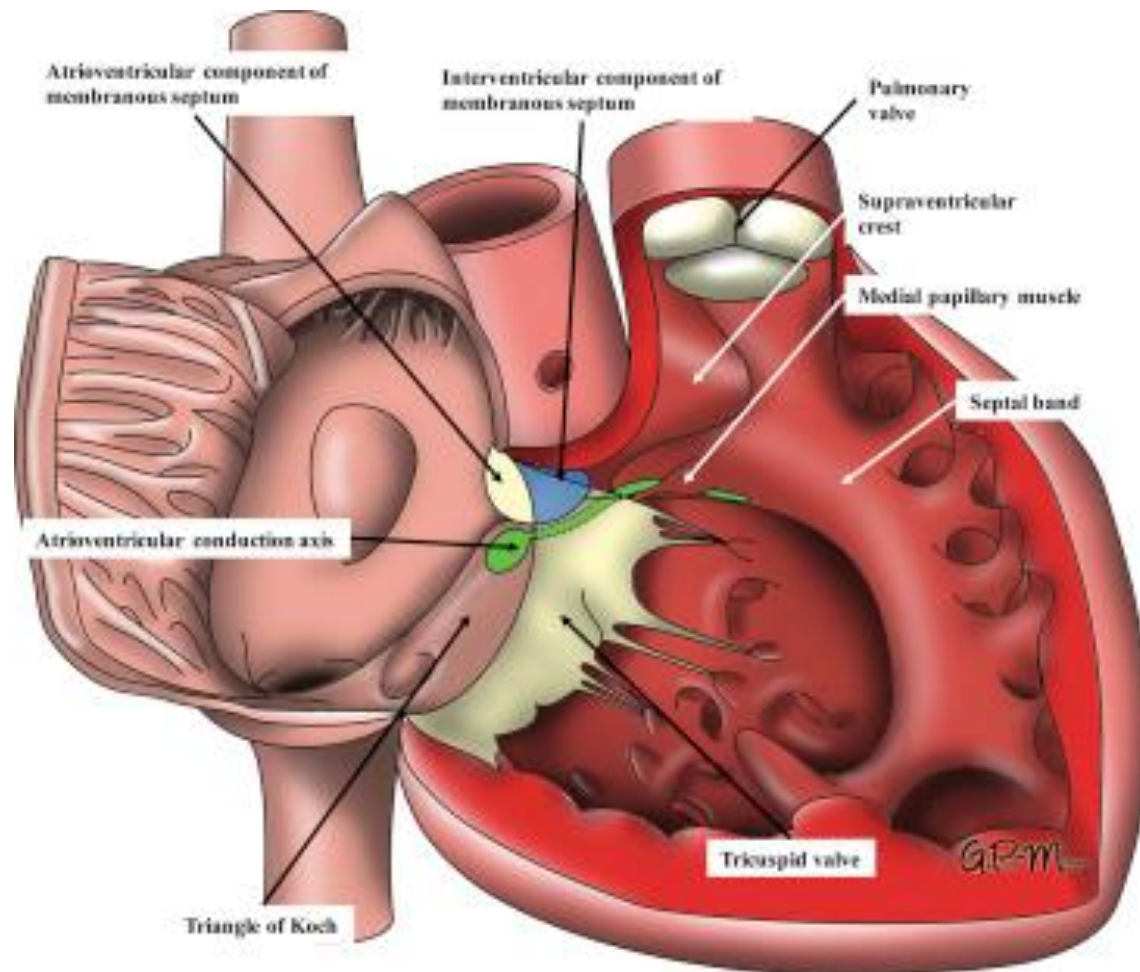
Right Ventricle

Opened right atrium: right lateral view



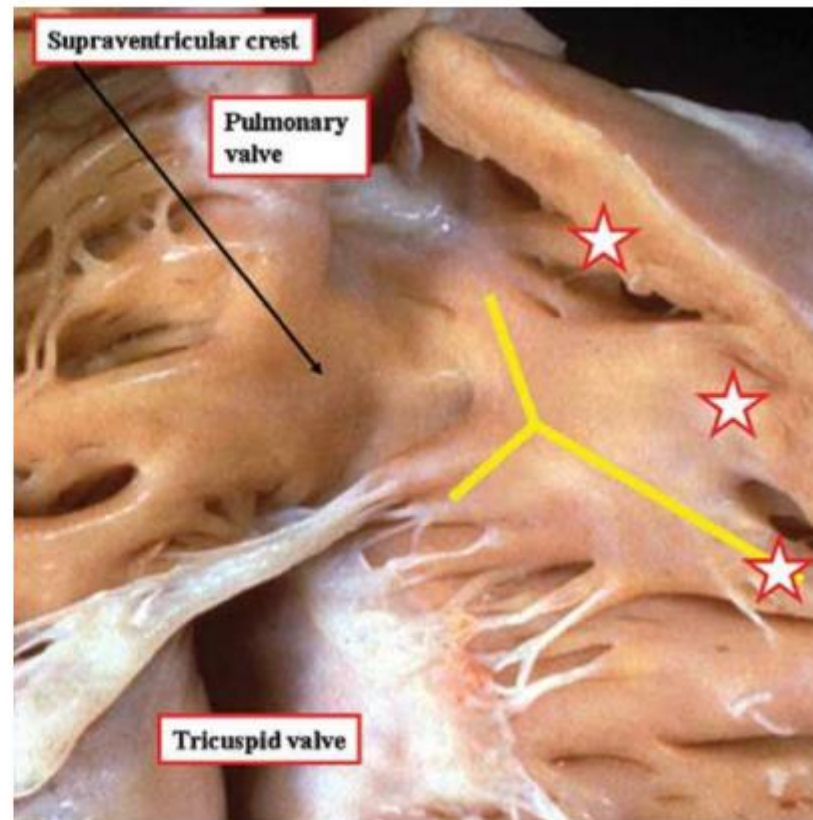
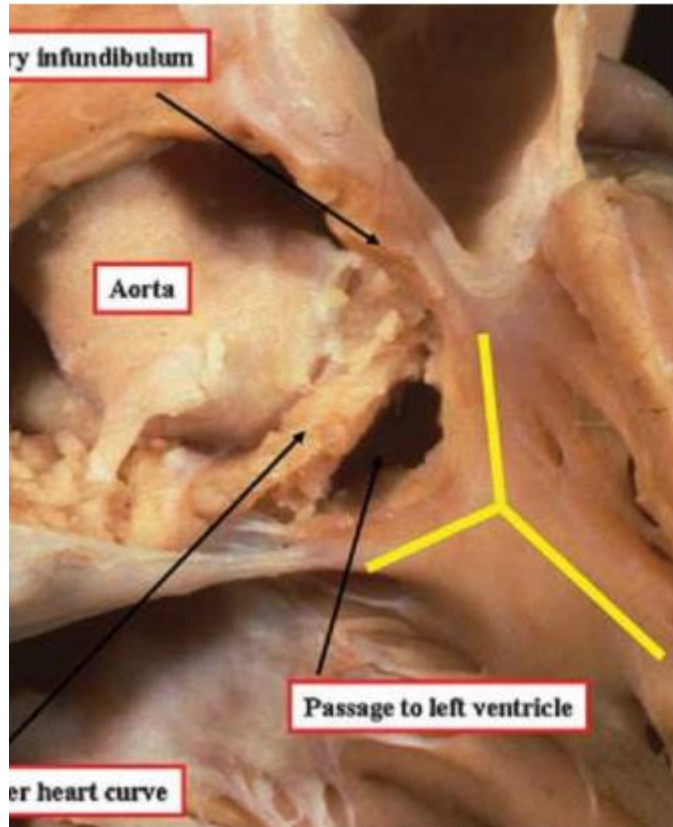
RV Morphology

: medial papillary muscle

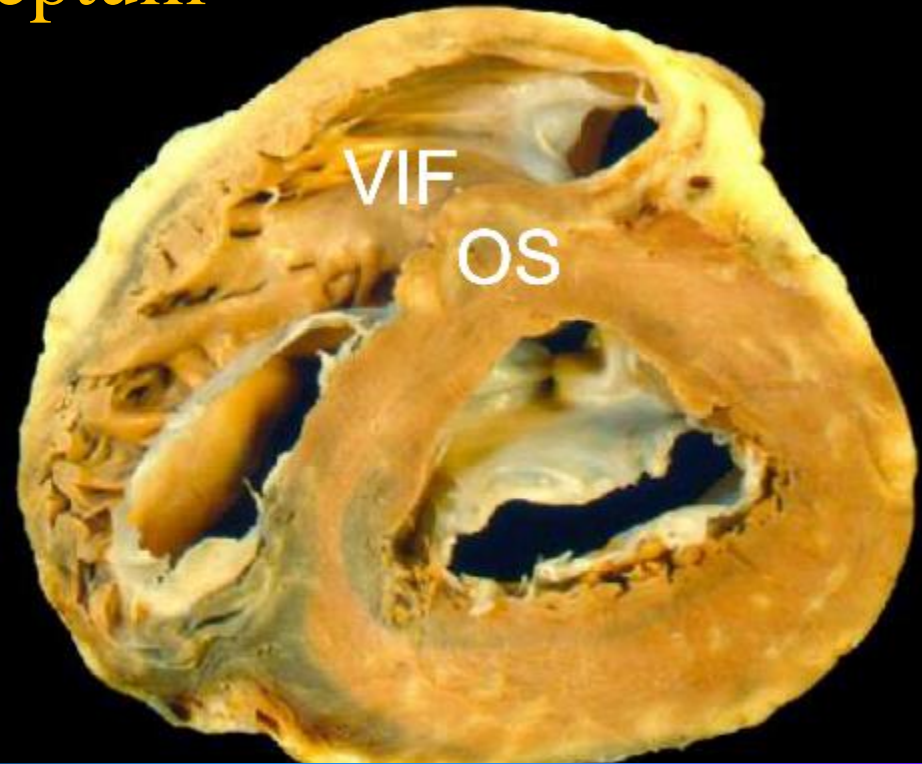
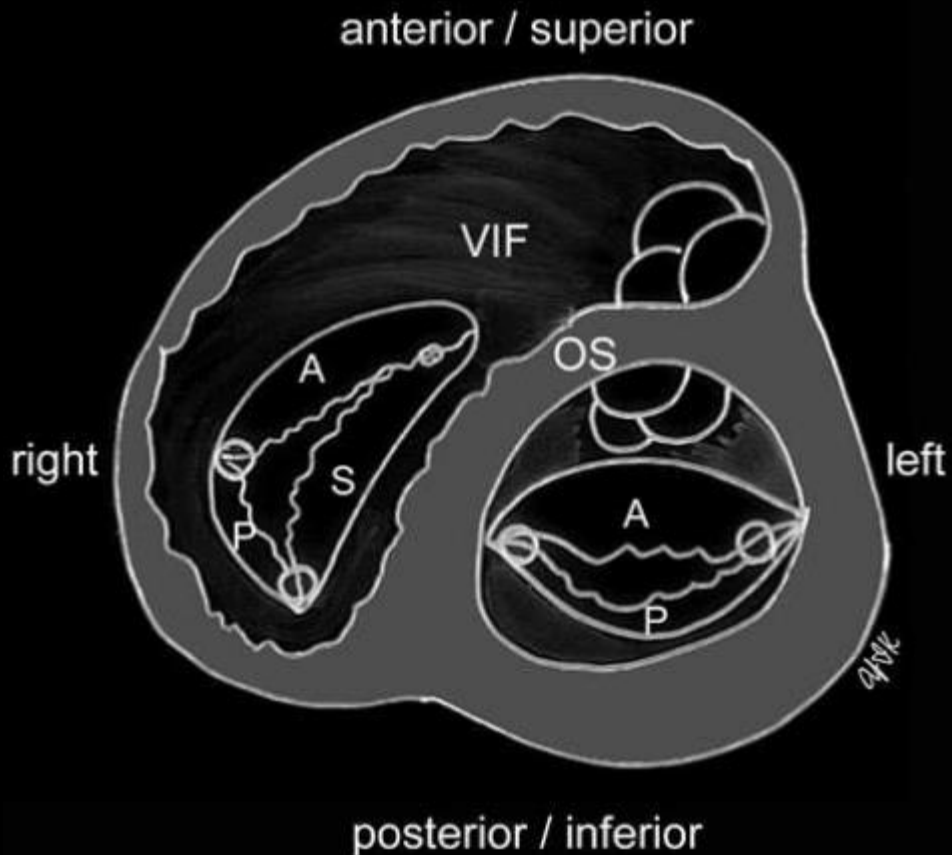


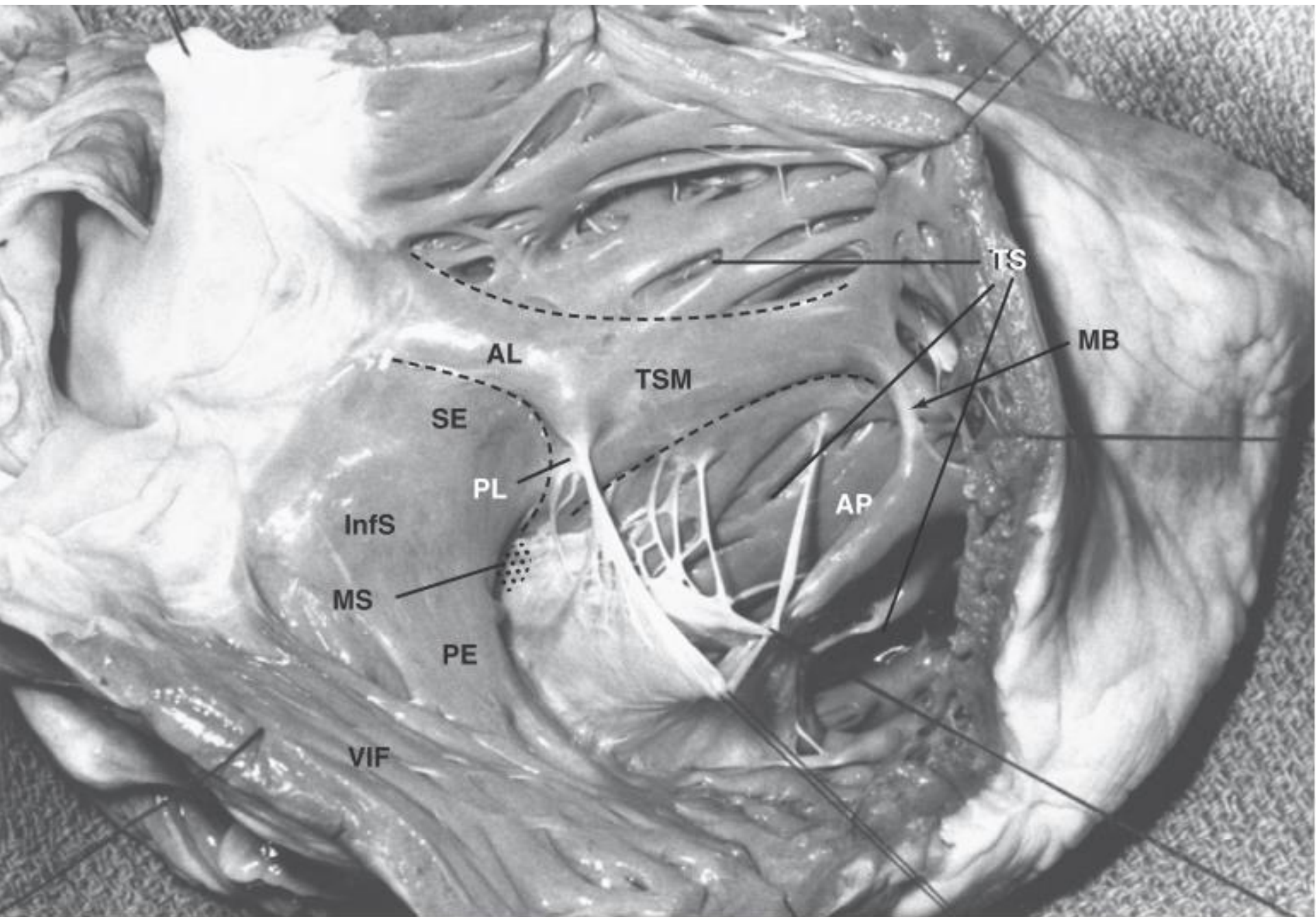
“Crista supraventricularis (Supraventricular crest)”

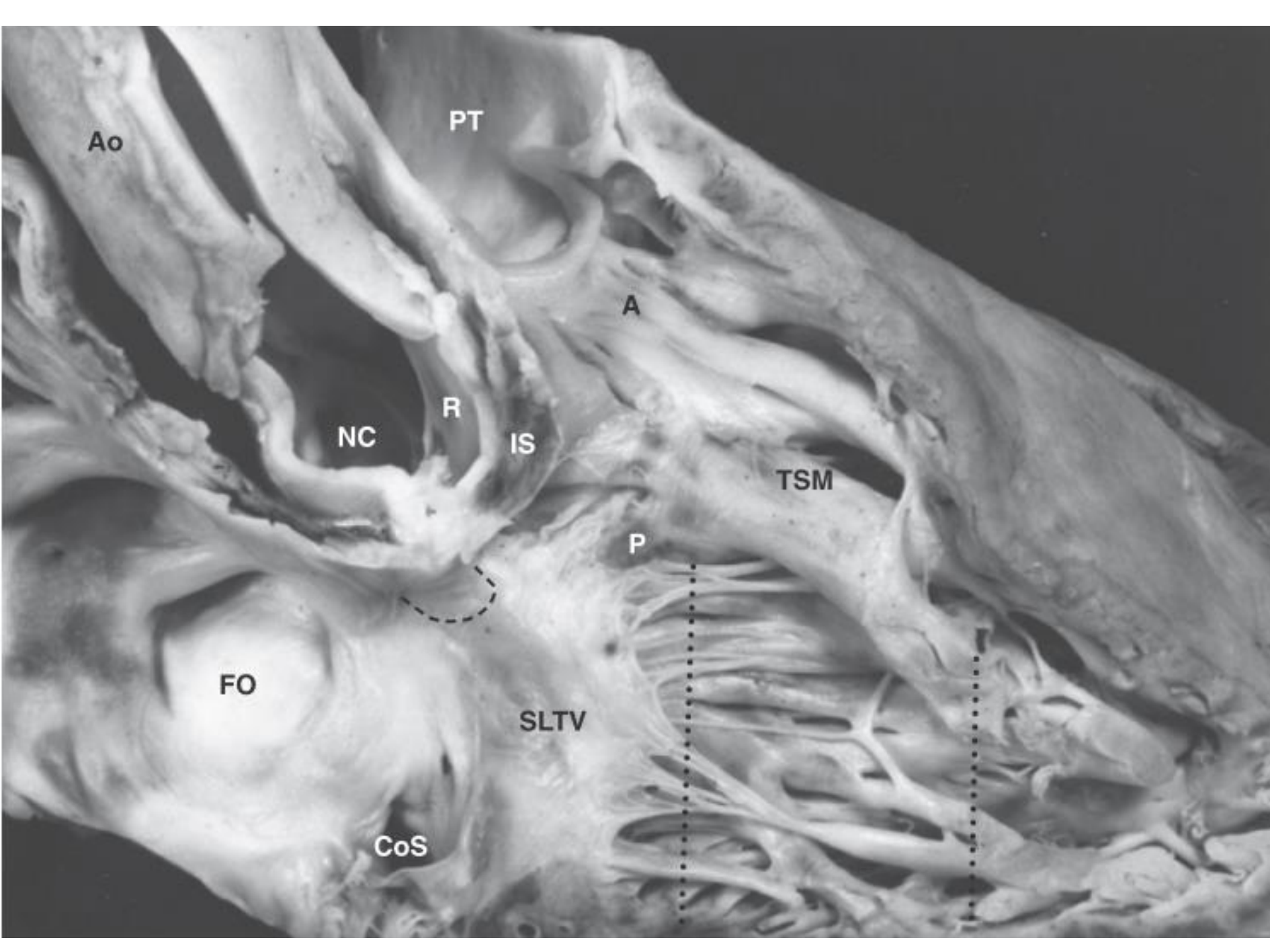
defined as the muscular area separating the attachments of the tricuspid and pulmonary valves in the roof of the right ventricle



Crista supraventricularis: ventriculoinfundibular fold (VIF) + outlet or infundubular septum







Ao

PT

A

NC

R

IS

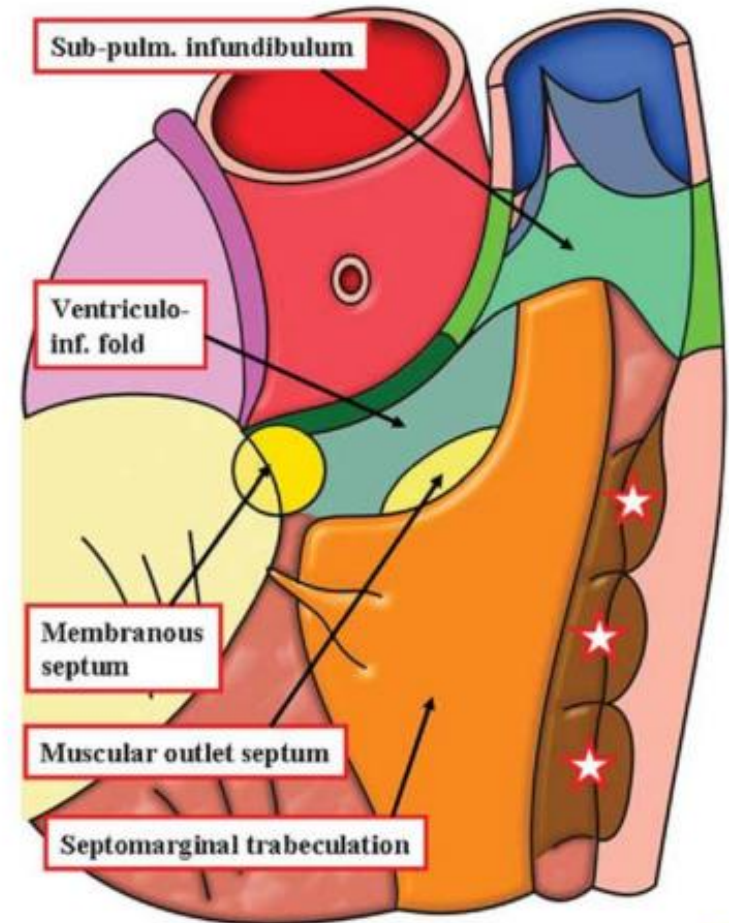
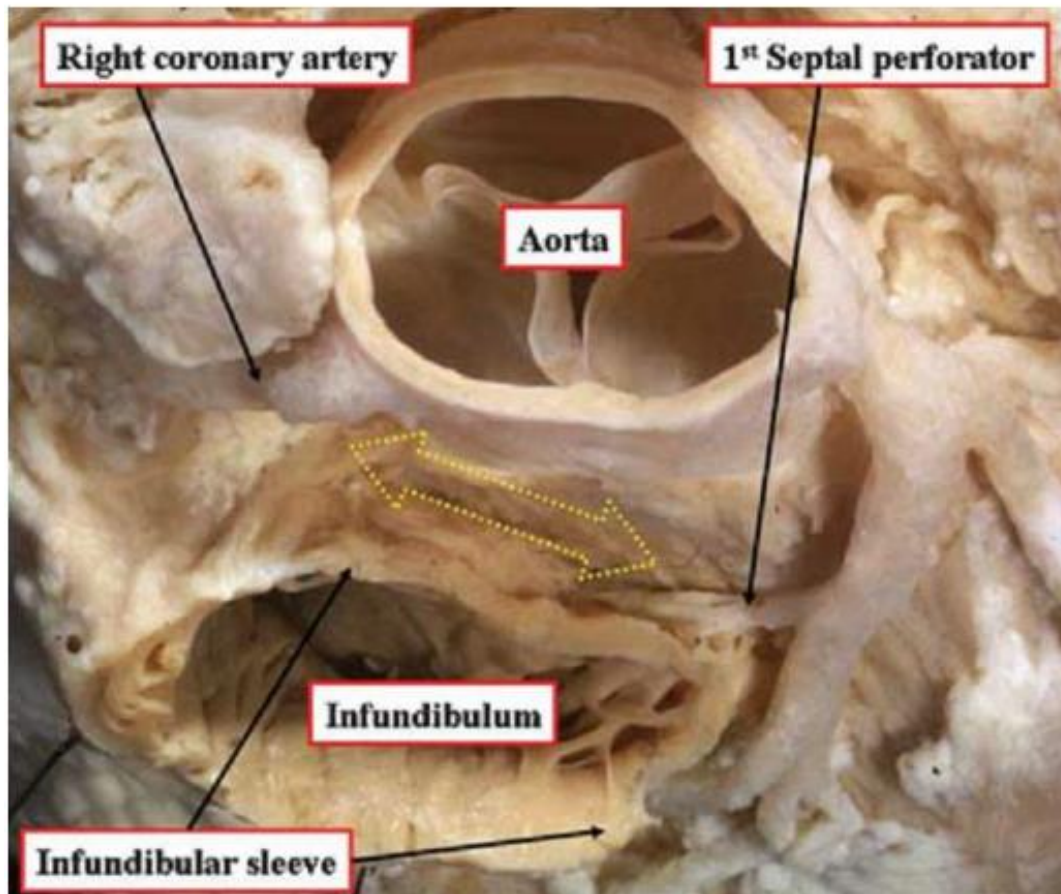
TSM

P

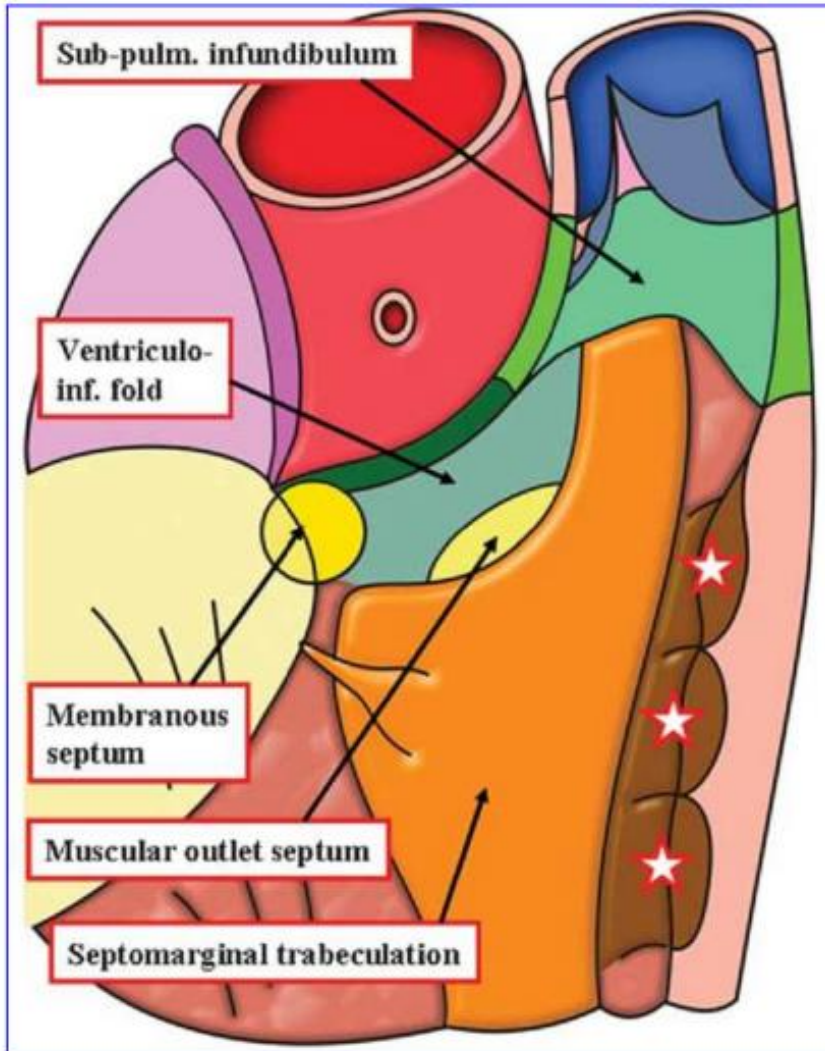
FO

SLTV

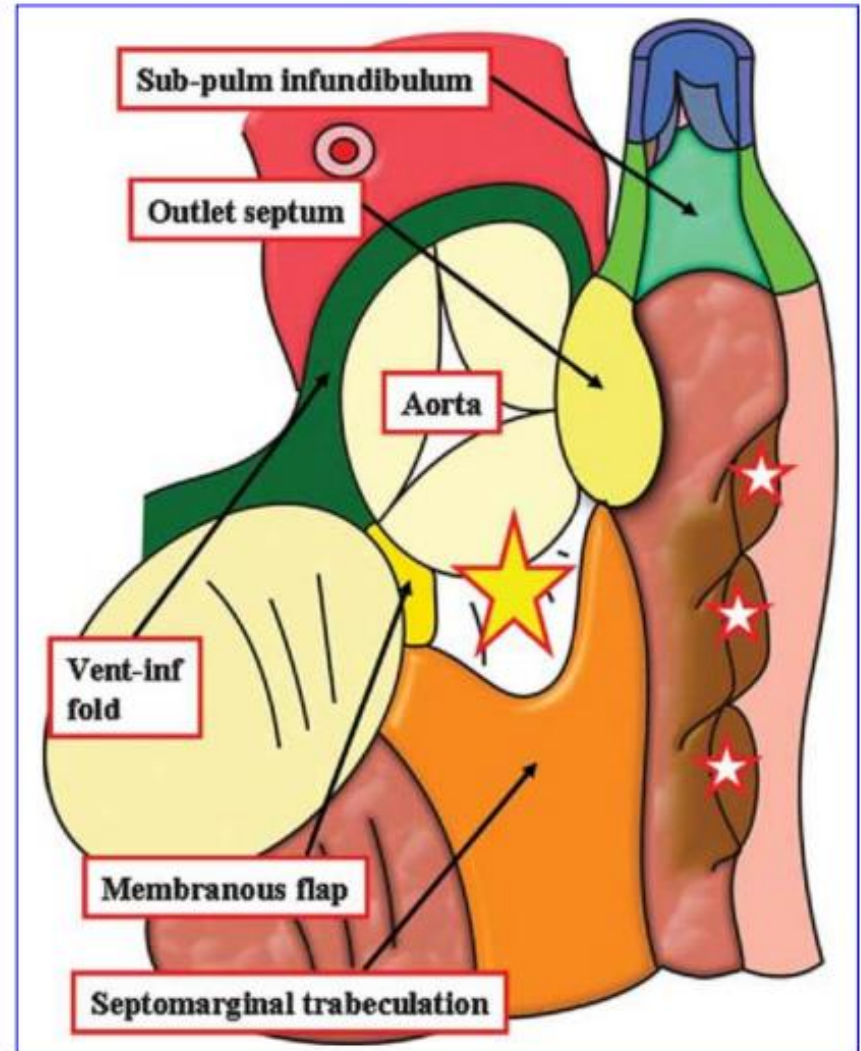
CoS

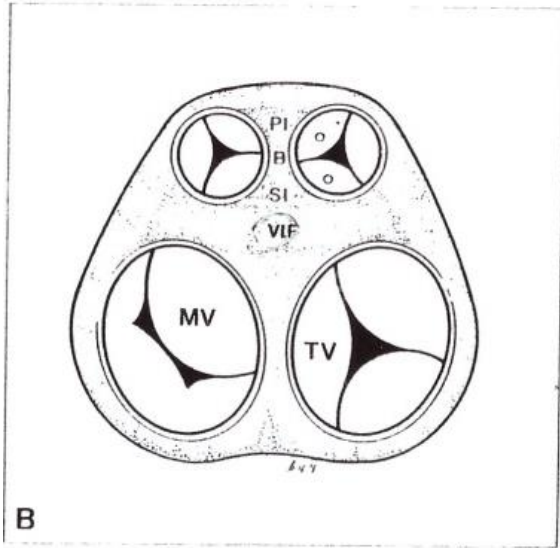


Normal



TOF





let right ventricle.

Notes

Definitions of some important anatomic structures of right ventricle (Fig. 10-9) [6-8].

Crista supraventricularis; muscular crest which separates the pulmonary and tricuspid valves in the normal right ventricle.

Outlet (infundibular) septum (IS); any muscular structure separating the ventricular outflow tracts and arterial valves. It has body (B) and septal (SI) and parietal (PI) insertions.

Ventriculoinfundibular fold (VIF); any muscular structure separating an arterial valve from an atrioventricular valve.

Trabecula septomarginalis (septomarginal trabecula) (TSM); extensive septal trabeculation of the morphologically right ventricle. It has a body (B) and anterior (AL) and posterior (PL) limbs.

Septoparietal trabeculations (SPT); series of muscle bundles or bars in the right ventricle which extend from the septum to the parietal wall.

Moderator band; one of the septoparietal trabeculations which arises from the body of the trabecula septomarginalis and crosses to the ventricular free wall.

Hum
inar

TSM = Septal band

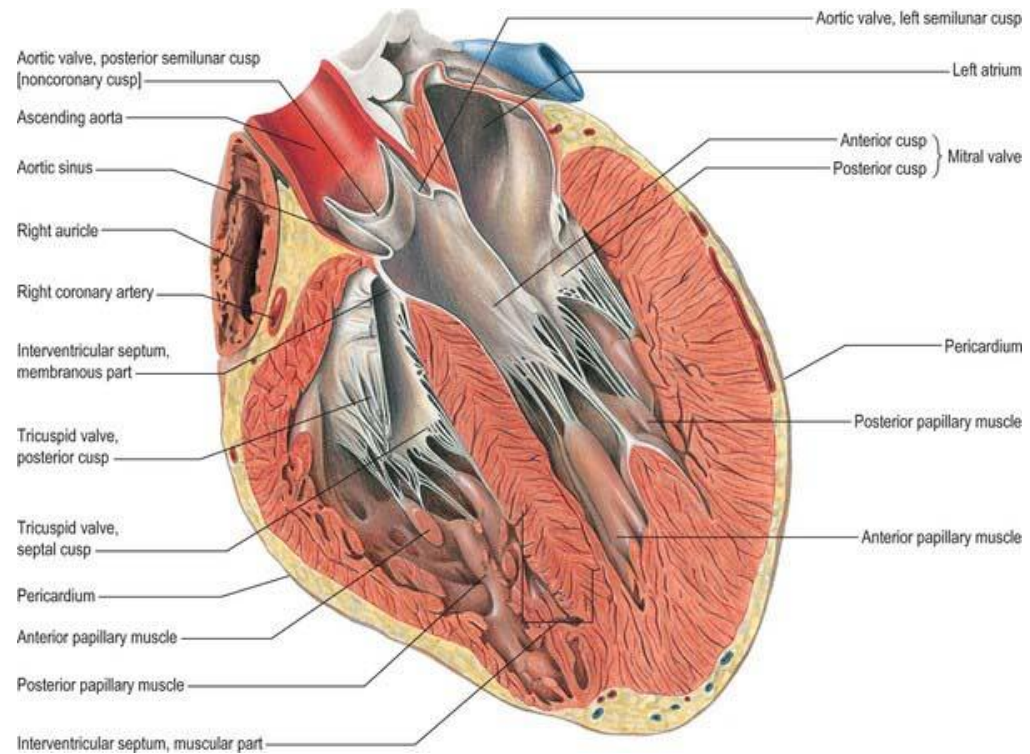
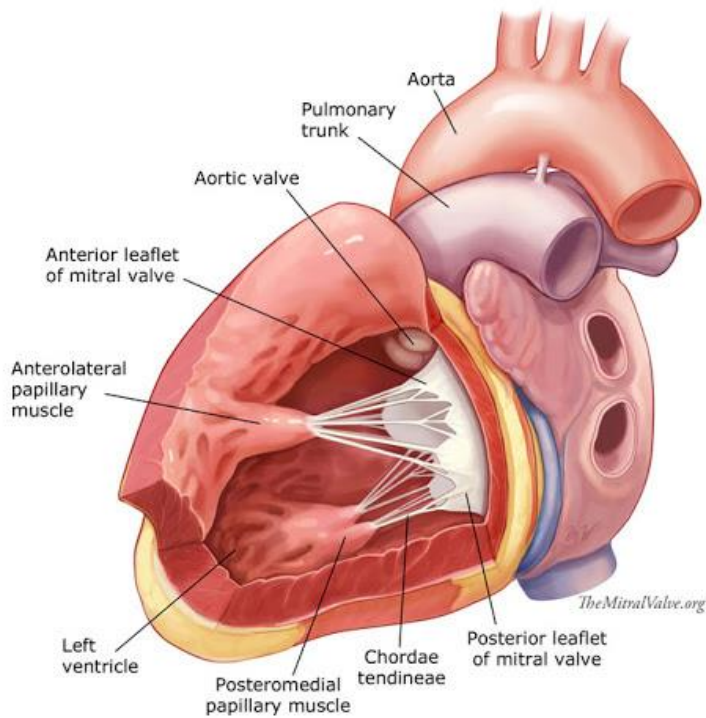
Infundibular Septum

- Parietal band
 - = parietal extension
 - = parietal attachment
- Body
- Septal band
 - = septal extension
 - = septal attachment

키조각은 이리 !!
(동음 이리이)

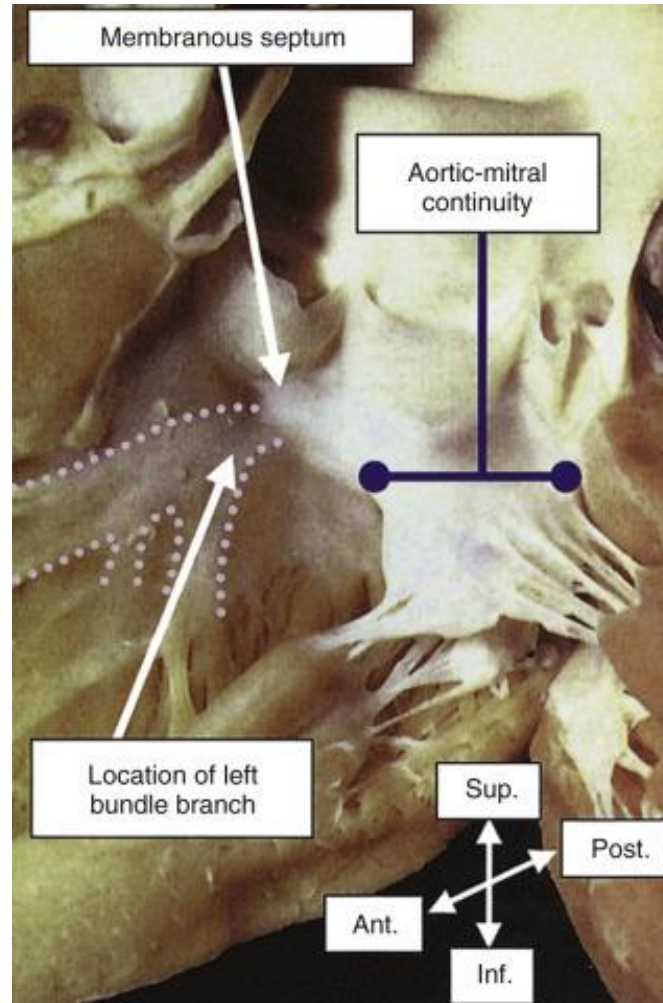
LV Morphology

: papillary muscle



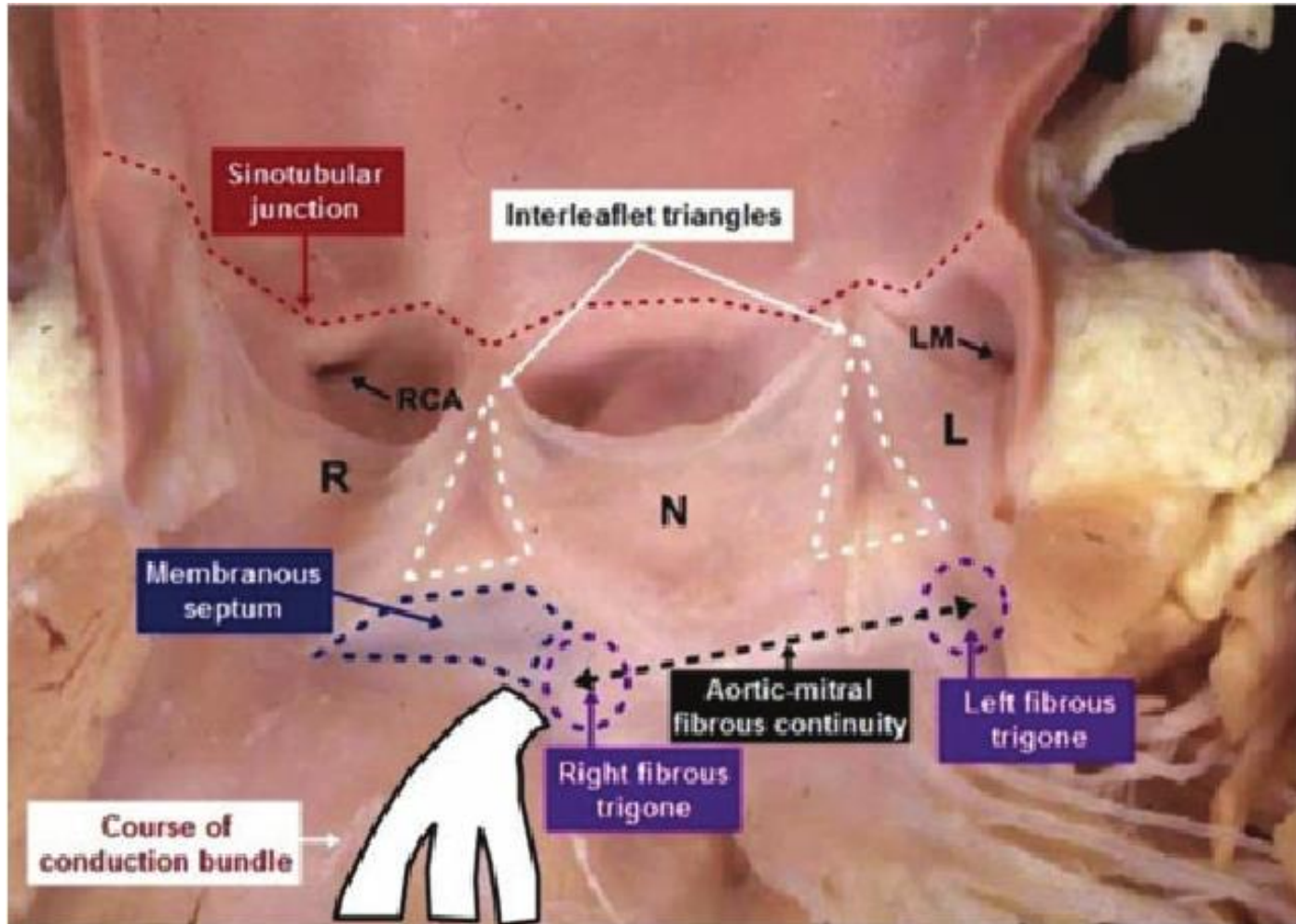
LV Morphology

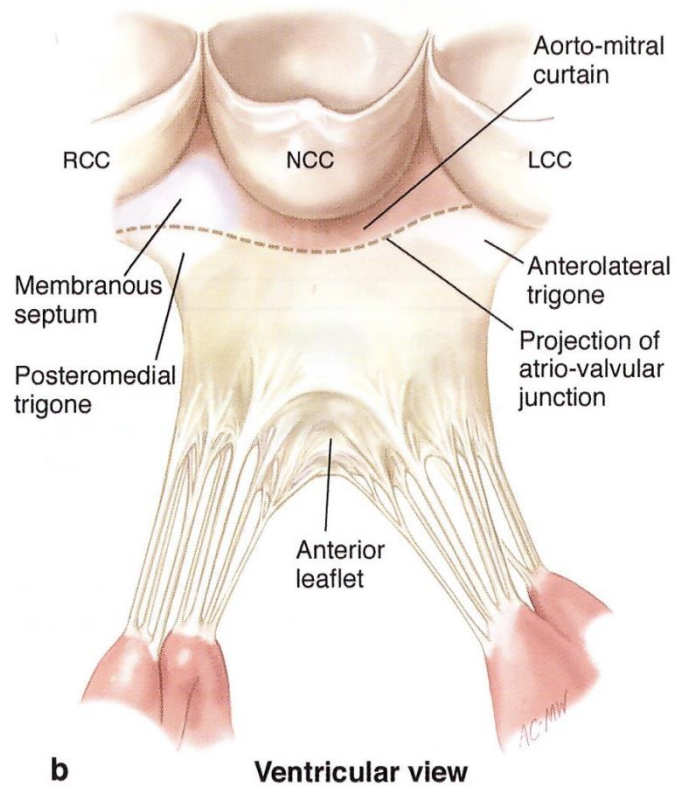
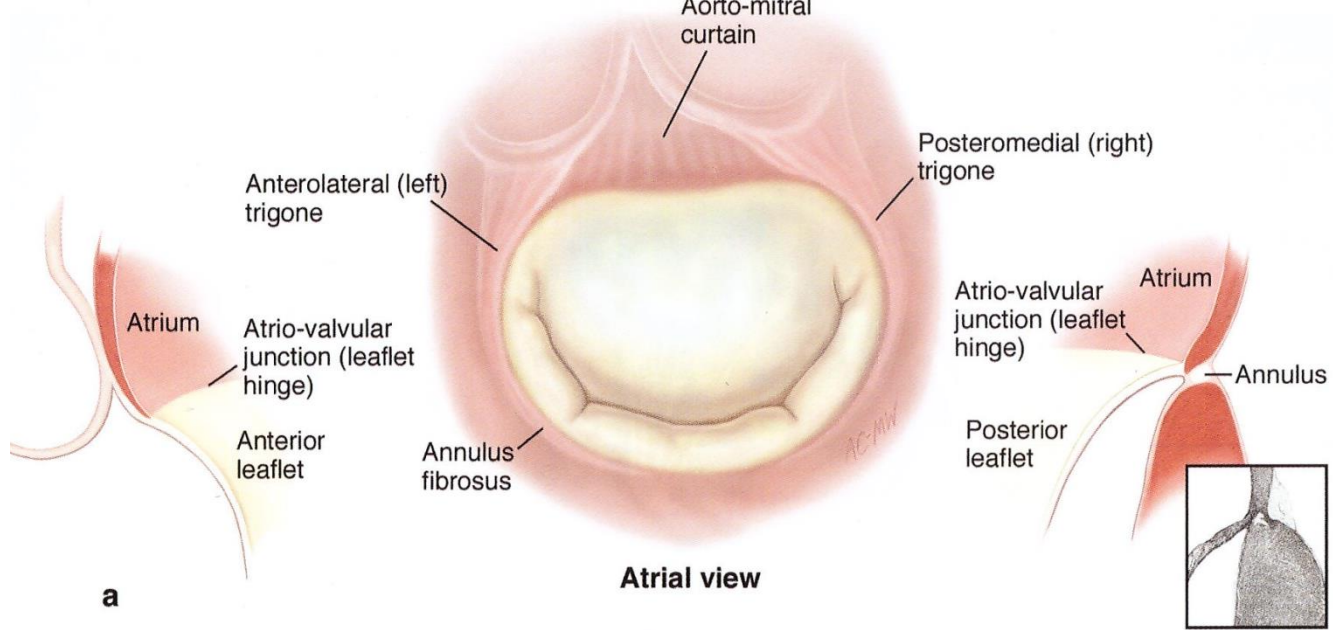
: mitral valve

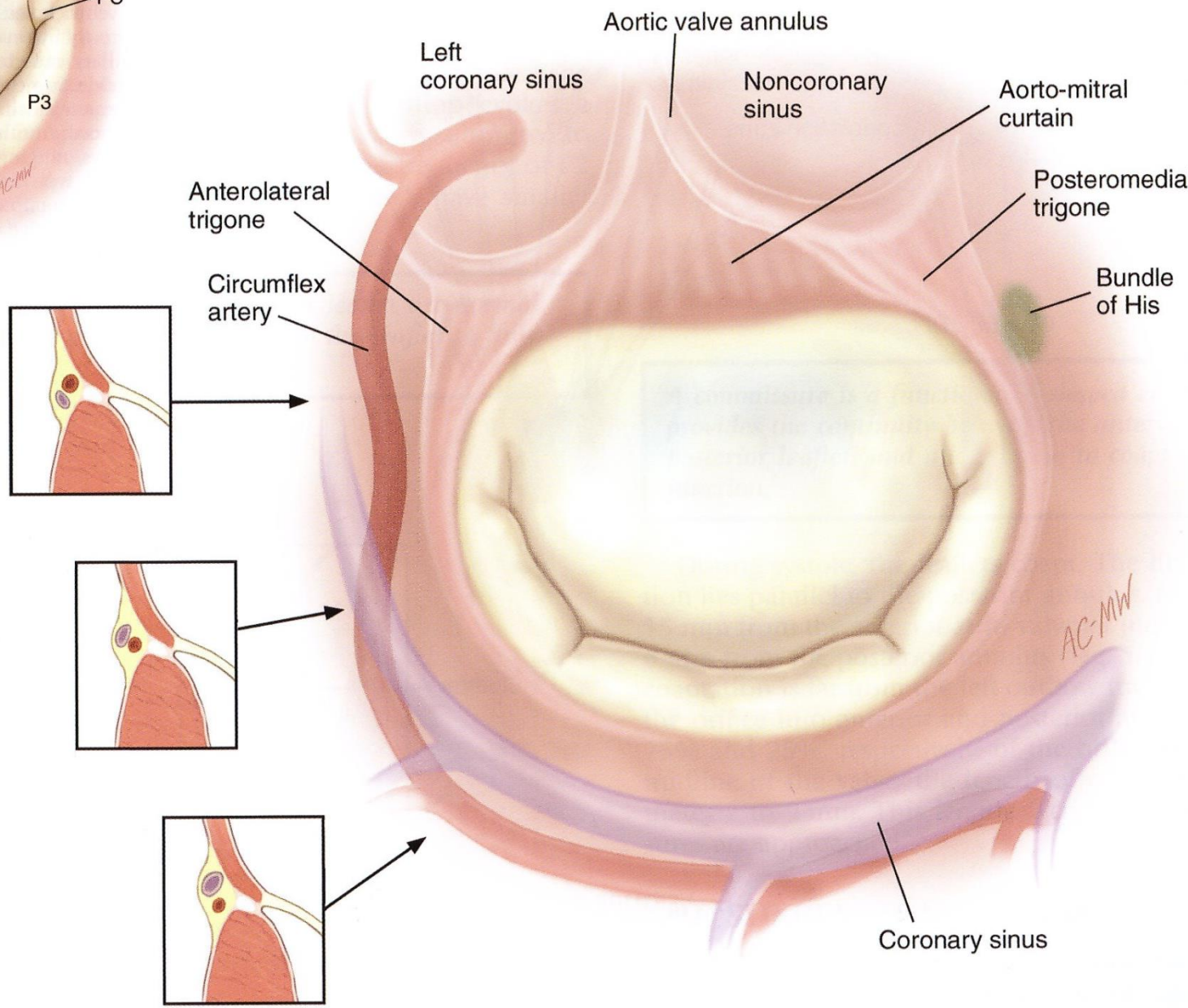
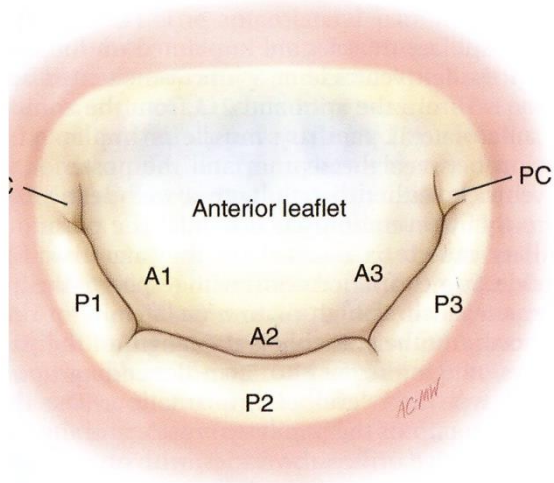


LV Morphology

: outlet







References

- Kouchoukos N, Blackstone E, Hanley F, Kirklin J. Kirklin / Barratt-Boyes. Cardiac Surgery. 4th ed. Elsevier/ USA, 2013
- Carpentier's Reconstructive valve surgery From valve analysis to valve reconstruction. Saunders/USA, 2010
- H. Kurosawa, A.E. Becker, Atrioventricular conduction in congenital heart disease. Springer-Verlag/1987
- Sabiston Textbook of Surgery, 17th ed. Elsevier/2004
- Ciba collection
- Canada Toronto Sick children's Hospital Dr. SJ Yoo's Photo